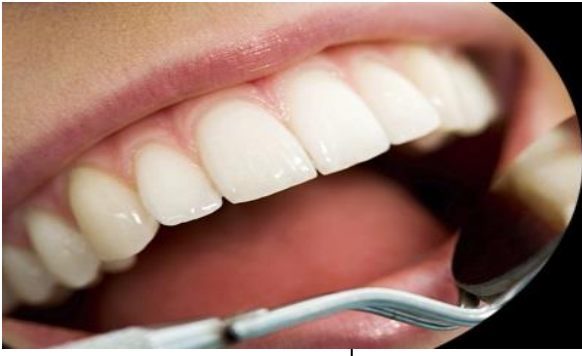



ISSN Print: 2394-7489
ISSN Online: 2394-7497
IJADS 2021; 7(3): 332-334
© 2021 IJADS
www.oraljournal.com
Received: 28-05-2021
Accepted: 30-06-2021

Reem Abdulrahim
Department of Prosthodontics,
Atatürk University, Erzurum,
Turkey

Tuğçe Kavaz
Department of Prosthodontics,
Atatürk University, Erzurum,
Turkey

Nuran Yanıkoğlu
Department of Prosthodontics,
Atatürk University, Erzurum,
Turkey

Comparison between two different techniques in recording posterior palatal seal for maxillary denture fabrication: A case report

Reem Abdulrahim, Tuğçe Kavaz and Nuran Yanıkoğlu

DOI: <https://doi.org/10.22271/oral.2021.v7.i3e.1321>

Abstract

Background: The posterior palatal seal of maxillary denture is an important aid in the retention of the upper prosthesis.

Objectives: The purpose of this article was to introduce two alternative techniques for posterior palatal seal (PPS) registration. These different methods were evaluating the best way to create the area of maxillary posterior palatal seal with more practical approach for routinely clinical measurement in term of posterior retention.

Materials and Methods: In this study the following materials were used: (Elite Hd + Putty Soft (Normal Setting), (Elite Ortho: Gypsum Type III White – Zhermack) for taking primary impression and poured the diagnostic cast. (PATTERN RESIN LS Self-Curing, Acrylic Die Material) to make special tray for each patient. Two different technique to copy the post dam area to the secondary cast were applied; (Cera Reus Pink Impression Wax) The second technique was by applying cold cure acrylic resin. Locate and delineate the anterior and posterior on the soft palate. At time of insertion the evaluation of posterior retention area was made for each two finished maxillary denture and by three different dentists.

Conclusions: Scraping method for establishing the area of post dam with different registration materials is an effective technique for improving posterior retention of maxillary denture.

Keywords: posterior palatal seal, maxillary complete denture, complete denture retention

Introduction

The posterior palatal seal (PPS) has been defined According to Glossary of Prosthodontics Terms-8 “as a soft tissue along the junction of the hard and soft palates on which pressure within the physiologic limits of the tissues can be applied by a denture to aid in the retention of the denture^[1].

A convenient designed PPS is an important factor in determining denture retention^[2]. Different techniques was suggested to record the PPS area^[3-5]. However the success of these techniques depends on the proper and precise location registrations and transfers of anatomical boundaries of PPS area to the diagnostic cast^[6].

Chenn cited three techniques for determining the location of the vibrating lines namely: (1) phonation of the “ah” sound, (2) the swallowing method and (3) the nose-blowing method^[7, 8]. Palatal seal of maxillary complete denture can be obtained by scraping the cast before denture processing, or by using selective pressure impression technique, or physiologic impression technique^[9, 11]. Winland found that various shapes of carving the posterior palatal seal area on the master cast include single bead, double bead, bead with anterior extension on to the bilateral glandular masses, cupid bow and according to House’s classification of the soft palate^[12, 13].

Mariyam *et al.* have discussed the different reasons for Failures in PPS area^[14]. under extension this is because the practitioners use fovea palatine as a landmark for terminating denture base which is not fixed landmark, Over extension when the dentist may violate the physiology of soft palate musculature and place the PPS too far distally, Under post damming with insufficient placement of tissues at some points along the terminal borders of the denture it may be a result of recording the tissues when the mouth was wide open during final

Corresponding Author:
Reem Abdulrahim
Department of Prosthodontics,
Atatürk University, Erzurum,
Turkey

impression (pterygomandibular fold becomes taut), and Over post damming as the cast was scrapped too aggressively and the PPS displaced too much tissue.

In this article we used two different techniques to record the PPS area with simple, efficient, and practical approach for clinical routine use and to create the PPS and compare between these different methods in term of simplicity, time consuming, material used and posterior denture stability.

Techniques

Two patients were selected for this study from the Prosthetic Clinic at College of Dentistry, Ataturk University. These two voluntaries at age of 54, 57 years old with totally edentulous maxillary arch, both of them were with moderate palatal depth with no excessive bony projection. Palatal mucosa was with no irritation or abused tissue.

The patients were informed about the details of study and the ethics committee of Dental faculty of Ataturk University has accepted the study protocol.

Each patient was applied to;

1. An additional silicon impression material (Elite Hd + Putty Soft (Normal Setting) was taken for the maxillary arch with stock tray and pours the impression with type III gypsum (Elite Ortho: Gypsum Type III White – Zhermack).
2. Adapt 2 auto polymerizing acrylic resin base plates (PATTERN RESIN LS Self-Curing, Acrylic Die

Material) for each patient.

3. Locate and delineate the anterior and posterior on the soft palate by using an indelible pencil and instruct the patient to say AH (Fig. 1 A).
4. Transfer this line to the silicon impression tray (Fig. 1B).
5. The first technique to create a post dam area was by applying wax (Cera Reus Pink Impression Wax) to the registered area with thickness of (0.5 mm) and full the same shape accordingly then re inserted in the patient mouth to harden (Fig. 1C).
6. The second technique was by applying cold cure acrylic resin with small brush to the delineated post dam area with thin layer of (0.5 mm) thickness then re inserted in the patient mouth to complete the self-polymerization process and take the final shape(Fig. 1D).
7. After pouring the two different post dam area registered materials; scrubbing the corresponding area with lacron wax carver. (Fig. 2)
8. Complete the construction of complete denture for both patients with their two different post dam area shaping techniques.
9. At time of insertion the evaluation of posterior retention area was made for each two finished maxillary denture by applying anterior pulling force against the posterior post dam area, this method was repeated three times for each different maxillary denture and by three different dentists.

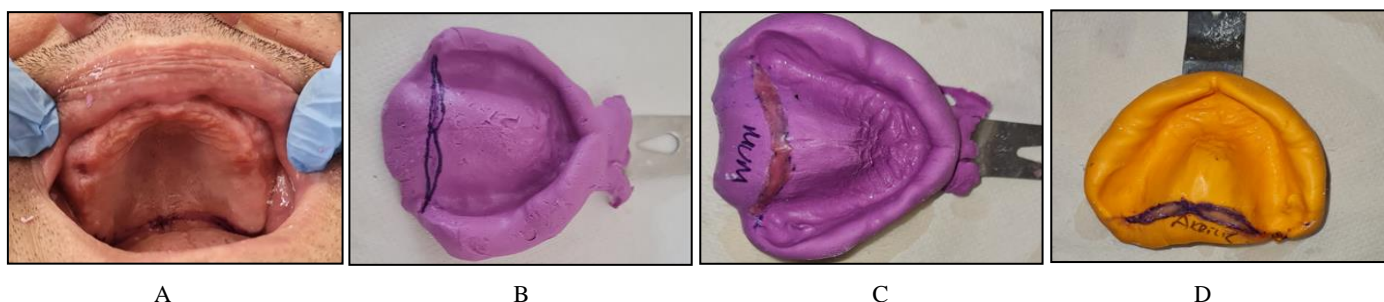


Fig 1: A, Intraoral delineation of anterior and posterior vibrating line with indelible pencil. B, Transfer of anterior and posterior vibrating line to silicone impression. C, full the post dam area with wax. D, full the post dam area with acrylic

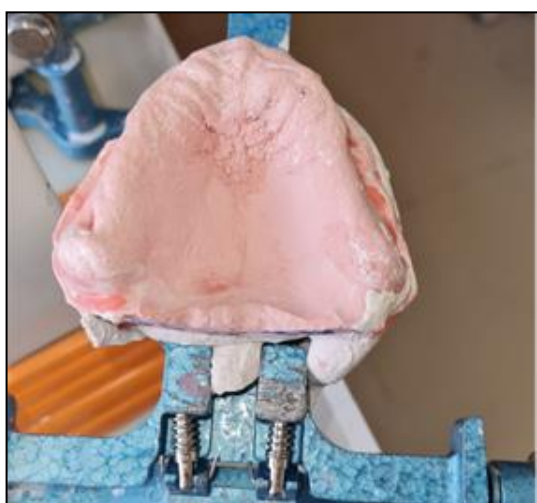

Fig 2: Post dam area on dental cast

Discussion and comparison

Recording the posterior palatal seal in proper and effective way is of great value, because it is an essential factor to set up the peripheral seal and post dam area which enhances retention by employing the atmospheric pressure. Preparation

of Post dam area is a fundamental part of maxillary complete denture fabrication^[15].

In this study which was conducted as a case report for two patients with almost the same criteria for applying two different techniques to register the post dam area of maxillary complete denture; both techniques showed no difference in the final retention of posterior border of the finished denture since the final scrubbing dental cast with definite dimensions. The Wax technique showed lesser time for method of application than acrylic technique which needs longer time to complete polymerization and passing all the acrylic reaction stages with their exothermic hardening procedure. For coast evaluation dental wax material is cheaper than acrylic resin material.

Conclusion

The establishment of the correct posterior palatal seal area is not a difficult procedure as the anatomy and physiology of the area is well defined and registered. Careful examination during the diagnostic phase of the treatment and following established techniques for the placement of the border, seal will ensure a more retentive prosthesis for the patient, whose satisfaction is the main goal of dentist and patient together.

sORCID iDsReem Abdulrahim <https://orcid.org/0000-0002-8544-801X>Tuğçe Kavaz <https://orcid.org/0000-0002-0526-3120>Nuran Yanıkoğlu <https://orcid.org/0000-0001-7677-1248>**References**

1. Thomason JM, Feine J, Exley C, Moynihan P, Muller F, Naert I, *et al.* Mandibular two implant-supported over dentures as the first choices standard of care for edentulous patients-the York Consensus Statement. *Br Dent J* 2009;207(4):185-6. Crossref PMID:19696851
2. De Souza Batista, *et al.* Use of Resin-Based Provisional Material to Create the Posterior Palatal Seal in Complete Denture Definitive Impressions. *Journal of Prosthodontics* 2019;28:e18-e20.
3. Gaikwad, *et al.* Transfer of posterior palatal area on maxillary cast: A modified technique. *J Prosthet Dent* 2019;123:4.
4. Jacobson Krol. A contemporary review of the factors involved in complete denture retention, stability, and support (Part I) stability. *J Prosthet Dent.* Feb 1983;49:165-72. Crossref.
5. Rajeev MN, Appelboum BM. An investigation of the anatomic position of the posterior seal by ultrasound. *J Prosthet Dent* 1989;61:331-6. Crossref.
6. Wicks, *et al.* Defining the posterior palatal seal on a definitive impression for a maxillary complete denture by using a non-fluid wax addition technique. *J Prosthet Dent.* Volume 112, Issue 6, December 2014, 1597-1600.
7. Chenn MS. Reliability of the fovea palatine for determining the posterior border of the maxillary denture. *J Prosthet Dent* 1980;43:133-.
8. Chenn MS, Welker WA. Methods taught in dental schools for determining posterior palatal seal region. *J Prosthet Dent* 1985; 53:380-3.
9. Sallom A. Evaluation of the conventional method for establishing the posterior palatal seal. *J Prosthet Dent* 2012;3(2):61-67.
10. Ansari IH. Establishing the posterior palatal seal during the final impression stage. *Prosthet Dent* 1997;78(3):P324-326.
11. Rashedi B, Petropoulos VC. Current concepts and techniques in complete denture final impression procedures. *J Prosthodont* 2003;12(4):280-7.
12. Winland RD, Young JM. Maxillary complete denture posterior palatal seal: Variations in size, shape and location. *J Prosthet Dent* 1973;29:256-61.
13. Ettinger R, Scandrett F. Posterior palatal seal: A review. *Aust Dent J* 1980;25:197-200.
14. Mariyam A, *et al.* posterior Palatal Seal (PPS): A brief review. *Journal of Scientific and Innovative Research* 2014;3(6):602-605.
15. Jamayet NB, *et al.* A modified way of the posterior palatal seal transfer in the fabrication of the complete denture. *Bangladesh Journal of Medical Science* 2012;16(2):185-187.