



ISSN Print: 2394-7489
ISSN Online: 2394-7497
IJADS 2021; 7(4): 214-222
© 2021 IJADS
www.oraljournal.com
Received: 01-08-2021
Accepted: 03-09-2021

Dr. Sumit Thote
PG Student, Department of
Prosthodontics Government
Dental College and Hospital,
Aurangabad, Maharashtra, India

Dr. Kishor M Mahale
HOD & Professor, Department
of Prosthodontics Government
Dental College and Hospital,
Aurangabad, Maharashtra, India

Dr. Shankar P Dange
Professor, Department of
Prosthodontics Government
Dental College and Hospital,
Aurangabad, Maharashtra, India

Dr. Smita Khalikar
Professor, Department of
Prosthodontics Government
Dental College and Hospital,
Aurangabad, Maharashtra, India

Corresponding Author:
Dr. Sumit Thote
PG Student, Department of
Prosthodontics Government
Dental College and Hospital,
Aurangabad, Maharashtra, India

Radiographic evaluation of bone changes in edentulous maxilla opposing implant retained mandibular overdenture: A systematic review

Dr. Sumit Thote, Dr. Kishor M Mahale, Dr. Shankar P Dange and Dr. Smita Khalikar

DOI: <https://doi.org/10.22271/oral.2021.v7.i4d.1373>

Abstract

Tooth loss is a common problem which affects the oral cavity but also hinders the overall health of a person. Common consequences of tooth loss include progressive alveolar bone resorption and decreased masticatory performance. Edentulism affects oral and general health in addition to quality of life. Both disability and handicap have been associated with a negative impact on psychosocial well-being, especially when considering elders. Treatment for edentulism includes conventional complete dentures (CCDs), implant-retained overdentures (IODs) and, in some cases, implant supported full arch fixed complete denture prostheses. Common problems, especially with mandibular CCDs, include lack of stability and retention, soreness and pain and further loss of function. Overdentures are used as a treatment option in dentistry for more than hundred years. Implant retained overdentures are cost effective and maintenance is also easier compared to implant supported restorations. An evaluation of the long-term outcome of mandibular implant overdentures in relation to maxilla may provide useful guidelines for the clinician. Therefore, this systematic review was designed with an objective to evaluate the effect of mandibular overdenture on edentulous maxilla.

Keywords: bone resorption, conventional complete dentures, implant supported overdentures, lingualised occlusion, systematic review

Introduction

Tooth loss is a common problem which affects the oral cavity but also hinders the overall health of a person. Various factors such as old age, caries, periodontitis, systemic diseases are known to play a significant role. Common consequences of tooth loss include progressive alveolar bone resorption and decreased masticatory performance^[1].

Edentulism has two major problems-disability because it limits a patient's ability to perform two essential tasks in life: speaking and eating, and handicap, because significant changes are needed in order to compensate for the deficiencies^[2]. Edentulism affects oral and general health in addition to quality of life^[3]. Both disability and handicap have been associated with a negative impact on psychosocial well-being, especially when considering elders^[1-3]. Awareness about preventive measures, oral hygiene, and care can help improve the dental status of the patient. However, preservation of the oral structures is also an important aspect in prosthodontic rehabilitation. Treatment for edentulism includes conventional complete dentures (CCDs), implant-retained overdentures (IODs) and, in some cases, implant supported full arch fixed complete denture prostheses. In the past, the most common treatment for edentulism has been to restore function with complete removable dentures. Edentulous patients with a severely resorbed mandible or maxilla often experience problems with conventional dentures, such as insufficient stability and retention, together with a decrease in chewing ability. Due to the fact that, edentulism causes progressive bone loss, treatment with CCDs is limited and detrimental changes continue overtime^[1-4]. Common problems, especially with mandibular CCDs, include lack of stability and retention, soreness and pain and further loss of function^[4].

Branemark's et al. introduction to implants and their proven results of Osseo integration in

Toronto conference in 1982 changed the entire vision of dentistry. The main benefits of implants were they increased prosthesis retention and a reduced the palatal coverage, resulting in higher patient satisfaction and chewing ability. Implant supported restorations are of two types. Implant supported fixed restoration and implant retained overdenture. Implant supported restorations are mostly advised in low to moderate bone atrophy cases while implant retained overdentures are advised in case of high bone atrophy [5-6]. Overdentures are used as a treatment option in dentistry for more than 100 years. In 1856 *Ledger* constructed plates that covered the teeth and he referred the teeth to as fangs. Evans described the use of roots to preserve restorations in 1888, in 1896 *Essig* described the use of telescopic coping over intentional devitalization of roots. Dolder bars for over dentures were introduced in 1961. In 1969, *Morrow, et al.* narrated the simplified techniques of over dentures. In 1980, after the introduction of the phenomenon called osseointegration by *Branemark et al.*, implant overdentures become an option [7]. IODs are an alternative treatment option for edentulism that promises to overcome many of the limitations with CCDs.

Implant retained overdentures are cost effective and maintenance is also easier compared to implant supported restorations. Long term success rate and easy convertibility of implant overdenture to conventional complete dentures in case of implant failures are the added benefits [6-7]. Studies have compared the use of CCDs to IODs to restore edentulous patients, especially the use of mandibular IODs retained by two unsplinted implants. Indeed, the use of mandibular IODs retained by two unsplinted implants is considered to be the first choice of treatment for edentulous elderly patients who are unsatisfied with CCDs [8]. In general, mandibular IODs may be a preferable option due to several advantages such as; possible decrease resorption of the residual ridges, may improve stability and retention, and possible additional improvement in the patient's quality of life and satisfaction [9-12]. The use of implants has dramatically improved treatment choices for most edentulous patients, but it may not be suitable for all patients particularly in less prosperous countries [13] or for patients who are unable to afford costs associated with this treatment option [14].

For a completely edentulous, implants may be used as a retentive tool for overdentures that gives all the advantages of tooth supported overdentures. Overdentures have played a vital role in preservation of remaining tooth, tooth root and alveolar bone. The main benefits of overdenture are retention and stability of prosthesis, which gives the psychologic benefit. These type of prosthesis should be considered in all patients unable to tolerate conventional dentures. They may be specifically indicated in patients with altered anatomy following surgery, neuromuscular disorders, a pronounced gag reflex or severe residual ridge resorption. An evaluation of the long-term outcome of mandibular implant overdentures in relation to maxilla may provide useful guidelines for the clinician. Systematic reviews are one key element of evidence-based healthcare. *Khan et al.* described a step-by-step process for conducting a systematic review, and outlined the quality elements inherent in each step [15]. Therefore, this systematic review was designed with an objective to evaluate the effect of mandibular overdenture on edentulous maxilla.

Materials and Method

Formulating the Review Question

The research question was set in accordance with the PICO

format (Population, Intervention, Comparison, and Outcome).

PICO Model

1) Patient	Patients wearing dentures
2) Intervention	Implant supported mandibular overdenture
3) Comparison	None
4) Outcome	Effects on maxilla

Research Question

Is there an effect by implant retained mandibular overdenture on maxillary complete edentulous arch?

OR

Do radiographic changes in the bone take place in maxillary complete edentulous arch in patients wearing implant retained mandibular overdenture?

Protocol and Registration

The present systematic review was registered at the National Institute for Health Research PROSPERO International Prospective Register of Systematic Reviews.

Registration number: CRD42020213229

The search protocol is designed based on the PRISMA (Preferred reporting Items for systematic Reviews and meta-analysis) guidelines 2009.

A. Inclusion Criteria

1. Peer reviewed scientific journals from 2001 to 2020;
2. Full articles in English were included;
3. Randomized Controlled trials with follow ups only;
4. Studies which checked effect of Mandibular overdentures on maxilla;
5. Completely edentulous maxillary arch;
6. Minimum 2 implants in mandible;
7. Radiographic evaluation with CBCT or OPG;
8. Patients ready to give consent.

B. Exclusion Criteria

1. Case reports, case series, cross-sectional studies, In-vitro studies or animal studies, Reviews & Abstracts;
2. Articles with incomplete data and patients with presence of any condition were excluded;
3. Declined to participate;
4. Articles in any other language except English;
5. Negative behavior towards dental treatment.

Criteria for Considering Studies for This Review

Type of studies and Type of participants

All randomized controlled trials with the required intervention were included.

Types of interventions

Interventions which had oral implants in mandible and compared to effect on maxillary denture were included. Interventions which had at least 2 implants and a minimum follow up of 6 months were included.

Types of outcome measures

Primary outcomes: To evaluate the effect of mandibular overdenture on edentulous maxilla using radiographical assessment to assess bone changes.

Search methods for identification of studies: Electronic databases like Ebscohost, Cochrane Library, Google Scholar and PubMed were searched. Based on the inclusion and exclusion criteria, 2 reviewers independently selected the relevant articles. Any disagreement was discussed until a

consensus was reached.

Search Strategy

The following bibliographic databases and trials registers were searched:

1. Pubmed search strategy (1 January 2001 to 1 May 2021)

- "Alveolar bone loss"[Mesh] OR "bone height changes" [tw] OR "ridge resorption" [tw] OR "residual ridges"
- "Maxilla"[Mesh] OR "Denture, Complete, Upper"[Mesh] OR "combination syndrome" [tw] OR "completely edentulous maxilla" [tw] OR "edentulous maxilla" [tw] OR "complete dentures" [tw]
- "Denture, Overlay"[Mesh] OR "all on four implant" [tw] OR "implant-retained mandibular overdentures" [tw] OR "mandibular implant supported overdentures"
- "Radiography, Dental"[Mesh] OR "Cone-Beam Computed Tomography"[Mesh]

2. The Cochrane Central Register of Controlled Trials (CENTRAL) search strategy (1 January 2001 to 1 May 2021)

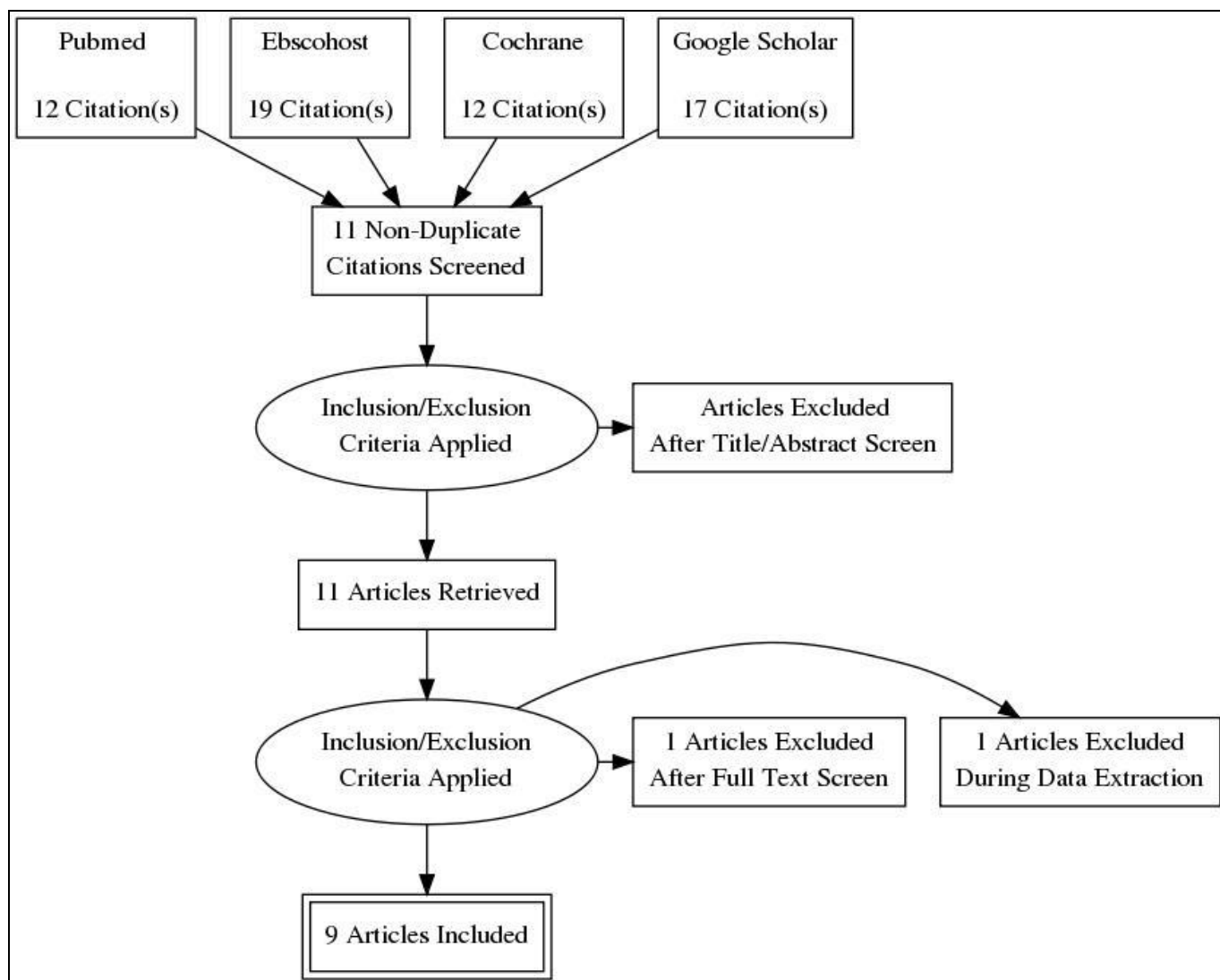
- "Alveolar bone loss" OR "bone height changes" OR "ridge resorption" OR "residual ridges"
- "Maxilla" OR "Denture, Complete, Upper" OR

- "combination syndrome" OR "completely edentulous maxilla" OR "edentulous maxilla" OR "complete dentures"
- "Denture, Overlay" OR "all on four implant" OR "implant-retained mandibular overdentures" OR "mandibular implant supported overdentures"
- "Radiography, Dental" OR "Cone-Beam Computed Tomography"

3. Ebscohost (1 January 2001 to 1 May 2021)

- #1 "alveolar bone loss" OR "bone height changes" OR "ridge resorption" OR "residual ridges"
- #2 "Maxilla" OR "Denture, Complete, Upper" OR "combination syndrome" OR "completely edentulous maxilla" OR "edentulous maxilla" OR "complete dentures"
- #3 "Denture, Overlay" OR "all on four implant" OR "implant-retained mandibular overdentures" OR "mandibular implant supported overdentures"
- #4 "Radiography, Dental" OR "Cone-Beam Computed Tomography"

Handsearching: Manual hand searching was done at Institution level.



Data Collection and Analysis**Selection of studies**

Two review authors assessed titles and abstracts for inclusion in the review. Selection criteria was used for selecting papers suitable for inclusion. Downloaded set of records from each database were imported to the bibliographic software package Zotero and merged them into one core database to remove duplicate records and to facilitate retrieval of relevant articles.

Data extraction and management

Data extraction was carried out on a specially designed form independently by two review authors who were blinded to each other's data. Results were compared to check for inconsistencies and disagreements resolved by discussion.

Following details for each trial were recorded on data extraction form

Authors, Study setting, Participants, Groups, Inclusion & exclusion, Intervention, Outcome and Risk of bias.

Table 1: Summary of the included studies.

Sr. No.	Author.	Country and Year of study.	Study Design.	Participants.	Groups Intervention/ Comparison.	Outcomes measured.	Description of main results.
1.	<i>Timo O. Närhi</i>	Netherlands July 2000.	RCT	89 completely edentulous patients.	Implant-supported overdentures on a trans mandibular implant system (n = 21) implant-mucosa-supported overdentures on 2 IMZ implants (n = 20) conventional complete dentures (n = 14).	Possible changes in the width of the maxillary residual ridge 6 years after receiving mandibular implant-supported or implant-mucosa-supported overdentures	Significant reduction in the width of the ridge was found in all measurement areas (mean difference = 0.4 to 0.6 mm). In subjects with implant-mucosa-supported overdentures, complaint of loose maxillary denture correlated with the decrement of residual ridge width.
2.	<i>Andrés López Roldán et al</i>	Spain. 2009	RCT	40 patients, 22 women and 18 men, had complete edentulism.	A "control" group formed by 15 patients wearing CDs and a "case" group formed by 25 patients wearing upper CDs and a lower overdenture on two lower jaw implants in with two different types of attachments.	Bone resorption process in maxilla and whether Kelly's Combination Syndrome occurs in the group of patients wearing overdentures.	0.32 mm/year bone loss in maxilla in patients with mandibular overdentures. Mandibular bone loss was 2.5 times less in patients in the cases group.
3.	<i>Moustafa Abdou ELSyad</i>	Egypt. July 2013	RCT	32 completely edentulous patients received 2 implants in the canine region of the mandible. Overdentures were connected to the implants either with ball (group 1, n = 16) or telescopic (group 2, n = 16) attachment.	Maxillary complete dentures.	To measure clinical and radiographic changes in the edentulous maxilla in patients with either ball or telescopic attachments of implant retained mandibular overdentures.	Bone resorption in the anterior area of the maxilla occurs in both groups. Telescopic attachments for implant-retained mandibular overdentures are associated with increased maxillary ridge resorption and flabbiness.
4.	<i>M. A. ELSYAD.</i>	Egypt. 2013	RCT	32 edentulous male patients received two implants in the anterior mandible and CDs in maxilla.	Group 1-mandibular overdentures were retained to the bars with either clips. Group 2-Silicone resilient liners. Group I; 7 patients received mandibular overdenture retained with 2 implants in the canine region bilaterally with ball and socket attachment.	To compare the influence of resilient liner and clip attachments for bar-implant retained mandibular overdentures on opposing maxillary ridge after 5 years of denture wearing.	Resilient liner attachments for bar-implant retained mandibular overdentures are associated with decreased resorption and flabbiness of maxillary anterior residual ridge and fewer maxillary denture relining times when compared with clip attachments.
5.	<i>Amany Abdel Fattah</i>	Egypt. January 2018	RCT	14 completely edentulous patients.	Group II; 7 patients received mandibular overdenture retained with single implant in the midline with ball and socket attachments.	To study the maxillary tissue changes under complete dentures opposing mandibular implant-supported overdenture retained by either two or single midline implant.	There was non-significant increase in maxillary mucosa thickness in both groups at both points of measurements. Also, there were posterior radiographic bony changes in maxillary ridge within both groups. There was significant increase in maxillary bony changes in Group II in comparison to Group I.

6.	<i>Mohamed Samih Alsrouj.</i>	Malasiya. October 2018	RCT	18 Completely edentulous patients.	Mandibular implant retained overdenture group and Complete Dentures.	To compare the residual ridge resorption (RRR) of the anterior maxillary bone beneath CDs when opposed by a mandibular CDs and implant-retained overdenture (IRO).	The mean reduction in bone volume of the anterior maxilla in CD group was 2.60%. The predominant areas of RRR were on the buccal and occlusal ridge of the anterior maxilla.
7.	<i>Eatemad R. Taha.</i>	Abraham Canadian universty Egypt. January 2019	Prospective parallel randomized controlled clinical study	12 completely edentulous male patients 51 to 64 years.	Group A- 6 patients received 4 parallel implants with IRO. Group B- 6 patients received 4 implants in the anterior part of the mandible, 2 axial implants in the center and 2 tilted implants at the distal ends with all-on four hybrid prostheses. All patients received maxillary CDs.	To evaluate and compare radiographic maxillary bone height changes under complete denture opposing mandibular four implants' retained overdentures or all-on-four hybrid mandibular prostheses.	Non-significant increase in maxillary mucosa thickness in both groups at both points of measurements. Also, there were posterior radiographic bony changes in maxillary ridge within both groups. There was significant increase in maxillary bony changes in Group II in comparison to Group I.
8.	<i>Radwa M.K Emera.</i>	Egypt. January 2019	RCT	18 completely edentulous male patients. Maxillary complete dentures were constructed opposed to 2-implant retained mandibular overdentures.	Group 1-ball/socket. Group 2-Locator attachment. Group 3- positioner attachment.	To compare radiographically the effect of different resilient attachments on maxillary and mandibular residual ridge changes after 5 years of using mandibular 2-implant retained overdentures.	The minimal rate of ridge resorption was recorded for posterior maxillary ridges followed by that of posterior mandibular while the highest resorption rate was recorded for anterior maxillary ridges.
9.	<i>Mohamed Saad Alrajhi.</i>	Dentistry Mansoua University. February 2020	RCT	12 completely edentulous Patients.	Group:1- 6 patients received 4 implants in the maxillary arch according to the All-on-four concept & were immediately loaded with maxillary denture. Control group-6 patients received conventional maxillary CDs and distal extension mandibular partial dentures only without any implant treatment in the maxillary arch.	To evaluate the effect of placement four implants following All-on-4 concept on anterior bone resorption in the upper completely edentulous patients opposing class I removable partial denture.	Control group showed highly significant higher anterior bone loss than test group. All on four fixed prosthesis for edentulous maxilla opposed by remaining mandibular anterior teeth reduces maxillary anterior alveolar bone loss compared to conventional dentures. However, it does not prevent maxillary bone loss.

Assessment of risk of bias in included studies

We planned to assess risk of bias using the methods set out in the Cochrane Handbook for Systematic Reviews of Interventions. We planned to assess included trials according to the following criteria.

- 1) Random sequence generation.
- 2) Allocation concealment.

- 3) Blinding, assessed in three groups: participant, operator and outcome assessor.
- 4) Incomplete outcome data.
- 5) Selective reporting.
- 6) Other bias.

Table 2: Risk of bias

	Random sequence generation (selection bias)	Allocation concealment (selection bias)	Blinding of participants and personnel (performance bias)	Blinding of outcome assessment (detection bias)	Incomplete outcome data (attrition bias)	Selective reporting (reporting bias)	Other bias
Amany Abdel-Fattah 2018	+	?	-	+	+	+	+
Andrés López-Roldán 2009	-	-	-	+	+	+	+
Eatemad R. Taha 2019	+	+	-	+	+	+	+
M. A. ELSYAD 2014	+	+	-	+	+	+	+
Mohamed Saad Alrajhi 2020	-	-	-	+	+	+	+
Mohamed Samih Alsrouj 2020	?	-	-	+	+	+	+
Moustafa Abdou ELSyad 2013	?	-	-	+	+	+	+
Radwa M.K Emera 2019	+	?	-	+	+	+	+
Timo O. Närhi 2000	+	-	-	+	+	+	+

Discussion

This systematic review assessed the outcome of implant-supported overdentures in terms of changes taking place in the maxilla.

According to *Timo O. Närhi* the patterns of resorption in the maxilla differed from those in the mandible, and were most pronounced at the first years after the loss of teeth. In contrast to the edentulous mandible, maxillary resorption was frequently seen as gradually decreasing the width of the residual ridge^[16, 17]. In the study, panoramic radiographs were made as a part of routine annual examinations. Authors

concluded that residual ridge width of an edentulous maxilla decreases gradually in incisor and canine areas. And the decrease in residual ridge width was small and not associated with the type of mandibular restoration.

Andrés López-Roldán concluded that bone loss occurred in all the patients, although they could not point out the differences in magnitude from one person to another. This result also coincides with that cited by the vast majority of authors, as well as explaining the multifactorial character of the resorption process^[18-21]. In the patients with control group, mandibular bone loss was 2.5 times greater than

maxillary bone loss. The authors also observed greater bone loss in the premaxilla, in the cases group to a significant degree. According to the authors, most relevant data that was obtained, in the midline in which the loss was 0.32 mm/year in comparison with the control group, whose loss at the point indicated was 0.22 mm/year, this being is a statistically significant difference. As such, the authors deduce that greater resorption occurred at the midline of the premaxilla in patients wearing complete maxilla dentures with an overdenture on two implants on the antagonist arch. This loss occurred in a slower manner. In the mandibular midpoint over the 6 years, patients in the control group lost 3.01 mm. In this same location, for patients in the cases group the loss was 0.71 mm.

Moustafa Abdou Elsyad concluded that maxillary denture retention was significantly lower with telescopic-retained overdentures than with ball-retained overdentures. This may be attributed to the high retention and stability of mandibular overdentures retained with telescopic attachments compared to overdentures retained with ball attachments. Such high retention comes from the survival tight fit between the inner and outer crowns [22]. According to the authors bone resorption in the anterior area of maxilla occurred in both groups. The masticatory forces transmitted to the mandibular residual ridge via the tissue-supported posterior section of the over dentures may have result in a progressive tilting and setting of the overdenture, and unfavourable loading of the anterior region of the edentulous maxilla with subsequent increased bone resorption [23]. Similar maxillary anterior bone resorption was reported by other authors which reported significant vertical bone loss in the anterior maxilla in patients wearing a mandibular two-implant retained overdenture. The authors found that, anterior maxillary ridge resorption was significantly higher with telescopic-retained mandibular overdentures than with ball-retained overdentures. This finding could be attributed to the high retention and stability of mandibular overdentures obtained with telescopic attachments, which improve masticatory function and increase bite forces [24]. The increased resorption of the anterior part of maxilla compared to the posterior part of corresponded with the finding of *Krelsler et al.*, who found greater resorption in the anterior than in the posterior part of edentulous maxilla [25]. The reduced maxillary bone resorption with ball-retained overdentures may be attributed to the resilient matrix used with this attachment, which allows vertical, lateral, and rotational movement of the mandibular overdentures and makes the overdentures mainly mucosa supported.

Elsayad MA conducted a follow-up study of 5 years, and considered 5 years follow up adequate for bone resorption to occur as it had been observed that significant resorption of the premaxilla can occur in 2–4 years after restoration with a maxillary CD opposed by IRO [26]. The authors used panoramic radiography as it is used widely in clinical practice and is a part of many recall programmes. Therefore, the investigation of ridge resorption in large numbers of patients with these radiographs was considered to be feasible [25, 27]. According to the authors, bone resorption in the anterior area of maxilla occurred in both groups. The overdenture rotation around bars during mastication may have resulted in unfavourable loading of the anterior region of the edentulous maxilla with subsequent increased bone resorption [28, 29, 30]. The maxillary anterior bone resorption in this study was in line with the finding of other studies performed in patients wearing a mandibular two implant-retained overdenture [28, 31].

A mean reduction in areas was observed in patients wearing a maxillary CD and a mandibular overdenture supported by two implants and a custom-made round bar with Ackermann clip attachments [31]. The reported annual anterior ridge resorption in this study (0.26 mm) for clip-retained overdentures was also concurred with the finding of *Lechner and Mammen* [28] who noted 0.28-mm bone loss/year with significant reduction in the vertical dimension of the anterior maxillae at the follow-up assessment. The increased resorption of anterior part of maxilla compared with posterior part corresponded with the finding of *Kreisler, et al.* [25] who found a higher resorption in the anterior (5–12%) than in the posterior (2–7%) part of the edentulous maxilla opposed by mandibular bar-retained overdentures on two implants.

Amany A F concluded that a mandibular implant supported overdenture was an excellent treatment option for fully edentulous patients in terms of masticatory function, chewing ability and patient's satisfaction. According to authors to improve support and stability of a denture, various numbers of implants have been recommended for mandibular implant overdentures [32, 33]. The minimum number of implants required for adequate anchorage of a complete denture varies according to the prosthetic concept used [32, 33]. The use of 2 inter-foraminal implants has proved to be very successful in stabilizing and retaining an overdenture as well as it is the most favorable for implant position in terms of bone stresses and part of mastication force transiting through mucosa [34]. The authors concluded that there was a decrease in radiographic bone height. This decrease was always more in the posterior region than in the anterior region of maxillary jaw bone in both groups. By comparing maxillary bone height changes in both groups of this study, it was found that the posterior bone height changed more in Group II patients with single sympheseal implant mucosa supported overdentures than Group I patients with two implant-mucosa supported mandibular overdenture and these differences were statistically significant. This could be explained by loss of posterior support in patients of Group II and instability of the complete dentures, which contributes to an unfavorable stress distribution among the denture bearing areas which was in agreement with another study which they compared that found more pronounced maxillary bone resorption in patients with complete mandibular denture compared to patients with two implant-mucosa supported mandibular overdentures [35]. This also agrees with several studies [36-38] that found improved tissue health and reduced annual residual ridge resorption in supporting tissues of prostheses that oppose a mandibular implant overdenture. The authors also found a slight increase in the thickness of mucosa in the anterior region in both groups during follow up period, but this increase was non-significant.

Mohamed Samih Alsrouji recorded all scans of maxilla using one CBCT machine to ensure similar dimension and magnification as it has been shown that measurements on 3D models of human skulls taken from different CBCT machines produced statistically significant clinical differences [39]. Authors mainly focused on the anterior part of the maxilla, where the bones are usually thicker and bone segmentation process was relatively straight forward. The mean volume bone loss for the IRO group in this study was 7.25%, which is significantly more than for the CD group (mean: 2.60%, almost threefold). Authors were also able to map out the areas of predominant bone resorption in the anterior maxilla, which was on the buccal and occlusal region of the alveolar ridge, which may cause the width of the residual ridge of the maxilla

to decrease with time.

According to *Eatemad RT* all patients of this study were pleased with the excellent retention, stability, the higher biting force & the improved masticatory efficiency of their 4 implant mandibular overdentures or all on four implant hybrid prostheses. The results of the present study revealed that an ongoing bone resorption of the anterior maxilla had occurred during study period which was significant for the two studied groups at the period from 6- 12 months interval. Bone resorption was more pronounced in the anterior maxillary region than posterior area; this finding was in accordance with *Kreisler et al.* 2003,^[25] who observed greater resorption in the anterior part of the maxilla than in the posterior part, with a premaxilla loss percentage of between 5% and 12%. However; the amount of bone resorption reported in this study was much less than those recorded in two implant retained overdentures^[25]. The main reason for this was that all patients in the study were rehabilitated with a lingualized occlusion concept to avoid too much anterior pressure. This concept with no anterior teeth contact has also been recommended for implant-retained mandibular overdentures to preserve anterior maxillary bone.

According to *Radwa M. K.* the study recorded 0.19mm, and 0.05mm for LOD (supragingival Locator abutment), 0.19mm, and 0.004mm for POD, 0.194mm and 0.08mm for BOD as the average annual max-ARRR and max-PRRR, respectively. The authors also compared their findings with *Elsyad* in a 5-year study, reported 0.26 mm and 0.12 mm annual max-ARRR for combined implant-mucosal support and totally mucosa supported group, respectively^[40]. In the same study, the authors reported 0.09 mm and 0.1mm annual max-PRRR for combined implant-mucosal support and totally mucosa supported group, respectively. The authors concluded that the selected attachment type may cause different degrees of stability that may cause different prosthetic complications on the opposing maxillary complete denture.

Mohamed Saad Alrajhi concluded that in anterior maxillary areas, CD group showed significant higher bone loss than All-on-four group. The effect of prosthesis was that FP had 0.270 lower change maxillary bone loss than CD i.e. CD had 0.270 more bone loss compared to FP (All on four group). Which was in agreement with the findings of *Kelly* as he related anterior maxillary bone loss and flappy tissue formation to increased bone loading from the increased biting forces from the opposed natural mandibular anterior teeth and a class I removable partial denture over a 3-year period using cephalometric radiographs and found a loss of 1 to 3 mm of anterior maxillary ridge height. That was explained biomechanically as during loading the CD a fulcrum line will be formed at the area of premolar allowing the CD to rotate anteriorly compressing the anterior area of maxilla causing overloading and decompression to the posterior area, the anterior overloading was related to patient preference to bite on the remaining anterior teeth, over eruption of remaining anterior teeth and lower posterior bone resorption under class I partial denture^[41].

Conclusion

Within the limitations of this systematic review, following conclusions can be made-

1. The overall rate of resorption in the maxillary arch as reported by various authors was within much smaller proportion ranging from 0.22 +/- 0.1 mm/year.
2. Mandibular implant supported overdentures supported by 2-4 implants against maxillary complete denture can

prove to be a better treatment option in completely edentulous patients provided the overall intraoral condition is good.

References

1. Allen PF, Thomason JM, Jepson NJ, Nohl F, Smith DG, Ellis J. A randomised controlled trial of implant-retained mandibular overdentures. *J Dent Res* 2006;85:547-51.
2. Sahyoun NR, Krall E. Low dietary quality among older adults with self-perceived ill-fitting dentures. *J Am Diet Assoc* 2003;103:1494-9.
3. Geckili O, Bilhan H, Mumcu E, Dayan C, Yabul A, Tuncer N. Comparison of patient satisfaction, quality of life, and bite force between elderly edentulous patients wearing mandibular two implant-supported overdentures and conventional complete dentures after 4 years. *Spec Care Dentist* 2012;32:136-41.
4. Albrektsson T, Blomberg S, Branemark A, Carlsson GE. Edentulousness—an oral handicap. Patient reactions to treatment with jawbone-anchored prostheses. *J Oral Rehabil* 1987;14:503-11.
5. Naert I, Alsaadi G, Van Steenberghe D, Quirynen MA. 10-year Randomized Clinical Trial on the Influence of Splinted and Unsplinted Oral Implants Retaining Mandibular Overdentures: Peri-implant Outcome. *Int J Oral Maxillofac Implants* 2004;19(5):695-702.
6. Raghoebar GM, Meijer HJ, Slot W, Slater JJ, Vissink A. A systematic review of implant-supported overdentures in the edentulous maxilla, compared to the mandible: how many implants? *Eur J Oral Implantol* 2014;7(2):S191-201.
7. Sadowsky SJ. Mandibular implant-retained overdentures: A literature review. *J PD* 2001;86(5):468-473.
8. Feine JS, Carlsson GE, Awad MA, Chehade A, Duncan WJ, Gizani S *et al.* The McGill consensus statement on overdentures. Mandibular two-implant overdentures as first choice standard of care for edentulous patients. *Gerodontology* 2002;19:3-4.
9. Locker D. Patient-based assessment of the outcomes of implant therapy: a review of the literature. *Int J Prosthodont* 1998;11:453-61.
10. Kapur KK. Management of the edentulous elderly patient. *Gerodontology* 1987;3:5-4.
11. Assuncao WG, Zardo GG, Delben JA, Barao VA. Comparing the efficacy of mandibular implant-retained overdentures and conventional dentures among elderly edentulous patients: satisfaction and quality of life. *Gerodontology* 2007;24:235-8. 8 A. Kutkut *et al.* / journal of prosthodontic research 2018;62:1-9.
12. Rashid F, Awad MA, Thomason JM, Piovano A, Spielberg GP, Scilingo E *et al.* The effectiveness of 2-implant overdentures—a pragmatic international multi-centre study. *J Oral Rehabil* 2011;38:176-84.
13. Zarb GA. A panacea for the edentulous predicament. *Int J Prosthodont* 2013;26:405-6.
14. Takanashi Y, Penrod JR, Lund JP, Feine JS. A cost comparison of mandibular two-implant overdenture and conventional denture treatment. *Int J Prosthodont* 2004;17:181-6.
15. Khan KS, Kunz R, Kleijnen J, Antes G. Five steps to conducting a systematic review. *J R Soc Med* 2003;96:118-21.
16. Klemetti E, Lassila L, Lassila V. Biometric design of complete dentures related to residual ridge resorption. *J Prosthet Dent* 1996;75:281-4.

17. Roraff AR. Arranging artificial teeth according to anatomic landmarks. *J Prosthet Dent* 1977;38:120-30.
18. Atwood DA, Coy WA. Clinical, cephalometric, and densitometric study of reduction of residual ridges. *J Prosthet Dent* 1971;26:280-95.
19. Tallgren A. The continuing reduction of the residual alveolar ridges in complete denture wearers: a mixed-longitudinal study covering 25 years. *J Prosthet Dent* 1972;27:120-32.
20. Xie Q, Närhi TO, Nevalainen JM, Wolf J, Ainamo A. Oral status and prosthetic factors related to residual ridge resorption in elderly subjects. *Acta Odontol Scand* 1997;55:306-13.
21. Bergman B, Carlsson GE. Clinical long-term study of complete denture wearers. *J Prosthet Dent* 1985;53:56-61.
22. Weng D, Richter EJ. Maxillary removable prosthesis retained by telescopic crown on two implants or two canines. *Int J Periodontics Restorative dent* 2007;27:35-41.
23. Heckman SM, Winter W, Meyer M, Weber HP, Wichman MG. Overdenture attachment selection and the loading of implant and denture bearing area. Part-1: In-vivo verification of steriolithographic model. *Clin Oral Implants Res* 2001;12:617-23.
24. Fontijn-Tekamp FA, Slagter AP, Van't Hof MA, Geertman ME, Kalk W. Bite forces with implant retained overdentures. *J Dent Res* 1998;77:1832-1839.
25. Kreisler M *et.al.* Residual Ridge Resorption in edentulous maxilla in patients with implant supported mandibular overdentures; An 8 year retrospective study. *IJP* 2003;16:295-300.
26. Maxson BB, Powers MP, Scott RF. Prosthodontic considerations for the transmandibular implant. *J Prosthet Dent* 1990;63:554-8.
27. Kreisler M, Schulze R, Schalldach F, d'Hoedt B, Behneke A, Behneke N. A new method for the radiological investigation of residual ridge resorption in the maxilla. *Dentomaxillofac Radiol* 2000;29:368-75.
28. Lechner SK, Mammen A. Combination syndrome in relation to osseointegrated implant-supported overdentures: A survey. *Int J Prosthodont* 1996;9:58-64.
29. Thiel CP, Evans DB, Burnett RR. Combination syndrome associated with a mandibular implant-supported overdenture: a clinical report. *J Prosthet Dent* 1996;75:107-13.
30. Jacobs R, Van Steenberghe D, Nys M, Naert I. Maxillary bone resorption in patients with mandibular implant-supported overdentures or fixed prostheses. *J PD t* 1993;70:135-40.
31. Tymstra N, Raghoobar GM, Vissink A, Meijer HJ. Maxillary anterior and mandibular posterior residual ridge resorption in patients wearing a mandibular implant-retained overdenture. *J Oral Rehabil* 2011;38:509-16.
32. Kronstrom M, Davis B, Loney R, Gerrow J, Hollender L. A prospective randomized study on the immediate loading of mandibular overdentures supported by one or two implants: a 3 year follow-up report. *Clin Implant Dent Relat Res* 2014;16:323-9.
33. El-Sheikh AM, Shihabuddin OF, Ghoraba SM. Two versus three narrow-diameter implants with locator attachments supporting mandibular overdentures: a two-year prospective study. *Int J Dent* 2012;2012:285684.
34. Rosano G, Taschieri S, Franc J, Gaudy O, Testori T, Del Fabbro M. Anatomic assessment of the anterior mandible and relative hemorrhage risk in implant dentistry: A cadaveric study. *John Wiley & Sons. Clin Oral Impl Res* 2009;20:791-95.
35. Jacobs R, Van Steenberghe D, Nys M, Naert I. Maxillary bone resorption in patients with mandibular implant-supported overdentures or fixed prostheses. *J Prosthet Dent* 1993;70:135-40.
36. Nelson K, Heberer S, Glatzer C. Survival analysis and clinical evaluation of implant retained prosthesis in oral cancer resection patients over a mean follow-up period of 10 years. *J Prosthet Dent* 2007;98:406-10.
37. Burns D. The mandibular complete overdenture. *Dent Clin NA* 2004;48:603-23.
38. Tuncay O, Thomson S, Abadi B, Ellinger C. Cephalometric evaluation of the changes in patients wearing complete dentures. A ten-year longitudinal study. *J Prosthet Dent* 1984;51:169-80.
39. Cawood JI, Howell RA. A classification of the edentulous jaws. *Int J Oral Maxillofac Surg* 1988;17:232-236.
40. Elsyad MM, Ashmawy M, Faramawy A. The influence of resilient liner and clip attachments for bar-implant retained mandibular overdentures on opposing maxillary ridge. A 5-year randomised clinical trial. *Journal of Oral Rehabilitation* 2014;41:69-77.
41. AT. The continuing reduction of the residual alveolar ridges in complete denture wearers: a mixed-longitudinal study covering 25 years. *J Prosthet Dent* 1972;27:120-132.