



ISSN Print: 2394-7489  
ISSN Online: 2394-7497  
IJADS 2021; 7(4): 322-324  
© 2021 IJADS  
[www.oraljournal.com](http://www.oraljournal.com)  
Received: 10-08-2021  
Accepted: 12-09-2021

**War Firdous**

Resident Department of  
Orthodontics & Dentofacial  
Orthopaedics, Govt. Dental  
College and Hospital Srinagar,  
Jammu Kashmir, India

**Mushtaq Mohammad**

Professor & Head Department of  
Orthodontics & Dentofacial  
Orthopaedics, Govt. Dental  
College and Hospital Srinagar,  
Jammu Kashmir, India

## Reliability of panoramic radiograph to determine gonial angle

**War Firdous and Mushtaq Mohammad**

DOI: <https://doi.org/10.22271/oral.2021.v7.i4e.1390>

### Abstract

**Background:** Gonial angle shows a great amount of individual variation based on age and type of malocclusion. The present study was conducted to assess reliability of panoramic radiograph to determine gonial angle.

**Materials & Methods:** 90 subjects of both genders were selected. Orthopantomograms were taken in all subjects. Gonial angle was calculated from the intersection of two planes, i.e; plane of the ramus of the mandible and body of the mandible. In the lateral cephalograms, the gonial angle was measured at the point of intersection of the plane tangential to the lower border of the mandible and another line tangent to the distal border of the ascending ramus and the condyle.

**Results:** Out of 90 patients, males were 40 and females were 50. The mean gonial angle in lateral ceph in males was 118.2 degree and on OPG was 119.3 degree. The mean gonial angle in lateral ceph in females was 124.5 degree and on OPG was 122.7 degree. The difference was significant ( $P<0.05$ ).

**Conclusion:** Panoramic radiograph found to be efficient in assessing gonial angle as compared to lateral cephalogram.

**Keywords:** panoramic radiograph, lateral cephalogram, gonial angle

### Introduction

Orthodontic diagnosis is set of complex clinical expertise that requires radical data collection through diagnostics aids such as observational efficacy, clinical examinations and evaluation of records; that may not be restricted to clinical images, preliminary cast and radiographs [1]. The mandibular angle or jaw angle is usually referred to as “gonial angle [2].” It is a valuable indicator for assessing vertical growth pattern and symmetry of facial skeleton, and rotation of mandible [3]. Gonial angle shows a great amount of individual variation based on age and type of malocclusion [4]. It also has a key role in forensic sciences, as it can be used to assess age in extreme situations (i.e; mass destruction, murderous mutilation, missing individuals, etc.) [5]. Gonial angle has a key role during cephalometric analysis as it gives a valuable guideline to predict growth pattern and rotation of the mandible. In hyperdivergent or high angle cases the gonial angle tends to be increased (i.e; obtuse), which is depicted by downward and backward rotation of the mandible [6].

Panoramic radiograph or orthopantomogram (OPG) and lateral cephalogram are generally recommended in the diagnosis of dental and skeletal disharmony [7]. Panoramic X-ray technology is widely available and is used routinely to assess the mandibular structures. The advantages of decreased superimposition of the anatomical structure, as well as benefit of permitting the measurement of both right and left sides favor the use of panoramic radiography [8]. The present study was conducted to assess the reliability of panoramic radiograph to determine gonial angle.

### Materials & Methods

The study was carried out on orthopantomograms and lateral cephalograms by selecting 90 patients of both genders who had undergone fixed orthodontic treatment in the Post Graduate Department of Orthodontics & Dentofacial Orthopaedics, Government Dental College & Hospital, Srinagar. Ethical approval for the study was obtained before starting the study.

**Corresponding Author:**

**War Firdous**

Resident Department of  
Orthodontics & Dentofacial  
Orthopaedics, Govt. Dental  
College and Hospital Srinagar,  
Jammu Kashmir, India

Data such as name, age, gender etc. was recorded. Gonial angle was calculated from the intersection of two planes, i.e; plane of the ramus of the mandible and body of the mandible. In the lateral cephalograms, the gonial angle was measured at the point of intersection of the plane tangential to the lower border of the mandible and another line tangent to the distal border of the ascending ramus and the condyle. The gonial angle at the intersection of these planes was measured. Results thus obtained were subjected to statistical analysis. P value less than 0.05 was considered significant.

**Results**

**Table 1:** Distribution of subjects

Total- 90		
Gender	Male	Female
Number	40	50

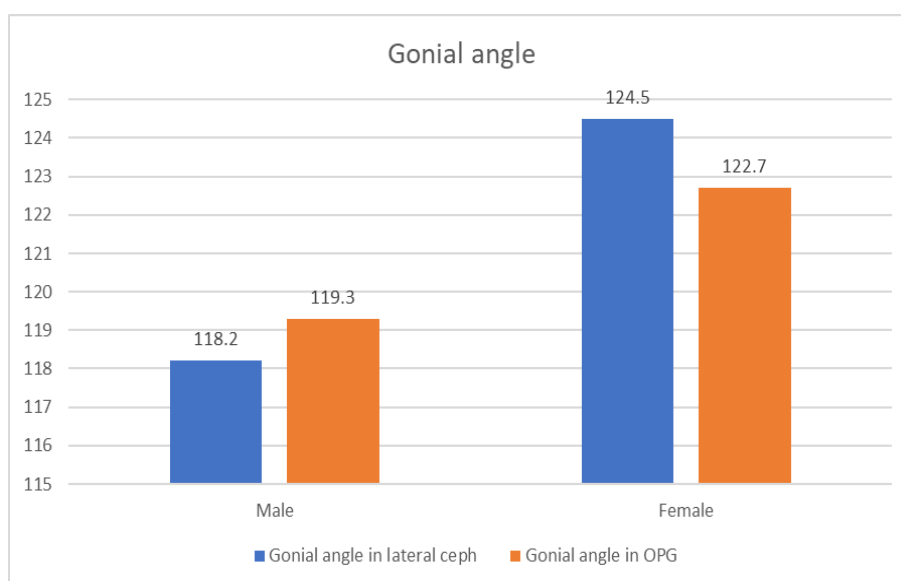
Table 1 shows that out of 90 patients, males were 40 and females were 50.

**Table 2:** Comparison of gonial angle between lateral cephalogram and OPG

Gender	Gonial angle in lateral ceph	Gonial angle in OPG	P value
Male	118.2	119.3	0.05
Female	124.5	122.7	0.02

Table 2, graph 1 shows that mean gonial angle in lateral ceph in males was 118.2 degree and on OPG was 119.3 degree. The mean gonial angle in lateral ceph in females was 124.5

degree and on OPG was 122.7 degree. The difference was significant ( $P<0.05$ ).



**Graph 1:** Comparison of gonial angle between lateral cephalogram and OPG

**Discussion**

The gonial angle is a good indicator of mandibular steepness and growth direction and therefore is required for various orthodontic treatment and orthognathic surgery. Gonial angle has been found to decrease in patient who has undergone surgical procedure for mandibular excess [9]. According to Brodie [10], the gonial angle is the posterior-inferior angle region of the mandible. Whereas Broca [11] considered it as the angle formed by a ramal plane and the mandibular plane. The tangent to the condyle and the mandibular angle region forms the ramal plane, while the mandibular plane is formed by the lower mandibular boundary. There is a pronounced notching of the lower border of mandible in conjunction with a steep mandibular plane and a large gonial angle [12]. The present study was conducted to assess reliability of panoramic radiograph to determine gonial angle.

In present study, we found that out of 90 patients, males were 40 and females were 50. Rajak *et al.* [13] investigated whether panoramic radiograph can be used as an alternative to lateral cephalogram for measuring the gonial angle in skeletal Class I patients. Panoramic radiograph and lateral cephalogram were collected from the pre-treatment records of 100 patients of the age 16-30 years. The mean gonial angle in lateral cephalogram was greater in panoramic radiograph, which was

statistically significant ( $P<0.05$ ). The mean gonial angle in female was found to be greater than the male patients in all radiographs. No significant difference was found between the mean gonial angle in lateral cephalogram and right panoramic radiograph. Linear regression analysis showed that, with a one-degree change in mean gonial angle in lateral cephalogram, the mean gonial angle in panoramic radiograph increases by 0.804 degree.

We found that mean gonial angle in lateral ceph in males was 118.2 degree and on OPG was 119.3 degree. The mean gonial angle in lateral ceph in females was 124.5 degree and on OPG was 122.7 degree. Memon *et al.* [14] compared three methods of gonial angle determination on a cephalogram with the method used to find gonial angle in an orthopantomogram, amongst three vertical groups (i.e; hyperdivergent, normodivergent and hypodivergent). A total of 178 panoramic and cephalometric radiographs of patients ranging from age 12-39y were used in this study. Gonial angle was constructed by three methods defined by Tweed's, Steiner's and Down's on the cephalogram and was then compared to the method of gonial angle determination on an OPG. The mean - difference between the values of different methods of finding Gonial Angle on cephalogram and orthopantomogram was found to be statistically significant (i.e;  $P = <0.05$ ) after Bonferroni

correction amongst three vertical groups. The value of gonial angle determination on an Orthopantomogram was found to be different when compared with the three methods (Tweed's, Steiner's and down's) of gonial angle determination on lateral cephalogram.

### Conclusion

Authors found panoramic radiograph to be more efficient in assessing gonial angle as compared to lateral cephalogram.

### References

1. Larheim TA, Svanaes DB. Reproducibility of rotational panoramic radiography: mandibular linear dimensions and angles. *American Journal of Orthodontics and Dentofacial Orthopedics* 1986;90:45-51.
2. Adil S, Awan MH, Khan I, Syed K. Comparison of the gonial angle measurements on Lateral Cephalogram and both hemispheres of Orthopantomogram. *POJ* 2016;7:48-50.
3. Mattila K, Altonen M, Haavikko K. Determination of the gonial angle from the orthopantomogram. *Angle Orthod* 1977;47:107-10.
4. Sharma VK, Tandon P, Singh GK *et al.* Evaluation of Skeletal Patterns Using Panoramic Radiography. *J Adv Res Dent Oral Health* 2017;2:1-8.
5. Nejad AM, Jamilian A, Meibodi SE, Hafezi L, Khosravi S, Cappabianca S *et al.* Reliability of panoramic radiographs for determination of gonial and Frankfurt mandibular horizontal angles in different skeletal patterns. *Stoma Edu J* 2016;3:18-22.
6. Akcam MO, Altioek T, Ozdiler E. Panoramic radiographs: a tool for investigating skeletal pattern. *American journal of orthodontics and dentofacial orthopedics* 2003;123(2):175-81.
7. Bibi T, Rasool G, Khan H. Reliability of orthopantomogram in determination of gonial angle. *Pak Oral Dent J* 2017;137:248-51.
8. Bhullar MK, Uppal AS, Kochhar GK, Chachra S, Kochhar AS. Comparison of gonial angle determination from cephalograms and orthopantoogram. *Ind J Dent* 2014;5:123-6.
9. Fischer-Brandies H, Fischer-Brandies E, Dielert E. The mandibular angle in the orthopantomogram. *Der Radiologe* 1984;24(12):547-9.
10. Araki M, Kiyosaki T, Sato M, Kohinata K, Matsumoto K, Honda K. Comparative analysis of the gonial angle on lateral cephalometric radiographs and panoramic radiographs. *Journal of oral science* 2015;57(4):373-8.
11. Brodie AG. On the growth pattern of the human head from the third month to the eighth year of life. *Am J Anat* 1941;68(12):209-62.
12. Broca P. Instructions craniologiques et craniometriques. *Mem. de la Soc. Anthropol. de Paris.* 1875;2:1203.
13. Rajak, Ravi Ranjan Kumar; Shrestha, Rabindra Man; and Koju, Sushmit. Reliability of Panoramic Radiography in Assessing Gonial Angle Compared to Lateral Cephalogram in Patients with Class I Malocclusion *Taiwanese Journal of Orthodontics* 2021;33:2.
14. Memon S. Comparison Between Three Methods of Gonial Angle Formation on Lateral Cephalogram and Orthopantomogram. *JPD* 2018;27(02):58.