



ISSN Print: 2394-7489  
ISSN Online: 2394-7497  
IJADS 2022; 8(1): 104-106  
© 2022 IJADS  
[www.oraljournal.com](http://www.oraljournal.com)  
Received: 23-10-2021  
Accepted: 26-12-2021

**Dr. Anuraj Vijayan**  
Department of Prosthodontics,  
I.T.S. Dental College, Hospital  
and Research Centre, Gautam  
Buddha Nagar, Uttar Pradesh,  
India

**Dr. Shubham Kumar Gupta**  
I.T.S. Dental College Hospital  
and Research Centre, Gautam  
Buddha Nagar, Uttar Pradesh,  
India, India

**Dr. Dhwanit Widhani**  
I.T.S. Dental College Hospital  
and Research Centre, Gautam  
Buddha Nagar, Uttar Pradesh,  
India, India

**Dr. Sunidhi Sharma**  
I.T.S. Dental College Hospital  
and Research Centre, Gautam  
Buddha Nagar, Uttar Pradesh,  
India, India

**Corresponding Author:**  
**Dr. Anuraj Vijayan**  
Department of Prosthodontics,  
I.T.S. Dental College, Hospital  
and Research Centre, Gautam  
Buddha Nagar, Uttar Pradesh,  
India

## Characterization of complete dentures using patient's intraoral photograph: A dental technique

**Dr. Anuraj Vijayan, Dr. Shubham Kumar Gupta, Dr. Dhwanit Widhani and Dr. Sunidhi Sharma**

DOI: <https://doi.org/10.22271/oral.2022.v8.i1b.1416>

### Abstract

Characterization of dentures allows for a more acceptable final prosthesis. Current characterization techniques require skill and understanding of various color dynamics for the fabrication of satisfactory esthetic denture prostheses. This technique allows the operator to have more control over the colors and unique characteristics of each patient and efficiently replicate them. To illustrate this technique, a printed close of an intraoral photograph of the arch was used to characterize a maxillary complete denture prosthesis.

**Keywords:** Characterized denture, Characterization, Internal characterization.

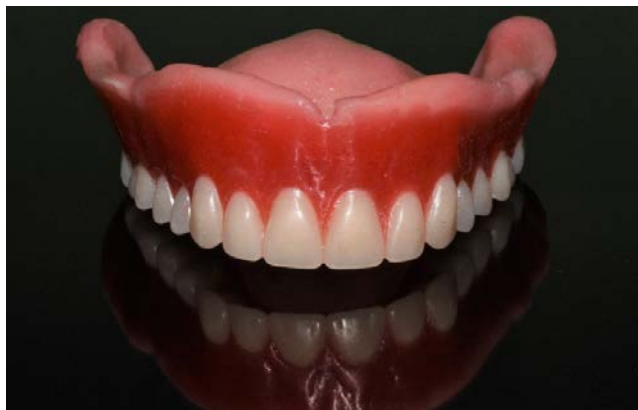### Introduction

Esthetic appearance of a complete denture is dependent as much on the denture base as on the denture teeth being used<sup>[1]</sup>. Characterization of denture base lends a life-like character to the otherwise lifeless prosthesis<sup>[2]</sup>. Multiple methods of characterization of dentures have been reported in literature including brush-on technique<sup>[3]</sup> using pigment impregnated polymer-monomer combination during packing of denture<sup>[4]</sup>, using custom pigmented veneers<sup>[5]</sup> and using custom pigmented tissue paper as a mode of internal characterization<sup>[2]</sup>. However, these techniques require above average technical skills to be completely satisfactory.

The laboratory technique described in this article simplifies characterization by using patient's intraoral photographs to replicate the complex color combination which is found in each individual's mouth, thus leaving no scope for error.

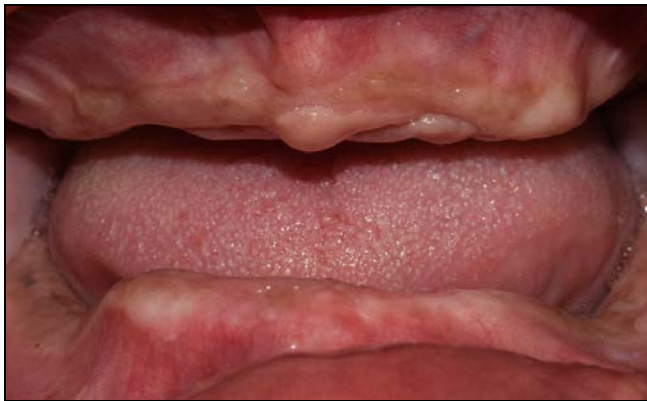### Technique

1. Try-in the waxed up contoured denture (Fig. 1). After patient's satisfaction with the same obtain consent for characterization of the denture.



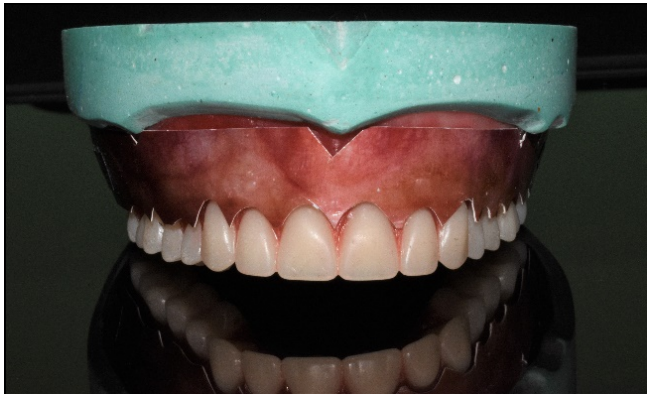**Fig 1:** Waxed up denture.

2. Take a close-up photograph of patient's edentulous arches (Fig. 2). With a laser printer, print the color image on any plain white paper.

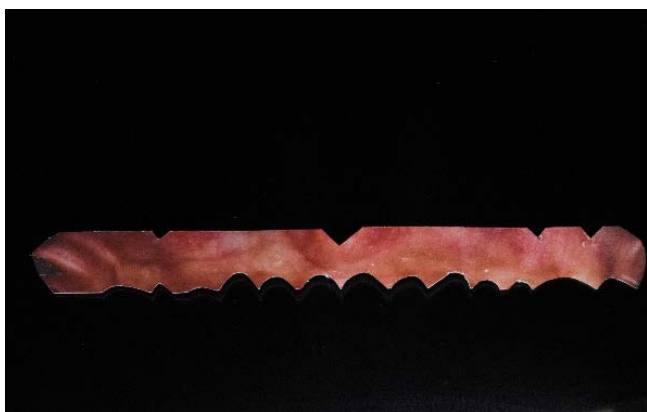

**Fig 2:** Close up intraoral photograph.

3. Cut the photograph along the gingival contours with the patient's trial denture acting as a guide and seal it using decoupage glue (Modge podge gloss, Pidilite Industries Ltd., India) (Fig. 3A and B).

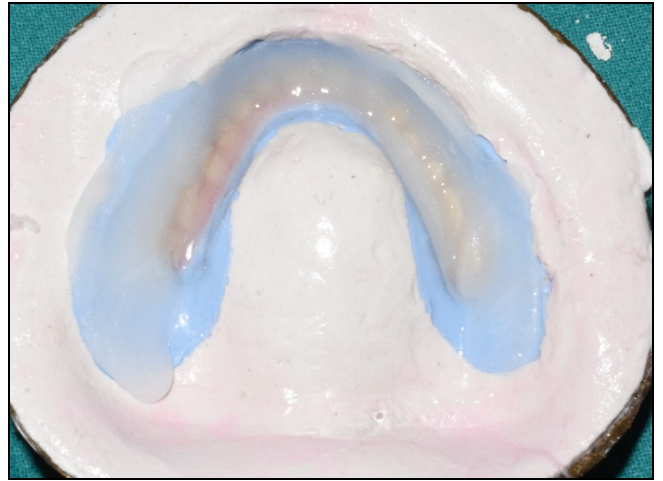


**Fig 3A:** Printed photograph cut according to denture's gingival contours

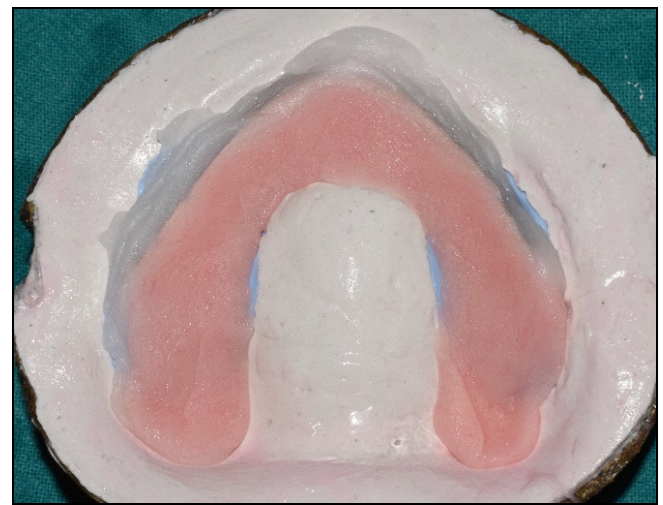

**Fig 3B:** Cut photograph post sealed with modge-podge.

4. Invest the denture, dewax and apply a thin layer of tin-foil substitute in areas of exposed stone in the usual manner.
5. Tack in the photograph carefully against a thin layer of clear, heat polymerizing PMMA (Trevalon; Dentsply Sirona) followed by packing with pink heat polymerizing PMMA (Trevalon; Dentsply Sirona) for processing of remaining denture parts (Fig. 4A and B).

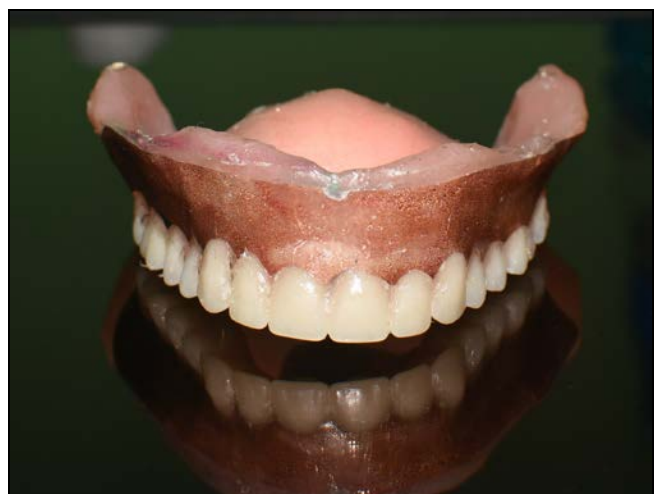

**Fig 4A:** Thin layer of clear PMMA adapted on the buccal aspect.



**Fig 4B:** Photograph embedded against clear acrylic followed by pink PMMA packing.

6. Process the denture using short polymerization cycle.
7. Retrieve the denture, finish and polish the denture (Fig. 5).



**Fig 5:** Final denture prosthesis.

**Discussion**

In this technique the outermost layer determines the intensity of the characterization. The thickness of outmost clear acrylic is paramount to the success of the natural shades of patient's intraoral mucosal picture showing through. It is advisable to

use a print color intensity that exactly mimics the intraoral condition or to use a darker shade if extra thickness of clear acrylic is necessary for reinforcement of the dentures buccal flange.

The decoupage glue which is used in this technique, effectively seals the complete picture and protects it against external agents such as residual monomer and heat which is derived while polymerization process is taking place. Also, upon drying the decoupage glue becomes completely clear and has a glossy appearance further enhancing the esthetics of the picture print. It is advisable to use two layers of decoupage glue, so that adequate thickness of the protective layer is formed.

Precise matching of patient's intraoral mucosal tints requires skillful mastery of colors and mixing thereof. Another major factor is the time involved in obtaining acceptable level of characterization through tinting. Although using pigments can yield excellent results when done by a capable clinician/technician, true replication would require a lot of effort in mimicking the intricacies of natural mucosa. Hence, it is the inherent advantage of this technique, by providing exact replication of intraoral situation also being much more efficient and removing the guesswork from the process.

Although this technique can be very useful in providing characterization, the inherent disadvantages lie in non-compliance with proper protocol. It is heavily dependent on the decoupage glue for sealing it against agents which might otherwise cause the pigments to leech out and give an unesthetic appearance. Also, precise position of the cut out is extremely important in when using this technique, otherwise failures in the form of paper extrusion or crimping can be expected.

### Summary

The prime advantage of the technique described in this article is the true replication of patient's mucosal color characteristics. This technique does not require any mixing or special technical skills when trying to mimic complex intraoral complexion, hence speculation regarding the same is completely avoided.

### References

1. Kemnitzer D. Esthetics and the denture base. *J Prosthet Dent.* 1956;6:603-15
2. Pattanaik S, Pattanaik B. Internal characterization of denture base by using acrylic stains and tissue paper. *J Indian Prosthodont Soc.* 2011;11:202-4.
3. Powers JL. Brush-on technique in natural coloring of cured cross-linked plastic artificial denture materials. *J Prosthet Dent.* 1953;3:350-353.
4. Choudhary SC, Craig JF, Suls FG. Characterization of the denture base for non-caucasian patients. *J Prosthet Dent.* 1975;33:73-79.
5. Pound E. Esthetic dentures and their phonetic values. *J Prosthet Dent.* 1951;1:98-111.