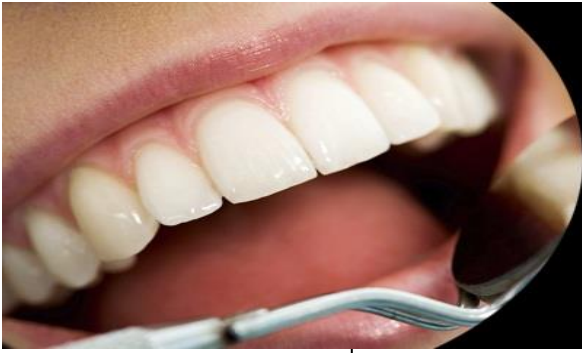



International Journal of Applied Dental Sciences

ISSN Print: 2394-7489
ISSN Online: 2394-7497
IJADS 2022; 8(2): 337-340
© 2022 IJADS
www.oraljournal.com
Received: 23-02-2022
Accepted: 25-03-2022

Dr. Shankar P Dange
Dean, Professor, Government
Dental College and Hospital,
Aurangabad, Maharashtra, India

Dr. Diksha T Dhage
2nd Year Postgraduate Student in
Prosthodontics, Government
Dental College and Hospital,
Aurangabad, Maharashtra, India

Dr. Kishor M Mahale
HOD, Department of
Prosthodontics, Government
Dental College and Hospital,
Aurangabad, Maharashtra, India

Dr. Smita A Khalikar
Associate Professor, Department
of Prosthodontics, Government
Dental College and Hospital,
Aurangabad, Maharashtra, India

Corresponding Author:
Dr. Shankar P Dange
Dean, Professor, Government
Dental College and Hospital,
Aurangabad, Maharashtra, India

Cusil denture: A new esthetic approach to improve retention, stability and preserve remaining natural teeth and bone in macroglossia patient

Dr. Shankar P Dange, Dr. Diksha T Dhage, Dr. Kishor M Mahale and Dr. Smita A Khalikar

DOI: <https://doi.org/10.22271/oral.2022.v8.i2e.1528>

Abstract

Edentulism is affecting the oral health of the patient debilitating their functional, esthetical and psychosocial demands. When very few natural teeth remains in the oral cavity, prosthetic rehabilitation can be possible by over denture, immediate denture, transitional denture or complete denture after complete removal of the remaining teeth. But when patient denies for extraction or any other treatment then transitional denture in the form of cusil denture is the best gentle option for the patient which is accompanied with the preservation of teeth and bone. This boosts the confidence of the patient by the presence of natural teeth along with proprioception during mastication. Cusil denture is a type of transitional denture which consist of holes in it for natural teeth which has a gasket of silicon relining material acting like a splint for periodically weak teeth.

Keywords: Cusil, macroglossia, soft silicon liner material

Introduction

Present day dentistry focuses on preservation of oral structures as said by 'Muller De van' that the perpetual preservation of that what remains is more important than meticulous replacement of what is missing. Thus preservation of teeth and ultimately bone can improve the condition of the prosthesis^[1]. But in developing countries the percentage of complete edentulism is more than partial edentulism^[2]. Consequences of teeth loss like bone resorption, sensory perception loss, functional and esthetic impairment, less intake of food makes the patient to face physiological and psychosocial challenges^[3]. Patients with few remaining natural teeth have options for prosthesis like overdenture, immediate denture and transitional denture. Overdenture has many prerequisites like proper positioning of the teeth, more visits of patients, economic considerations. And immediate denture stresses patient about extraction of many teeth at same time^[7] Cusil denture is a type of transitional denture which gives a good advantage of preserving the remaining natural teeth, bone loss, proprioception, esthetics, masticatory efficiency and self-confidence. It is a good treatment option for those patients who are not willing for extraction or any other procedures^[4, 5] among all the removable partial dentures cusil is the gentle and most economical opinion. Sometimes a complete denture can lead to failure because of less retention and stability reasons in resorbed ridges, macroglossia patients, knife-edge ridge. Hence preservation of even a single natural tooth can aid in retention and stability of the denture^[6]. Cusil denture is a tooth and tissue bearing acrylic denture which has holes for natural tooth to emerge through it and a gasket surrounding their neck by long term soft silicon liner.

Clinical report

A 52 year old man came to the Department of Prosthodontics, Government dental college and hospital Aurangabad. His chief complaint was masticatory insufficiency due to missing teeth. His past medical history was not relevant.

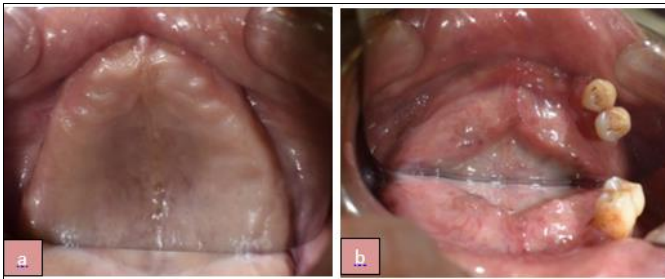


Fig 1: (a, b) Maxillary and mandibular arches with 34, 35 present in mandibular arch.

This makes the denture to be fabricated with good stability and support within the neutral zone. Patient was not willing for extraction of the mobile tooth or for root canal treatment. So a transitional denture – Cusil denture was planned in patient till the teeth gets exfoliate on their own.

Treatment procedure

1. Primary impression of maxillary and mandibular arch was recorded with medium fusing impression compound material,(DPI impression compound material)as no remarkable undercuts were present with 34, 35 and primary cast was obtained with dental plaster
2. Final impression was made by border moulding with low fusing impression compound (green stick) and wash impression with light body silicon impression material. (zhermack condensation silicon impression material)

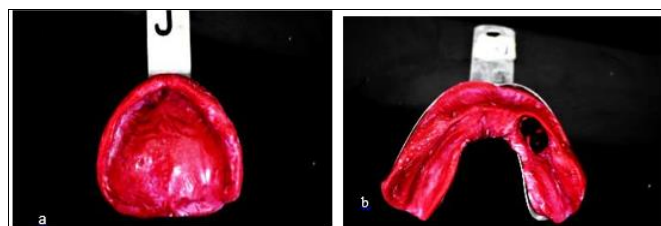


Fig 2: (a, b) Primary impression of maxillary and mandibular arches.

3. Master cast was poured in dental stone.
4. Denture base was constructed and wax rim was prepared.
5. Jaw relation and bite registration was recorded and mounted on mean value articulator.
6. Neutral zone was established using low fusing impression compound green stick.
7. Teeth arrangement was done according to the neutral zone recorded.
8. Try in of upper and lower teeth setting was done in patient oral cavity.

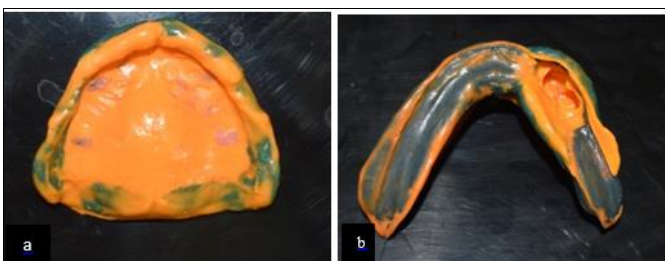

Fig 3: (a, b) Final impression of maxillary and mandibular arches in silicon impression material

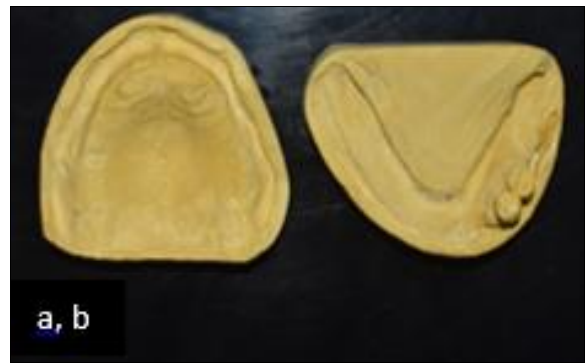

Fig 4: (a, b) Maxillary and mandibular secondary cast poured in dental stone.

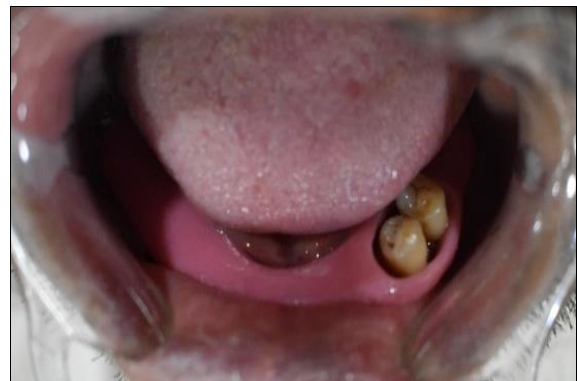

Fig 5: Record base prepared in mandibular denture accompanied with macroglossia.

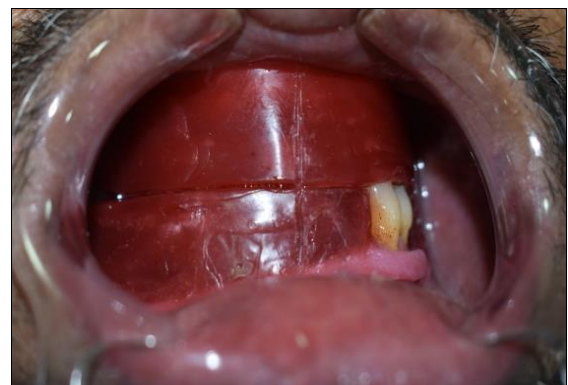

Fig 6: Bite registration and jaw relation was recorded.




Fig 7: Neutral zone was recorded in low fusing impression compound.

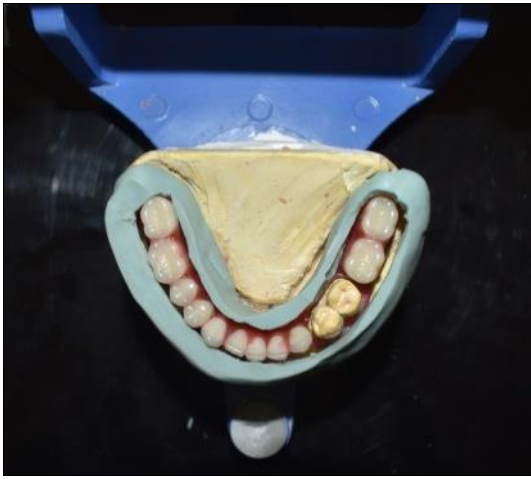

Fig 8: Teeth arrangement was done according to neutral zone recorded.

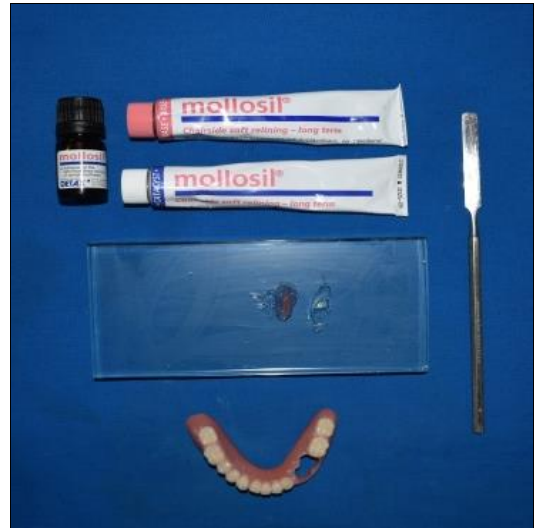

Fig 11: Soft silicon relining material

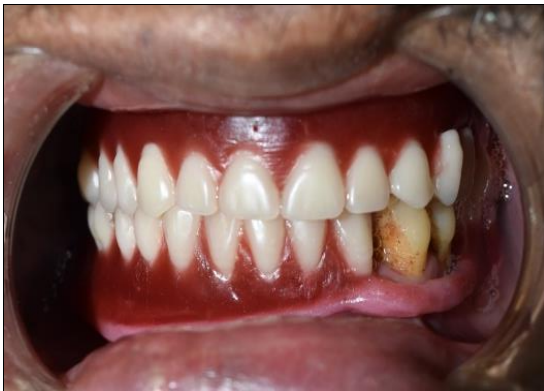

Fig 9: Try in of the teeth arrangement was done in patient.

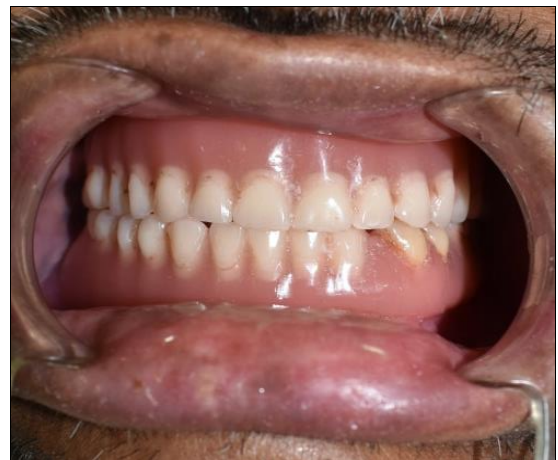

Fig 12: Denture positioned in mouth after silicon liner application.

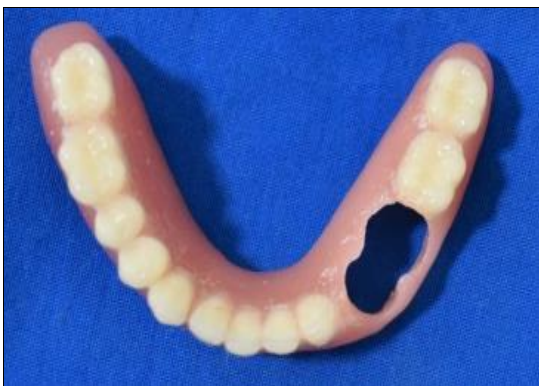

Fig 10: Lower denture fabricated with holes in it for natural teeth.

14 Post-operative instructions were given to patients about use of the denture, maintainance and hygiene.

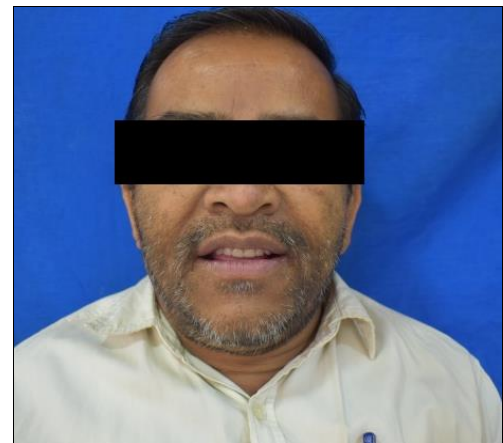

Fig 13: Post-operative view after denture delivery.

9. Fabrication of the denture was done in conventional manner by blocking the area around the teeth by putty.
10. Denture was retrieved consisting of holes in it for emergence of natural teeth and was finished and polished in usual manner.
11. Silicon liner adhesive was applied to the surrounding acrylic neck area of the denture and allowed it to dry for 10 second and inserted in patients mouth.
12. Silicon liner material consisting of base and catalyst was mixed and applied to the space area around the tooth cervical region of denture base, inserted in oral cavity and allowed to set for 3 minutes.
13. Denture was removed from mouth containing silicon rings and immersed in water for 1 minute.

Indications

1. Very few remaining natural teeth.
2. Periodontically compromised teeth.
3. Patients not willing for extractions or any other treatment.
4. When in need of transitional denture.
5. Single isolated teeth.

Contraindications

1. When too many natural teeth are remaining.
2. When severe soft and hard tissue undercuts are present.
3. High smile line patients.
4. Bruxism

Discussion

Prostodontics deals with rehabilitation of the patient functionally, esthetically as well as psychologically. When patient is having few remaining natural tooth with some compromised periodontal condition, extraction of the same leads to their psychological impairment as complete edentulism is a social stigma [8]. Edentulism was found to have significant effect on residual ridge resorption, decreasing alveolar bone height and surface area for retention and stability of complete denture. Specially mandibular dentures have more problems of retention and stability than maxillary denture. Partially edentulous arches with few remaining natural teeth have many options like overdenture, immediate denture and transitional denture [9]. But overdenture requires specific conditions of teeth like endodontic treatment, particular hygiene maintainance. And immediate denture gives the patient psychological stress of extraction of many teeth at once [10]. In that case when patient wants to save remaining natural teeth, transitional cusil denture serves a very promising treatment for them.

It gives better retention and stability than any other denture by preserving the natural teeth and bone in possible conditions. Denture gives retention and stability by remaining teeth resisting to lateral displacement and firm holding the neck of the teeth by elastomeric gasket creating a seal as in complete denture which flushes the food over it. Its advantage is that the vertical dimension, proprioception, esthetic demand (no metal clasp) and psychological stability of the patient is preserved [9, 12]. Some of its limitation are that it requires frequent corrections and has plaque accumulation as whole cervical region of the tooth is covered [5, 7]. If any tooth loss occurs in future this denture can be adjusted accordingly to include the missing teeth.

Conclusion

Cusil denture is the best option for those patients who have very few remaining natural teeth present and not willing for extraction or endodontic treatment. It preserves the teeth and bone which aids in retention and stability of the denture as compared to complete denture.

References

1. Jour, Savitha K, Manohara PS, Rajkumar E. 2021/06/10,130,134, FPD Supported Cu-Sil Like Denture A Simplified Approach to Preserve the Teeth and Bone,11,10.52403/ijhsr.20210618. International Journal of Health Sciences and Research.
2. Ines Polzer, Martin Schimmel, Frauke Müller, Reiner Biffar. Edentulism as part of the general health problems of elderly adults, International Dental Journal. 2010;60:3. DOI.org/10.1922/IDJ_2184Polzer13.
3. Jour, Morimoto, Yasuhir, Emami, Elham, DE Souza, et al. The Impact of Edentulism on Oral and General Health,10.1155/2013/498305. International Journal of Dentistry, Hindawi Publishing Corporation, 2013.
4. Jain JK, Prabhu CR, Zahrane MA, Esawy MS, Ajagannavar SL, Pal KS. Cu-sil dentures - a novel approach to conserve few remaining teeth: Case reports. J Int Oral Health. 2015 Aug;7(8):138-40. PMID:26464557;

PMCID: PMC4588780.

5. Charles PD, Anandapandian PA. An innovative restorative method for management of complex esthetic problems in partially edentulous mouth using the concept of Cu-sil denture. SRM J Res Dent Sci [serial online]. 2017 [cited 2022 Mar 30];8:303. <https://www.srmjrds.in/text.asp?2017/8/1/30/203484>
6. Jain JK, Prabhu CR, Zahrane MA, Esawy MS, Ajagannavar SL, Pal KS. Cu-sil dentures - a novel approach to conserve few remaining teeth: Case reports. J Int Oral Health. 2015;7(8):138-140.
7. Vinayagavel, Sabarigrinathan, Gunasekar. Hema Cusil like Denture - Case Report, International Journal of Health Sciences & Research (www.ijhsr.org). 2014 Feb;4:2.
8. Aman Arora, Viram Upadhyaya, Divya Malik, Kirti Rohilla. Cu-sil denture: conserving the remaining. Int. J. of Adv. Res. 2017 Jul;52086-2091. (ISSN 2320-5407). www.journalijar.com
9. Wael M, Zakaria. Fenestrated Denture: A Grace Option To Edentulous Patient. International Journal of Dental Sciences and Research. 2017;5(2)31-34. <http://pubs.sciepub.com/ijdsr/5/2/4>
10. Satyendra K, Kumar D, Legha VS, Arun Kumar KV. Specially designed tooth supported mandibular overdenture with enhanced retention. Med J Armed Forces India. 2015;71(2):S546-S548. DOI:10.1016/j.mjafi.2015.02.005
11. Nikolaos Topouzelis, Christos Iliopoulos, Olga Elpis Kolokitha, Macrogloussa, International Dental Journal, 2011;61:2. ISSN0020-6539, <https://doi.org/10.1111/j.1875-595X.2011.00015.x>.
12. Alqutaibi AY. A within-subject comparison of the conventional clasp-retained with attachment-retained removable partial dentures. J Taibah Univ Med Sci. 2020 Jun;29;15(4):305-311. DOI:10.1016/j.jtumed.2020.05.005. PMID:32982634;PMCID:PMC7479171.