



ISSN Print: 2394-7489
ISSN Online: 2394-7497
IJADS 2022; 8(2): 287-293
© 2022 IJADS
www.oraljournal.com
Received: 01-02-2022
Accepted: 03-03-2022

Dr. Shabana Azmin
PG Hostel, Institute of Dental
Studies and Technologies,
Kadrapad, Ghaziabad,
Uttar Pradesh, India

Dr. Narendra Kumar
Institute of Dental Studies and
Technologies, Kadrapad,
Ghaziabad, Uttar Pradesh, India

Dr. Vikram Kapoor
Institute of Dental Studies and
Technologies, Kadrapad,
Ghaziabad, Uttar Pradesh, India

Dr. Sidhartha Tomar
Institute of Dental Studies and
Technologies, Kadrapad,
Ghaziabad, Uttar Pradesh, India

Corresponding Author:
Dr. Shabana Azmin
PG Hostel, Institute of Dental
Studies and Technologies,
Kadrapad, Ghaziabad,
Uttar Pradesh, India

Applications of cone beam computed tomography in the field of prosthodontics: A review

Dr. Shabana Azmin, Dr. Narendra Kumar, Dr. Vikram Kapoor and Dr. Sidhartha Tomar

DOI: <https://doi.org/10.22271/oral.2022.v8.i2e.1520>

Abstract

Cone beam computed tomography (CBCT) is one of the latest radiographic modality available. It is use are enormous in medical and dental field. Among all CBCT is an essential commodity in the field of prosthodontics. The amazing capability of CBCT for providing sub-millimeter resolution in images of high diagnostic quality, with short scanning times (10–70 s) and radiation dosages reportedly up to 15–100 times lower than those of conventional Computed tomography scans are the unique features of CBCT. The aim of this article is to educate the Prosthodontist to CBCT technology, provide an overview of CBCT systems and review the specific application of various CBCT display modes to clinical Prosthodontics practice.

Keywords: Cone beam computed tomography, implants, prosthodontics, radiation, dentistry

Introduction

Radiology plays an important role in both diagnosis and treatment planning in the field of dentistry. The evolution of dental radiology goes back to year 1895 with the introduction of intraoral radiographs to the development of current radiologic modalities like Computed Tomography (CT), Magnetic Resonance Imaging (MRI) and Cone Beam Computed Tomography (CBCT).

Cone beam computed tomography is an extraoral radiographic modality that allows 3-dimensional imaging of hard tissue structures making it a successful investigative method in the field of dental and maxillofacial imaging ^[1].

Radiation exposure dose from Cone Beam Computed Tomography is ten times less than from conventional Computed Tomography scans during maxillofacial exposure ^[1]. Also, Cone Beam Computed Tomography has exceptional dimensional accuracy with the magnification of only 2% and shorter scanning times of approximately 60 seconds.

One of the major marvels of Cone Beam Computed Tomography is that it can be used to evaluate the success of bone grafts and provides reliable information regarding both qualitative and quantitative measurement of bone at lower radiation doses making it a very preferable imaging modality for pre and post treatment assessment in implant dentistry.

Apart from implant dentistry, Cone Beam Computed Tomography has proved to be a boon in the field of prosthodontics in general, as it has its uses in craniofacial and airway analysis, comprehensive treatment planning in overdenture patients. Cone beam computed tomography also gives useful information related to the thickness and perforations of sinus membrane, surgical access into the sinus and also the patency of osteomeatal complex, thus helping the prosthodontists to improvise the success of sinus implants and maxillary sinus grafts ^[2].

History

In 1995, an incredible evolution hits the field of medicine because of the astonishing discovery of X- ray by Sir Wilhelm Conrad Roentgen. In 1972, GN Hounsfield introduced computerized transverse axial scanning which led to the introduction of computed tomography.

In Japan Arai *et al.* and in Italy Mozzo *et al.* were working independently and their hardwork led to the introduction of Cone Beam Computed Tomography (CBCT) in Oral and

Maxillofacial application and like CT, CBCT offered both 3D imaging and more accurate imaging as compared to 2D imaging [3].

Hence, CBCT being both cost effective and easily accessible led to its swift entry in the field of dentistry which helped the dental professionals and teachers to explore the utilisation of CBCT technologies.

Dosage Consideration

The annual dose delivered to an individual in the year 2006 accounted for nearly 50% per capita doses from medical sources of radiation in the United States, compared with approximately 15% in 1980, hence a total increase of 470% was seen which is depicted in (Fig. 1) [1].

Radioactivity is believed to be the emission of ionizing radiation or particles because the spontaneous disintegration of atomic nuclei. This is measured by counting the number of atoms that spontaneously decay each second, reported in the unit becquerel (Bq), where 1 Bq equals 1 disintegration per second, and the more commonly used unit curie (Ci), where 1 Ci equals 3.7×10^{10} disintegrations per second. And exposure defined as is the charge which is produced in air from ionizing radiation and is measured in roentgen (R) [1, 3, 2, 4, 3].

Absorbed dose describes how much radiation is absorbed at a point or the amount of energy that the radioactive source deposits per unit mass of tissue or organ and is measured in gray (Gy). Absorbed dose is converted to equivalent dose, measured in sievert (Sv), by multiplying the quality of the radiation delivered. For x-rays, the quality factor is 1 [1, 3, 4].

The quantity of 'effective dose' is generally used to compare the doses from ionizing radiation from different sources or to the different parts of body. Effective dose is a sensitivity of different tissues within the human body. Effective dose cannot be measured during a CBCT scan, nor can it be measured at all, but it is a calculated quantity and represents the dose imparted to the body as a whole [4, 6].

Dose area product (DAP) may correlate moderately well with effective dose from CBCT. DAP is a measure of the air kerma, or the amount of kinetic energy released per unit mass when the x-ray beam is traveling through the air multiplied by the cross-sectional area of the x-ray beam incident on the patient. DAP is measured in units of $\text{Gy} \cdot \text{cm}^2$ and is a unit that has been most widely used in conventional radiography. DAP can then be loosely converted to effective dose using a conversion factor which is machine specific thing but can be somewhat generalized [7, 8].

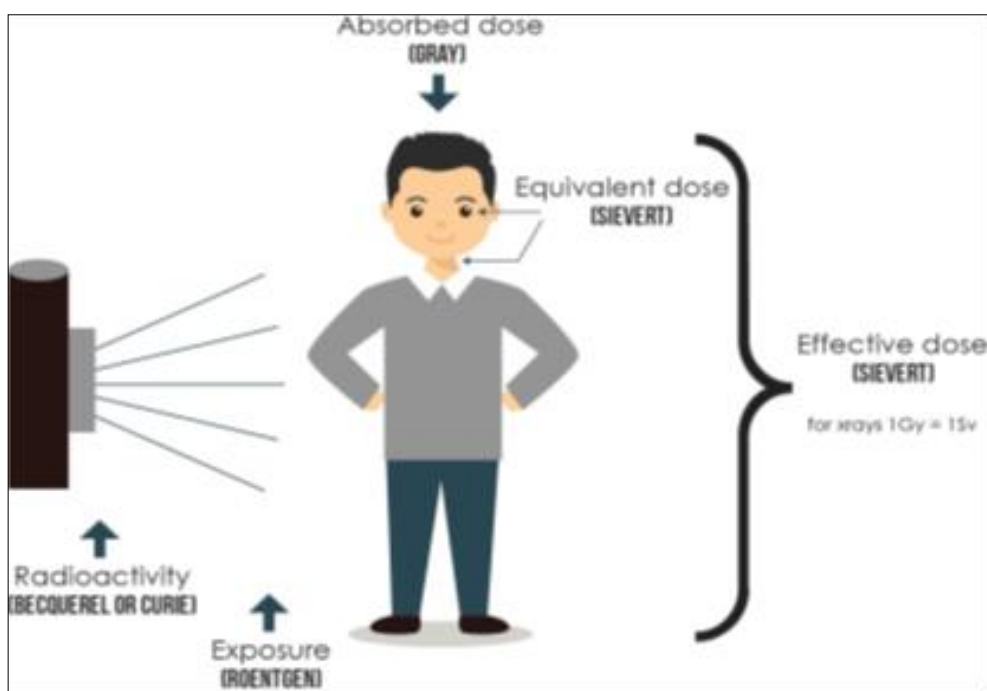


Fig 1: Radiation exposure and dose to humans. REM, roentgen equivalent man.

Age at exposure is critical for any radiation exposure in younger population because of increased cellular growth and continued organ development, as well as a longer latency period (longer life expectancy); they will have an inherently increased risk of cancer induction from radiation exposure. And between the ages of 10 and 15 years, age ceases to have a substantive impact on the magnitude of risk from radiation exposure [8, 9].

As reported by the United Nations Scientific Committee on the Effects of Atomic Radiation (known as UNSCEAR), dose is considered low if it is between 10 and 100 mSv and very low if it is less than 10 mSv

Components of CBCT

CBCT consists of rotational scan which rotates at an angle more than 180° . It consists of an x-ray source and a reciprocating detector moving synchronously around the patient's head (figure 2). These projection data are used to generate a 3D volumetric data set with the help of sophisticated algorithms which includes back-filtered projection. Primary reconstruction images in three orthogonal plane named axial, sagittal and coronal plane, are provided by these 3D volumetric data set. At the time of rotation, at fixed intervals many exposures are made, which provides single projection images known as BASIS IMAGES. The complete series of basis images is called PROJECTION DATA.




Fig 2: The first commercially available maxillofacial CBCT units in US; A) The NewTom 9000 DVT (QR sri, Verona, Italy) was a supine unit with fixed spherical field of view of 9 inches. B) The 3D accuitomo XYZ Slice view tomography (J. Morita corp, Kyoto, Japan) was a unit in which the patient was seated and produced a small volume, cylindrical FOV with a high resolution [26].

Current CBCT units are divided into two groups on the basis of detector type: image intensifier tube/charge-coupled device combination or flat-panel imager. The image intensifier tube configuration comprises an x-ray image intensifier tube coupled to a charge-coupled device with a fiber optic coupling.

Flat-panel imaging consists of detection of x rays with an “indirect” detector that is based on a large area solid-state sensor panel coupled to an x-ray scintillator layer. The most common flat-panel configuration consists of a cesium iodide scintillator applied to a thin film transistor made of amorphous silicon.

Principles of CBCT

All CT scanners consist of an x-ray source and detector mounted on a rotating gantry. The x-ray source transverses the object under study and within the object under study the intensity of x- ray is weakened. So, during rotation of the gantry, the left energy (attenuated) is detected by a sensor/phosphate/ a film and more or less is converted into GREY scales. These recordings constitute “raw data” that is reconstructed by a computer algorithm to generate cross-sectional images whose component picture element (pixel) values correspond to linear attenuation coefficients [12].

CT can be divided into two categories on the basis of acquisition x-ray beam geometry, as fan beam and cone beam. In fan beam CT the x- ray source rotates at a scan angle of 360° and a fan beam literally cuts through the object under study. The fan beam is received by the detector and the resultant image is two dimensional in nature and we can get several images and is based on the principle of reconstruction [2, 3, 6, 12]

In cone beam CT the shape of the x- ray bundle is unique that it CONE shaped. The result of the CBCT examination is a stack of images with 3- dimensional as all of these images have a defined slice thickness. Up to 1024 axial images can be performed. The principle behind the cone beam CT is similar to Fan beam CT that is reconstruction. So, when we put all the images together this is gained by the compilation. We can define any plane we want and any axis we want to see in order to examine the image anatomy. The image we get is truly 3 dimensional and is multiplanar reconstruction, as any plane within the volume can be chosen to examine [1, 13].

CBCT produces an entire volumetric dataset from which the voxels are extracted. Voxel dimensions are dependent on the

pixel size on the area detector. Therefore, CBCT units in general provide voxel resolutions that are isotropic — equal in all three dimensions [1, 2, 13, 15].

So Conventional CT equipment using a fan shaped X ray beam captures a series of axial plane slices or from a continuous spiral motion over the axial plane. A CBCT machine, on the other hand, uses a cone-shaped beam and a reciprocating solid-state flat panel detector, which rotates once around the patient (Figure 11), 180-360 degrees, covering the defined anatomical volume rather than slice-by-slice imaging found in conventional CT. This single scan (rotation) captures planned data (180-1024 2D images), unlike stacked axial slices found in CT, further reducing the absorbed x-ray dose from 6 to 15 times in comparison to CT [1, 3].

The captured 2D images are instantaneously conveyed to the computer, which reconstructs them, using modified Feldkamp algorithm into the anatomical volume for viewing at 1:1 ratio in axial, coronal, and sagittal planes (orthogonal planes). And the data is in the Digital Imaging and Communications in Medicine (DICOM) format, which enables ease of telecommunication and usage with other third-party imaging software [15].

Uses of CBCT

Oral and maxillofacial surgery: CBCT is helpful in examination of midfacial and orbital fractures including dentoalveolar fractures, post fracture evaluation, to examine the precise location and extension of pathologies (odontogenic and non-odontogenic tumors, cysts) of the jaws as well as osteomyelitis. Also, in cases of pathologic calcifications (e.g., tonsilloliths, lymph nodes, salivary gland stones) can also be recognized in terms of location and distinguished from possibly noteworthy calcifications, such as those occurring in carotid artery. The CBCT is very important for evaluation of unerupted / impacted or supernumerary teeth and their association with vital structures [1, 3, 6, 15].

Applications in orthodontics: Some of the orthodontic uses include assessment of palatal bone thickness, skeletal growth patterns, dental age estimation, visualization of impacted teeth tooth inclination and torque, determining available alveolar bone width for buccolingual movement of teeth, upper airway assessment and for planning orthognathic and facial orthomorphic surgeries. CBCT provides pictorial guides for

safe placement of mini implants, evading accidental and irreparable injury to the vital structures^[1,2].

Applications in TMJ disorders: CBCT imaging offers multiplanar and possibly three-dimensional images of the condyle and surrounding structures to enable analysis of TMJ and function and in cases in which asymmetry is suspected or surgery is a contemplated. CBCT enables to examine the joint space and the true position of the condyle in revealing likely dislocation of the joint disk, to quantify the roof of the glenoid fossa and assists in locating the soft tissue around the TMJ. These benefits drawn above have made CBCT the best imaging device for cases involving developmental anomalies of the condyle, trauma, fibro-osseous ankylosis, pain, dysfunction, and condylar cortical erosion, rheumatoid arthritis and cysts^[1,2].

Applications in endodontics. CBCT imaging is superior to 2D imaging in the description of periapical lesions, precisely demonstrating lesion juxtaposition to the maxillary sinus, sinus membrane involvement and lesion location relative to the mandibular canal. CBCT can be used to determine the number and morphology of roots and associated canals (both main and accessory) for establishing working lengths, and to determine the type and degree of root angulation and as well provides true assessment of root canal obturations. Detecting vertical root fractures measuring the depth of dentin fracture, and detecting horizontal root fractures. CBCT imaging not only allows for early detection of root resorption but it can also identify the extent of a lesion. Depiction of pulpal extensions in talon cusps and the localization of broken instruments are simplified by CBCT images^[1,2].

Applications in periodontics: CBCT is proved to be far better than 2D radiographs for the visualization of buccal and lingual defects due to absence of superimposition of the structures. CBCT provides accurate measurement of intrabony defects and let clinicians to evaluate furcation involvement, dehiscence, fenestration defects, and periodontal cysts and to assess postsurgical consequences of regenerative periodontal treatment^[1,2,20,21,22].

Cone-beam computed tomography (CBCT) and stereo photography

Cone-beam Computed Tomography (CBCT) and stereo photography are two of the latest imaging modalities available for three-dimensional (3-D) visualization of craniofacial structures. CBCT image scan be fused with extraoral facial (photographic) or intraoral (impression) optical data for diagnosis of dentofacial deformities, assessment of the interaction of hard tissue base with the soft tissue integument; monitoring and evaluation of changes over time; and planning orthognathic surgery. Also, CBCT have uses in general radiology, mainly in otolaryngological musculoskeletal, breast, respiratory and cardiac imaging. CBCT has also been used in spinal surgery.

3-D Reconstruction

Augmented 3-D reconstructed models can provide accurate visualization of the inter-occlusal relationship. The more advanced 3-D reconstruction consists of reconstructions of various structures like hard tissues, soft tissues and other tissues. Using 3-D reconstruction data surgeries can be planned and osteotomies can be performed. Hence, pre-surgical and post-surgical treatment planning can be evaluated

[1, 2, 24].

Advantage

Size and cost

CBCT has greatly reduced size because of reducing the size of the irradiated area by collimation of the primary x-ray beam by minimizing the radiation dose. Mostly CBCT units can be adjusted to scan small regions for specific diagnostic tasks. It is approximately one fourth to one fifth the cost of conventional CT.

Fast acquisition or rapid scan time

In conventional CT scanners, several fan beam rotations are necessary to complete the imaging of an object. But in CBCT all basis images are acquired in a single rotation, scan time is rapid mostly less than 30 seconds (10–70 seconds) and comparable with that of medical spiral MDCT systems.

Image accuracy or sub-Millimeter resolution

The volumetric data set voxels and the size of these voxels determines the resolution of the image. In conventional CT, the voxels are anisotropic — rectangular cubes while as in CBCT voxel resolutions are isotropic i.e., equal in all 3 dimensions. conventional CT voxel surfaces can be as small as 0.625 mm square, and their depth is usually in the order of 1–2 mm. Whereas CBCT produces the images with sub-millimeter voxel resolution ranging from 0.4 mm to as low as 0.125 mm. The coronal and MPR of CBCT data have the same resolution as axial data unlike conventional CT. And this kind of spatial resolution is very beneficial for the diagnosis and treatment of maxillofacial cases^[6,9,20,26].

Dose reduction

Published reports (2005 International Committee on Radiation Protection) indicate that the “conventional” fan-beam CT systems (average range for mandible 1,320–3,324 μsv ; average range for maxilla 1,031–1,420 μsv). While as the effective dose for various CBCT devices ranges from 52 to 1025 microsieverts (μSv). These values are approximately equivalent to 4 to 77 digital panoramic radiographs (approximately 2.9–13.3 μSv). CBCT provides a range of dose reductions of between 96% and 51% compared with conventional head CT (range 1400 to 2100 μSv). This also reduces the effective patient dose to approximately that of a film-based periapical survey of the dentition (13–100 μsv) 18–20 or 4–15 times that of a single panoramic radiograph (2.9–11 μsv)^[1,5,9,14,16,26].

Display modes unique to maxillofacial imaging

It provides the clinician with the opportunity to use chair-side image display, real-time analysis and MPR modes that are task specific. The entire volume can be reoriented so that the patient’s anatomic features are realigned as CBCT is isotropic. Also cursor-driven measurement algorithms allow the clinician to do real-time dimensional assessment. And the availability of cursor-driven measurement algorithms provides the practitioner with an interactive capability for annotation, and measurements.

Reduced image artifact

With the help of manufacturers’ artefact suppression algorithms and increasing number of projections, CBCT images can result in a low level of metal artifact, particularly in secondary reconstructions designed for viewing the teeth and jaws.

Disadvantages

Image noise

Noise is the additionally recorded x-ray attenuation, reflecting nonlinear attenuation and it contributes to image degradation. During the process of X ray projection of CBCT, a large portion of the photons undergo Compton scattering interactions and produce scattered radiation. And most of these scattered radiations are omni-directionally and are recorded by pixels on the cone beam area detector but it does not reflect the actual attenuation of an object along a specific path of the x-ray beam leading to noise formation.

The scattered radiation is proportional to the total mass of tissue contained within the primary x-ray beam and it this increases with increase in object thickness and field size. In clinical applications, the scatter-to-primary ratios are about 0.01 for single-ray CT and 0.05 to 0.15 for fan-beam and spiral CT and may be as large as 0.4 to 2 in CBCT. Additional sources of image noise in CBCT are

- Variations in the homogeneity of the incident x-ray beam and
- Added noise of the detector system (electronic).

The inhomogeneity of x-ray photons depends on the number of the primary and scattered x-ray absorbed the primary and scattered x-ray spectra incident on the detector and the number of views (projections). Electronic noise is due to the inherent degradations of the detector system related to the x-ray absorption efficiency of energy at the detector.

Poor soft tissue contrast

The spatial variation of the x-ray photon intensities that are transmitted through the patient is the contrast and it gives a measure of difference between regions in an image. Two principal factors limit the contrast resolution of CBCT. X-ray scatter reduces subject contrast by adding background signals that are not representative of the anatomy, thereby reducing image quality. Also scattered radiation contributes to increased noise of the image; it is also a significant factor in reducing the contrast of the cone beam system.

Second, there are numerous inherent flat panel detector-based artifacts that affect its linearity or response to x radiation. Also

- Saturation (nonlinear pixel effects above a certain exposure),
- dark current (charge that accumulates over time with or without exposure), and
- Bad pixels (pixels that do not react to exposure) contribute to nonlinearity.

Role of CBCT in implant dentistry

The increasing need of dental implant to replace missing dentition demands an excellent imaging modality to help the prosthodontist to access and diagnose the case, to measure the width and depth of available bone we have for the placement of implants which is amazingly fulfilled by the use of CBCT. Using CBCT helps us to avoid unwanted injuries to the vital anatomical structures like inferior alveolar nerve, mental nerve, adjacent roots etc. it provides us with accurate measurements of the bone and adjacent structures and with permitting precise measurement of distance, area, and volume.

It's far better than other imaging modalities in the aspects that it reproduces the anatomy with a submillimeter of accuracy. Also using specialized software allows cross-referencing and display of multiple view angles from a specific implant site.

The commonly viewed angles are axial, reconstructed panoramic and cross-sectional views of the jaws.

With a CBCT image, surgical guide can be fabricated, which is mostly used in the complete absence of the patient thus, allowing precise placement of implants, prefabrication of the abutments and prosthesis, and "same day" delivery of the prosthesis.

In the "prosthodontically driven implant" technique, a radiopaque marker (barium coated teeth) can be used to accurately demarcate the final tooth position. Cone beam computed tomography can be extremely beneficial in identifying areas of inadequate bone to support dental implants and being able to diagnose such shortcomings before the surgical procedure allows determining the volume of graft needed before surgery and which type of graft material to select. Imaging the surgical site post graft placement would help us to reveal the amount of bone formed and will also provide information on bone density.

Valuable information about the thickening and perforations involving the sinus membrane, patency of the osteo meatal complex along with ample amount of information to improve the success rate of grafting of the maxillary sinus and sinus implants also can be provided with the help of CBCT.

Marginal bone loss around implants is crucial pre-requisite for estimating implant success. Peri-implant bone loss is considered a good indicator of bone reaction to surgical intervention, implant loading and early implant failure. A 2-dimensional, periapical radiograph only allows evaluation of the proximal marginal bone level around implants. However, cone beam computed tomography (CBCT) provides cross-sectional images in the 3 dimensions that allow examination of the buccal and lingual bone levels around implants. The reconstructed 3D images are saved as Digital Imaging and Communications in Medicine (DICOM) files. Subsequently, horizontal (X and Y) planes at a right angle to the long axis of each implant are reconstructed to give 2 vertical cross-sectional images as follows: a mesiodistal (MD) image, which is formed by using a "curve tool" that bisects the alveolar ridge and the implants mesiodistally, and a buccolingual (BL) image, formed by the axis that bisects the implant buccolingually. This results in 4 circumferential measurements: distal (D), buccal (B), mesial (M), and lingual (L).

The level of the horizontal marginal bone (HBL) is determined by measuring the perpendicular distance between point C (the convergence point of a line representing the ridge [CD] and a second line tangent to the peri-implant crater [CB]) and the implant in millimeters. The subtractions of DIB and HBL at T1 and T3 from the values at T0 indicated vertical and horizontal bone loss (VBL and HBL_o).

Prosthodontists can use the implant radiographic guides to transfer the prosthodontic plan to the CBCT scan. A fabricated radiographic guide is positioned in the patient's mouth during the scan. The simple radiographic guide includes a radiopaque marker that indicates the desired placement position of an implant.

CBCT visualization of the prosthodontic plan allows the clinician to evaluate the subjacent anatomy, test the feasibility of the proposed implant placement and make needed modifications to the plan to optimize the spatial and functional relationships between the planned prosthetic treatment and the anatomy.

Prosthodontists have also facilitated the transfer of the crown-to-bone approach (transfer of virtual plan to surgical placement) by providing a surgical guide or template to help

surgeons to the intended tooth position and implant placement in favour with the intended treatment goals.

The radiographic guide can be modified to function as a surgical guide. A surgical guide can be designed and constructed on the basis of computer analysis of the available bone, the proximity of teeth to the proposed implant site. This can help prosthodontists to comprehend the optimal location of implant placement better and leading to successful outcome. A recent software development has simplified the process of implant planning and placement by eliminating the requirement for fabrication of a radiographic guide. This development allows the prosthodontists to scan both the patient's maxillofacial region of interest and the stone dental casts with CBCT. The scans are completed in less than a minute and from that point until the implant is placed, all planning and guide fabrication can be completed by means of a virtual patient model [3, 8, 17, 18].

The virtual environment uses a multi-object viewer in which patient-specific objects (including the maxillary and mandibular dentition created from stone cast scans, teeth and implant objects, and the CT scan of the jaw) can be combined in the same 3-D matrix for planning.

Comparison of CBCT with other imaging modalities

In the year 2008 Angelopoulos *et al.* studied to identify the mandibular canal in each 68 patients in both OPG and CBCT and reach to the conclusion that CBCT is better for the evaluation of mandibular canal precisely. In 2009 Dreiseidler *et al.* compared the images of OPG, CBCT and CT by five experience examiners and they concluded that the assessment of CBCT and CT is superior in comparison to OPG. Naitoh *et al.* in the year of 2010 compared CBCT and MSCT images of 28 patients and concluded that both the imaging modalities are able to depict the anatomic features of mandible properly. Yim *et al.* in 2011 compared the accuracy of OPG, OPG with steel ball, vs CBCT for each patient according to the tooth location and they concluded the use of steel bar is recommended for pre implant imaging of mandible but CBCT provides greater accuracy. Hu *et al.* in the year 2012 studied to compare between OPG vs CBCT imaging technique by calculating the measurement error between radiography and real specimen in 10 cadaver heads and concluded that for mandible pre implant imaging can be performed safely with the help of OPG but for maxilla CBCT is recommended. In comparison CBCT is much better than other modalities like OPG because of poor imaging and CT for its cost and more radiographic exposure to the patient.

Summary

The development and availability of CBCT in the market is undoubtedly increasing its access to the dental practitioners for the diagnosis and treatment planning of pathologies and concerns related to the maxillofacial regions.

The extra ordinary feature of CBCT is the ability of the technology to provide sub millimeters spatial resolution images of high quality along with relatively very low scanning time i.e., 10-70 seconds. The most promising feature of CBCT is to give better image as compared to conventional CT with minimum radiation exposure. Also, it is less costly than the conventional CT imaging technique.

Keeping in mind the limitations of CBCT like image artifacts, low soft tissue contrast, we can state that registration of surface scans on CBCT scans are more accurate method of prosthetic treatment plan incorporation than conventional radiographic templates.

Talking about the radiographic template made with the help of CBCT is proved to offers valuable information about the correct occlusal plane along with the location and inclination of the implant and restoration. And it helps to contribute significantly to better presurgical and reconstruction planning. CBCT may be a helpful method for evaluating implant abutments and (screw access hole) SAHs and for defining the location and direction of the SAHs in straight abutments were greater than that in angled forms. However, CBCT should only be used after careful consideration, especially about the patient exposure, where conventional 2D imaging techniques are not sufficient or where access to the technological processes such as guided surgery will improve patient management. It's suggested that OPG using calibration with defined steel balls as references seems more reliable in standard situations. But in cases which are more difficult to manage, modern three-dimensional techniques should be used to additionally examine the available bone volume for dental implants.

The effective dose of the original generation machine is more lowered by using the new generation of i-CAT CBCT scanner, for a similar FOV thus reducing the exposure. The reduction in the scanning time is probably the reasons for this decrease in effective dose, therefore less absorbed dose to the TLDs during the experimental set-up, which contributes to a lower overall effective dose to the patient. It is also advised to limit FOV according to the ROI to further reduce the dose to "as low as reasonably achievable" (known as 'ALARA') which is used to describe how radiation releases to the environment or exposure to humans should be moderated. Dentists should have a responsibility to balance diagnostic needs with dose and risk. It is very important to always think about why the scan is required and what is necessary to visualize and then to think how to achieve that with as low a dose as possible. There is an approximate risk of 1 in 1000000, of cancer from CBCT.

In summary, with the continued decrease in the cost and increase in availability of CBCT technology, it is only a matter of time until it finds its way into all clinical practices. The increased diagnostic capability combined with the lower radiation dose will bring this technology into the limelight. The use of 2-D or 3-D CT image-based planning for oral implant treatment is now widespread. These methods are helpful in the preoperative evaluation of the surgical site [13, 17, 25, 26].

Conclusion

Reduced radiation dosage and best imaging capacity of CBCT devices makes this device of choice for presurgical planning approaches. Considering the hype in cone beam CT, further adaptations, optimizations, and new developments will soon follow. The future may offer fully adaptable systems regarding exposure parameters and scanning volumes and image quality improvements.

Overall, CBCT may be a better alternative for preoperative radiographic assessment of potential implant sites appears promising as well a good imaging modality for the assessment of implant success rate by measuring the changes in the crestal bone level around the implant. In more difficult cases, modern three dimensional technique i.e CBCT should be used to additionally determine the available bone volume. In order to improve the quality of the treatment. It's recommended to use three CBCT.

References

1. Kumar M, *et al.* Cone-beam computed tomography-know its secret. *J Int Oral Health.* 2015;7(2):64-8.
2. John GP *et al.* Fundamentals of cone beam computed tomography for a prosthodontist. *J Indian Prosthodont Soc.* 2015;15(1):8-13.
3. Scarfe WC, Farman AG, Sukovic P. Clinical application of cone beam computed tomography in dental practice. *J Can Dent Assoc.* 2006;72(1):75-80.
4. Fornell J, *et al.* Flapless, CBCT-guided osteotome sinus floor elevation with simultaneous implant installation. I: radiographic examination and surgical technique. A prospective 1-year follow-up. *Clin. Oral Impl. Res.* 2011;23:28-34.
5. Arisan V, *et al.* Conventional multi-slice computed tomography (CT) or cone beam CT (CBCT) for computed aided implant placement. Part II; reliability of mucosa supported stereolithographic guides, 2012, 1-11.
6. Pertl L, *et al.* Preoperative assessment of the mandibular canal in implant surgery: comparison of diagnostic rotational panoramic radiography (OPG), computed tomography (CT) and cone beam computed tomography (CBCT) to the actual anatomical situation. *Eur J Oral Implantol.* 2013;6(1):73-80.
7. Logan H, *et al.* Evaluation of the accuracy of Cone Beam Computerized Tomography (CBCT): medical imaging technology in head and neck reconstruction. *J of Otolaryngol - Head & Neck Surg.* 2013, 42(25).
8. Tadinada A, *et al.* CBCT evaluation of buccal bone regeneration in postmenopausal women with and without osteopenia or osteoporosis undergoing dental implant therapy. *J Prosthet Dent.* 2015;114(4):498-505.
9. Kern F, *et al.* Accuracy of three-dimensional printed templates for guided implant placement based on matching a surface scan with CBCT. *Clinical Implant Dentistry and Related Research.* 2016;18(4):762-8.
10. Elsyad MA and Khirallah AS. Circumferential bone loss around splinted and non-splinted immediately loaded implants retaining mandibular overdentures: A randomized controlled clinical trial using cone beam computed tomography. *J Prosthet Dent.* 2016;116(5):741-8.
11. Charette JR, *et al.* Cone beam computed tomography imaging as a primary diagnostic tool for computer-guided surgery and CAD-CAM interim removable and fixed dental prostheses. *J Prosthet Dent.* 2016;116(2):157-65.
12. Asli HN, Kajan ZK and Gholizade F. Evaluation of the success rate of cone beam computed tomography in determining the location and direction of screw access holes in cement-retained implant-supported prostheses: An *in vitro* study. *J Prosthet Dent.* 2018;120(2):220-4.
13. Jamjoom FZ, *et al.* Positional accuracy of a prosthetic treatment plan incorporated into a cone beam computed tomography scan using surface scan registration. *J Prosthet Dent.* 2018;120(3):367-74.
14. Anenson JW, Till JE and Grogan HA. Understanding and communicating radiation dose and risk from cone beam computed tomography in dentistry. *J Prosthet Dent.* 2018;120(3):353-60.
15. Nakagawal Y, *et al.* Preoperative application of limited cone beam computerized tomography as an assessment tool before minor oral surgery. *Int. J. Oral Maxillofac. Surg.* 2002;31(3):322-26.
16. Davies J, Johnson B and Drage NA. Effective doses from cone beam CT investigation of the jaws. *Dentomaxillofacial Radiology.* 2012;41:30-6.
17. Hashimoto K, *et al.* Comparison of image validity between cone beam computed tomography for dental use and multidetector row helical computed tomography. *Dentomaxillofacial Radiology.* 2007;36:465-71.
18. Jeong DK, *et al.* Comparison of effective dose for imaging of mandible between multi-detector CT and cone-beam CT. *Imaging Science in Dentistry.* 2012;42: 65-70.
19. Repesa M, *et al.* Comparison of Results of Measurement of Dimensions of the Placed Dental Implants on Cone Beam Computed Tomography with Dimensions of the Producers of the Implants. *ACTA Inform Med.* 2017;25(2):116-20.
20. Moshfeghi_M, *et al.* Analysis of linear measurement accuracy obtained by cone beam computed tomography (CBCT-NewTom VG). *Dent Res J.* 2012;9(1):57-62.
21. Gibbs SJ, Nashville and Tenn. Effective dose equivalent and effective dose: Comparison for common projections in oral and maxillofacial radiology. *Oral Surg Oral Med Oral Pathol Oral Radiol Endod.* 2000;90:538-45
22. Naitoh M, *et al.* Evaluation of voxel values in mandibular cancellous bone: relationship between cone-beam computed tomography and multislice helical computed tomography. *Clin. Oral Impl. Res.* 2009;20:503-6
23. Sovitk A, *et al.* Adaptive radiotherapy based on contrast enhanced cone beam CT imaging *Acta Oncologica.* 2010;49:972-7.
24. Loubele M, *et al.* Comparison between effective radiation dose of CBCT and MSCT scanners for dentomaxillofacial applications *European Journal of Radiology.* 2009;71:461-8
25. Worthington P, Rubenstein J, Hatcher DC. The role of cone-beam computed tomography in the planning and placement of implants. *JADA* 2010;141(3):19-24.
26. White SC, Pharoah MJ. *Oral Radiology Principles and Interpretation.* Mosby Elsevier, 6th Edition, Chapter 14, 225-236.