



ISSN Print: 2394-7489  
ISSN Online: 2394-7497  
IJADS 2022; 8(2): 303-308  
© 2022 IJADS  
[www.oraljournal.com](http://www.oraljournal.com)  
Received: 10-02-2022  
Accepted: 12-03-2022

**Dr. Tanushree Khandelwal**  
Department of Orthodontics and  
Dentofacial Orthopedics, Jaipur  
Dental College, Jaipur,  
Rajasthan, India

**Dr. Vijay Agarwal**  
Department of Orthodontics and  
Dentofacial Orthopedics, Jaipur  
Dental College, Jaipur,  
Rajasthan, India

**Dr. Karamdeep Singh**  
Department of Orthodontics and  
Dentofacial Orthopedics, Jaipur  
Dental College, Jaipur,  
Rajasthan, India

**Dr. Lokendra Singh**  
Department of Orthodontics and  
Dentofacial Orthopedics, Jaipur  
Dental College, Jaipur,  
Rajasthan, India

**Dr. Shivangi Mittal**  
Department of Orthodontics and  
Dentofacial Orthopedics, Jaipur  
Dental College, Jaipur,  
Rajasthan, India

**Dr. Kaustubh Bhapkar**  
Department of Prosthodontics  
Crown, Bridge and  
Implantology, Jaipur Dental  
College, Jaipur, Rajasthan, India

**Corresponding Author:**  
**Dr. Tanushree Khandelwal**  
Department of Orthodontics and  
Dentofacial Orthopedics, Jaipur  
Dental College, Jaipur,  
Rajasthan, India

## **A comparative evaluation of changes in marginal alveolar bone in anterior maxilla caused by maxillary incisors intrusion using miniscrews and utility arch: A 3-dimensional study**

**Dr. Tanushree Khandelwal, Dr. Vijay Agarwal, Dr. Karamdeep Singh, Dr. Lokendra Singh, Dr. Shivangi Mittal and Dr. Kaustubh Bhapkar**

DOI: <https://doi.org/10.22271/oral.2022.v8.i2e.1523>

### **Abstract**

**Objective:** This study was performed to investigate the changes in alveolar bone after maxillary incisor intrusion and to determine the related factors in deep-bite patients.

**Material and Methods:** 20 maxillary central incisors of 20 patients were evaluated. The maxillary incisors in Group I (20 patients; mean age,  $22 \pm 1.32$  years) were intruded with a Utility-arch, while those in Group II (10 patients; mean age,  $20 \pm 2.71$  years) were intruded with miniscrews. Changes in the alveolar envelope were assessed using pre-intrusion and post-intrusion CBCT. Labial, palatal, and total bone thicknesses were evaluated at the crestal (3 mm) and mid-root (6 mm) levels. BACH, PACH, and BBH was evaluated. Paired t test was performed for quantitative variables.

**Results:** Upper incisor inclination and intrusion changes were significantly greater in Group II than in Group I.

**Conclusions:** Change in the labial inclination and the amount of intrusion should be considered during upper incisor intrusion, as these factors increase the risk of alveolar bone loss.

**Keywords:** CBCT, TADs, Utility Arch, BACH, PACH, BBH

### **Introduction**

Since the elementary era, overbite is an essential occlusal characteristic that has been the focused for treatment alterations<sup>[1]</sup>. Deep bite is one of the most common malocclusions seen in children as well as adults and is most difficult to treat successfully<sup>[2]</sup>. A deep bite is an intricate orthodontic problem that is a prevalent feature of many malocclusions<sup>[3]</sup>. Deep bite malocclusion can be elucidated as “the overlap on the labial surface of lower incisors by upper incisors when the accepted limit of 1–2 mm is surpassed”<sup>[1]</sup>. Bishara<sup>[2]</sup> described Deep bite as Malocclusion in which the maxillary incisors excessively overlap mandibular incisor crowns vertically when the teeth are in centric occlusion. For stability in function and retention and to establish the proper interincisal relationship the deep bite incisor relationship should be corrected<sup>[2]</sup>. Nonsurgical treatment procedures are concentrated on either intrusion of anterior teeth, extrusion of posterior teeth, or both. Several factors determine the choice of treatment, such as upper incisor visibility on rest and smile, interocclusal space, and vertical dimension<sup>[4]</sup>.

In deep bite patients with predisposition towards vertical growth pattern, opening bite by extruding posterior segments is not recommended. For such patient’s true incisor intrusion is an exquisite treatment opportunity<sup>[1]</sup>. In subjects with a normal vertical dimension, intrusion of the anterior teeth is recommended<sup>[3]</sup>.  $2 \times 4$  appliances or reverse curved arches are conventional methods for incisor intrusion<sup>[3]</sup>.

The introduction of skeletal anchorage as a source of stationary anchorage to orthodontic forces has made most complex tooth movements simple<sup>[5]</sup>. By application of intrusive forces close to the center of resistance, true intrusion can be achieved using miniscrews<sup>[3]</sup>. Miniscrews offer multiple advantages because of their small dimensions, of immediate

loading, multiple placement sites, relatively simple placement and removal [5].

The bone morphology of the patient and the biomechanics used during treatment are important factors that must be taken into account before orthodontic treatment [6]. Orthodontic forces can lead to different tissue responses, such as alveolar bone loss, gingival inflammation, root resorption, and pulpal reactions [6]. More marginal bone loss has been found in orthodontically treated subjects than in untreated subjects [7].

Cone-beam computed tomography (CBCT) has become immensely popular in multiple specialties of dentistry. With detailed 3-dimensional (3D) information, CBCT imaging offers clinicians and researchers a novel way to visualize and quantify bone-structure morphology and changes associated with diseases and treatments [8].

To our knowledge, only two previous study has used CBCT to evaluate changes in the alveolar bone after incisor intrusion using 2 different segmented arches. Given this lack of information, the primary purpose of the present study will be to evaluate the effect of maxillary incisor intrusion on alveolar bone height and thickness, using CBCT scans.

### Materials and Method

The Study was based on pretreatment and post-treatment CBCT of 20 patients. A total of 40 CBCT images (20 pretreatment and 20 post treatment), aged 18-28 years who were randomly selected from the patients visiting OPD of Department of Orthodontics and Dentofacial Orthopedics, Jaipur Dental College.

Subjects who satisfied all the following criteria were selected for the study; this includes subjects with Class I malocclusion or class II div 1 or div 2 malocclusion, No Expansion therapy, Patients with deep bite with unaesthetic maxillary incisor excess (5-8mm) at rest, No history of trauma to anterior teeth. Patients who have previously undergone orthodontic treatment, Patient with history of long-term medications, Patients with impacted canines, Patients with any Systemic diseases which can interfere with orthodontic tooth movement, Patients with periodontal or gingival problems, Alcoholics and Drug abusers, Pregnant ladies were all excluded from the study.

The treatment protocol was standardized using an MBT (McLaughlin, Bennett, Trevisi) pre-adjusted appliance (AO; American orthodontics, Washington ave, Sheboygan, USA) with 0.022-inch slots. After completion of levelling and alignment, 19X25 arch wire was placed for 1 month in all subjects following which intrusion was carried out.

The subjects were divided into two groups. Group I were treated using 17\*25 Titanium Molybdenum alloy intrusion utility arch and group II were treated using with 1.4-mm diameter and 8-mm length miniscrews.

Group I consisted of the CBCT images of 10 patients with a mean age of  $22 \pm 1.32$  years, while Group II consisted of the CBCT images of 10 patients with a mean age of  $20 \pm 2.71$  years. These patients had been treated previously with the 0.022-inch MBT prescription preadjusted brackets, applied to the maxillary central and lateral incisors, in combination with intrusion mechanics. Intrusion was started when leveling and alignment of the 4 maxillary incisors were completed.

In Group I, the  $0.017 \times 0.025$  titanium molybdenum alloy intrusion utility arch was applied to the maxillary incisors and the arch was inserted into the molar tubes with a gable-bend at the posterior segment with cinching-back. The active anterior part of the arch was adjusted to apply 60grams, as measured with a force gauge.

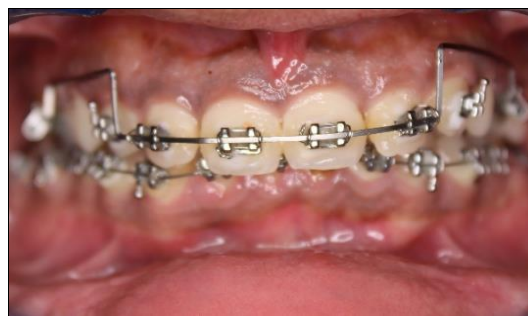

Fig 1 A: Pre-Treatment intrusion Image using utility arch

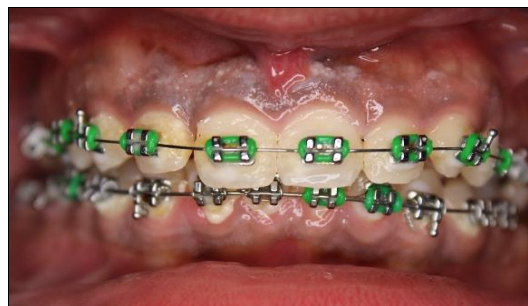

Fig 1 B: Post-Treatment intrusion Image using utility arch

In Group II, 1.4-mm diameter and 8-mm length miniscrews were inserted, using a self-drilling method, between the lateral incisors and canine, bilaterally. An intrusion force was obtained by using continuous E-thread from the  $0.019 \times 0.025$ -inch stainless steel arch-wire to the miniscrews. In both treatment groups, a total of 60 grams intrusion force (30 grams to the right and 30 grams to the left segment) was applied between the central and lateral incisors. Reactivations were applied every 4 weeks until adequate overbite was achieved.  $T_0$  and  $T_1$  CBCT images were used to evaluate changes in the alveolar bone. The intrusion duration was  $0.49 \pm 0.10$  years for Group I, and  $0.47 \pm 0.07$  years for Group II. The  $T_1$  CBCT was taken at a minimum of 6 months after the  $T_0$  CBCT.

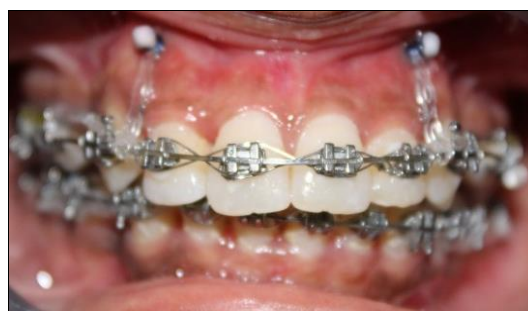

Fig 2 A: Pre-Treatment intrusion Image using Miniscrews

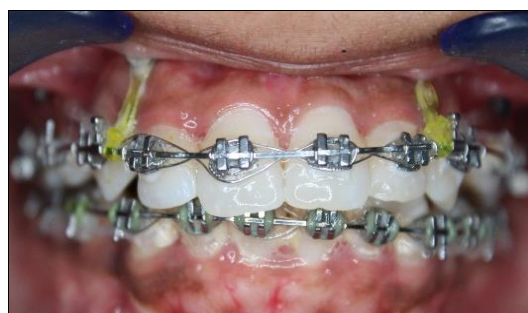

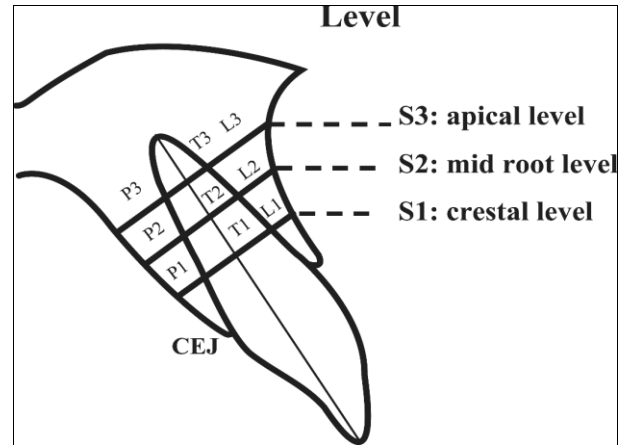
Fig 2 B: Post Treatment intrusion Image using Miniscrews

Control appointments were scheduled every 4 weeks, and the force level was checked at every appointment and adjusted whenever needed. No other treatment was performed until suitable overbite was achieved. Termination was done after 6 months of treatment or if one of the following was observed  
 1) Reaching adequate overbite  
 2) Severe inflammation or miniscrews failure.

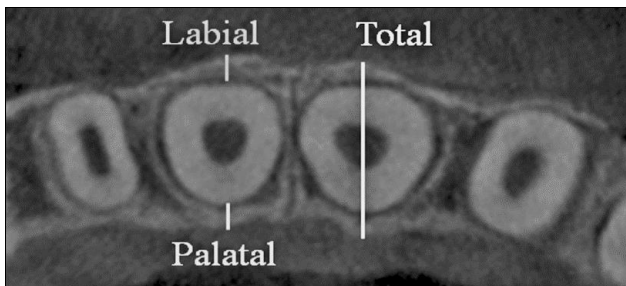
**3D-Image Cone-beam Computed Tomography**

Each subject was seated on a chair with his or her Frankfort horizontal (FH) plane parallel to the floor. A CBCT device (VATECH PAX I 3D smart scanner) was set to 94 kV/8 mA with an exposure time of 13 s. Patients were asked to occlude with maximum intercuspation and their lips and tongue in the resting position, and not to swallow, breathe, or move their head or tongue during image capture. Each 3D image consisted of 512 slices; with a slice thickness of 0.38 mm. Data was stored in Digital Imaging and Communications in Medicine (DICOM) format. The CBCT images were obtained with VATECH PAX I 3D smart scanner with a single 360° rotation, producing 306 basis images. All images had a medium or full field of view that allowed visualization of both the cranial base and the face. Primary and secondary reconstructions of the data were performed with E3 Plus software, leading to images with an isotropic voxel size of 0.2 mm. The labial, palatal, and total alveolar bone thicknesses for each maxillary central incisor were measured in 2 slices, separated by 3 mm, at the widest point of the labio-palatal root along the long axis from the cemento-enamel junction (CEJ). These measurements were defined as the labial bone thickness (LBT 3, LBT6mm), palatal bone thickness (PBT 3, PBT 6mm), and total bone thickness (TBT 3, TBT 6mm). The alveolar thickness of each side and the level of the maxillary right and left incisors were averaged to obtain the mean thickness. (FIG)


On the sagittal-cross section of the maxillary incisors, labial and palatal aspects were measured as the distance from the most apical portion of the CEJ to the most coronal portion of the marginal alveolar bone crest, defined as the buccal alveolar crestal height (BACH) and the palatal alveolar crestal height (PACH), respectively. Buccal bone height (BBH) measurements were defined as the linear distance between the most incisal point of the tooth's crown to the buccal alveolar crest along the long axis of the tooth.



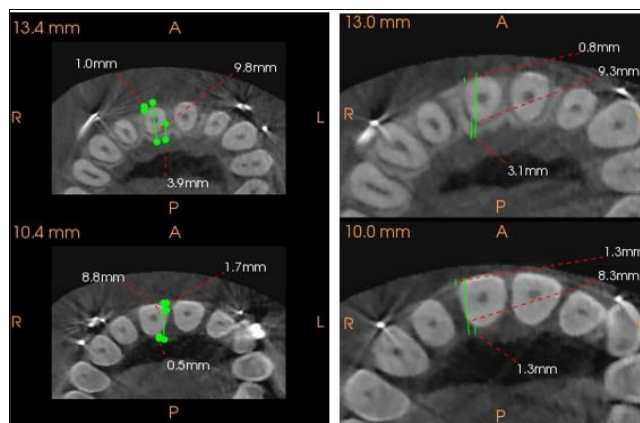
**Fig 4:** Location of the pre- and intrusion bone thickness measurements



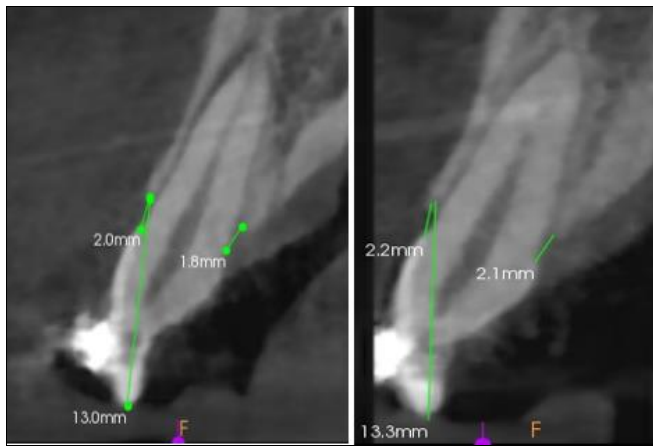
**Fig 3:** Measurement of maxillary tooth bone plate thickness; Location of alveolar bone thickness measurements LBT, Labial bone thickness; TBT, total bone thickness, PBT, palatal bone thickness.



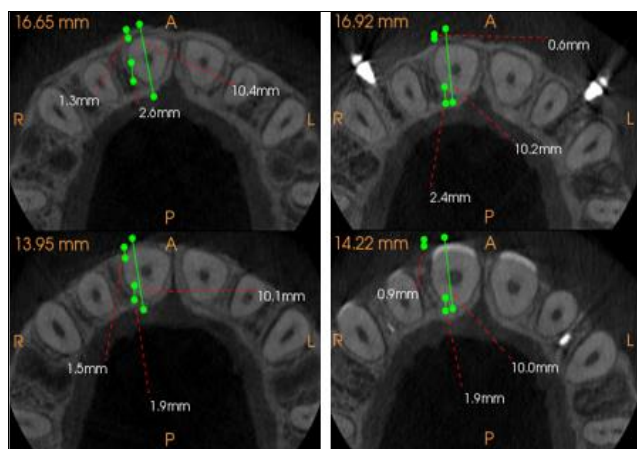
**Fig 5:** Location of alveolar bone height measurements. PACH, Palatal alveolar crestal height; BACH, buccal alveolar crestal height; BBH, buccal bone height.



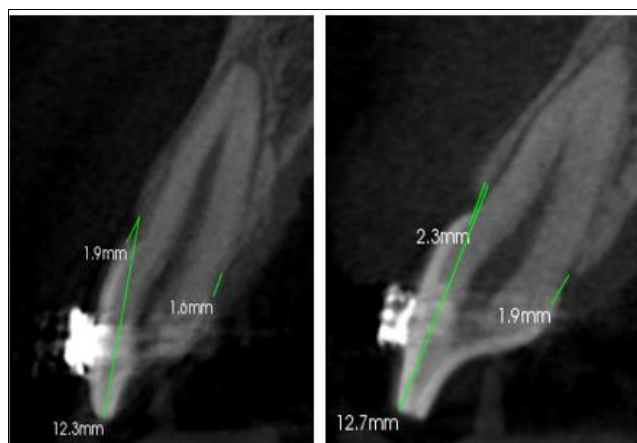
**Fig 6:** Pre and post treatment CBCT measurement of LBT, Labial bone thickness; TBT, total bone thickness, PBT, palatal bone thickness. Using intrusion arch (Group I)



**Fig 7:** Pre and Post Treatment CBCT measurement of alveolar bone height; PACH, Palatal alveolar crestal height; BACH, buccal-alveolar-crestal height; BBH, buccal bone height Using intrusion arch(Group I)



**Fig 8:** Pre and post treatment CBCT measurement of LBT, Labial bone thickness; TBT, total bone thickness, PBT, palatal bone thickness using Miniscrews (Group II)



**Fig 9:** Pre and Post Treatment CBCT measurement of alveolar bone height; PACH, Palatal alveolar crestal height; BACH, buccal-alveolar-crestal height; BBH, buccal bone height using Miniscrews. (Group II)

**Results**

The data collected was subjected to statistical analysis using Statistical Package for Social Sciences (SPSS, IBM version 20.0). The level of significance was fixed at 5% and  $p < 0.05$  was considered statistically significant. Paired t test was performed for quantitative variables. In the present study there are highly significant changes in the

post Treatment results in both group I (Intrusion Arch) and group II (Miniscrews). However, the mean difference is greater in miniscrews when compared to Intrusion arch demonstrating greater changes seen with Miniscrews.

**Table 1:** Demonstrates the Difference in the Buccal Alveolar Crest Height Between Group I and Group II before and after intrusion

BACH	Pre	Post	Mean Difference	P value
Group I	2.88±3.49	3.32±3.65	0.44	<0.001 HS
Group II	2.02±0.49	2.98±0.4	0.96	<0.001 HS

**Inference:** Post Treatment results shows Highly significant <0.001 (p value) changes in Group I and II, however mean difference shows greater increase in BACH in Group II.

**Table 2:** Demonstrates the Difference in the Palatal Alveolar Crest Height Between Group I and Group II before and after intrusion

PACH	Pre	Post	Mean Difference	P value
Group I	1.51±0.38	1.79±0.38	0.28	<0.001 HS
Group II	1.68±0.23	2.2±0.31	0.52	<0.001 HS

**Inference:** Post Treatment results shows highly significant <0.001 (p value) changes in Group I and II, however mean difference shows greater increase in PACH in Group II.

**Table 3:** Demonstrates the Difference in the Buccal Bone Height Between Group I and Group II before and after intrusion

BBH	Pre	Post	Mean Difference	P value
Group I	13.34±0.43	13.84±0.36	0.5	<0.001 HS
Group II	12.8±0.45	13.99±0.55	1.19	<0.001 HS

**Inference:** Post Treatment results shows highly significant <0.001 (p value) changes in Group I and II, however mean difference shows greater increase in BBH in Group II

**Table 4:** Demonstrates the Difference in Pre and Post intrusion comparison of changes in LBT3

LBT3	Pre	Post	Mean Difference	P value
Group I	1.65±0.11	1.29±0.09	0.36	<0.001 HS
Group II	1.62±0.26	0.9±0.17	0.72	<0.001 HS

**Inference:** Post Treatment results shows Highly significant <0.001 (p value) changes in Group I and II, however mean difference shows greater decrease in LBT3 in Group II.

**Table 5:** Demonstrates the Difference in Pre and Post intrusion comparison of changes in LBT6

LBT6	Pre	Post	Mean Difference	P value
Group I	1.23±0.17	0.91±0.12	0.32	<0.001 HS
Group II	1.09±0.29	0.64±0.12	0.45	<0.001 HS

**Inference:** Post Treatment results shows highly significant <0.001 (p value) changes in Group I and II, however mean difference shows greater decrease in LBT6 in Group II.

**Table 6:** Demonstrates the Difference in Pre and Post intrusion comparison of changes in PBT3

PBT3	Pre	Post	Mean Difference	P value
Group I	1.7±0.21	1.49±0.2	0.21	<0.001 HS
Group II	1.77±0.22	1.44±0.16	0.16	0.053

**Inference:** Post Treatment results shows highly significant <0.001 (p value) changes in Group I however mean difference shows greater decrease in PBT3 in Group I.

**Table 7:** Demonstrates the Difference in Pre and Post intrusion comparison of changes in PBT6

PBT6	Pre	Post	Mean Difference	P value
Group I	3.45±0.5	3.15±0.08	0.3	0.105
Group II	2.45±0.27	2.47±0.59	-0.02	0.882

**Inference:** Post Treatment results illustrates greater decrease in PBT6 in Group I.

**Table 8:** Demonstrates the Difference in Pre and Post intrusion comparison of changes in TBT3

TBT3	Pre	Post	Mean Difference	P value
Group I	9.37±0.23	9.45±0.31	0.08	0.73
Group II	9.17±0.22	9.14±0.30	-0.03	0.87

**Inference:** Post Treatment however mean difference shows decrease in TBT3 in Group I and II.

**Table 9:** Demonstrates the Difference in Pre and Post intrusion comparison of changes in TBT6

TBT6	Pre	Post	Mean Difference	P value
Group I	9.4±0.87	8.75±0.61	0.65	<0.001 HS
Group II	9.57±0.75	8.48±0.9	0.73	<0.001 HS

**Inference:** Post Treatment results shows Highly significant <0.001 (p value) changes in Group I and Group II however mean difference shows greater decrease in TBT6 in Group II.

## Discussion

One of the objectives of orthodontic treatment is to establish a normal overbite [9]. The location of the maxillary incisors, peculiarly with the upper lip, is a crucial factor in determining the type of treatment [5]. Maxillary incisor intrusion is the treatment of choice in patients with an excessive gingival display [3]. Advantages of true intrusion of anterior teeth involves attainment of lip competency, diminished incisal exposure without any accentuation of lower anterior facial height [10].

Intrusive arches are in wide spread use; undesirable side effects such as extrusion of posterior teeth and flaring of anterior teeth may compromise their efficiency [11]. Considerable clinicians applied segmental mechanics with the support of TADs following the revolutionary introduction of temporary bone anchorage devices (TADs) for orthodontic usage [4]. Direct application of intrusive forces from miniscrews provides competent alternative.

There is a risk of aggravation of the periodontal condition during Orthodontic treatment, especially that involving intrusive movements [12].

With the advent of 3-dimensional imaging modalities such as cone-beam computed tomography (CBCT) has made it possible to qualitatively and quantitatively evaluate the height and thickness of the alveolar bone and the length and thickness [13]. This CBCT study was performed to evaluate the alveolar bone loss around the maxillary central incisors that is induced by two different intrusion mechanics (intrusion-arch and miniscrew), after the leveling and aligning stage.

The Difference in the Buccal Alveolar Crest Height Between Group I and Group II pre and post intrusion specified significant <0.001 (p value) changes in Group I and II, however mean difference shows greater decrease in BACH in Group II. This can also be related to the increase in the labial tipping and intrusion of incisors in Group II which can be associated with the increase in BACH in Group II. Tian *et al.* [14] described that normally inclined maxillary incisors had

more bony support and decreased frequency of alveolar bone defects than lingual-inclined maxillary central incisors.

The difference in the Palatal Alveolar Crest Height (PACH) between Group I and Group II before and after intrusion post treatment results shows highly significant <0.001 (p value) changes in Group I and II, however mean difference shows greater increase in PACH in Group II. Son [15] compared the angle between U1 and alveolar bone surface prior to and post treatment and described, that the resorption of palatal alveolar bone were not significantly related with age and the amount of retraction and intrusion of maxillary incisors. On the other hand, Bae [16] reported that palatal bone dehiscence was noted in a skeletal class II case patient who underwent maxillary incisor intrusion and retraction at the end of treatment.

The difference in the Buccal Bone Height (BBH) between Group I and Group II before and after intrusion illustrates post treatment results shows highly significant <0.001 (p value) changes in Group I and II, however mean difference in Group I is 0.5 and Group II is 1.19 depicting greater increase in BBH in Group II.

We found a statistically significant decrease in labial alveolar bone thickness at the crestal (3mm) and mid-root (6mm) levels in the miniscrew group (Group II). Significantly greater changes were observed in the miniscrew group than in the intrusion-arch group (Group I), which might be related to greater changes in inclination and intrusion of the maxillary incisors. In the present study, the lingual inclination of the maxillary incisors at the T0 was greater in the miniscrew group, which might be a factor in the greater labial alveolar bone loss in this group.

We found a slight decrease in palatal alveolar bone thickness at the crestal (3mm) and mid-root (6mm) levels in the miniscrew group (Group II). Significantly greater changes were observed in the miniscrew group than in the intrusion-arch group; mean difference in Group I is 0.21 and Group II is 1.6 in PBT3 and 0.3 and -0.02 in PBT6 depicting greater decrease in PBT3 in Group II and PBT6 in group I. Sun *et al.* [17] stated decrease of ABH was found on the palatal side of maxilla and both sides of mandible, especially the lingual side. Gudomporn *et al.* [18] evaluated changes in maxillary alveolar bone thickness after maxillary incisor extrusion and proclination and found significant variation in palatal and total alveolar bone thicknesses at the mid root and apical root levels.

Negative correlation was found between the pre and post treatment readings of intrusion with Group II in TBT crestal (3mm) however significant changes were observed in TBT mid root (6mm); mean difference in group I is 0.65 and group II is 0.73. Atik [6] stated that total alveolar bone thickness did not change, but was maintained in both treatment groups which suggests that the rate of labial alveolar bone resorption was significantly higher than the rate of apposition on the lingual aspect in the miniscrew group, which may lead to a decrease in the LBT at the crestal level. Kaied and Tanielian [19] demonstrated significant decreases in alveolar bone thickness following incisor intrusion using segmented mechanics and utility arches.

In the present study, the intrusion-arch group did show a significant decrease in alveolar bone thickness however the results of miniscrews demonstrated more decrease in alveolar bone thickness. The differences may arise from the different type of biomechanics used, different force magnitudes, and individual response differences in terms of the bone remodeling rate.

## Conclusion

Considering our findings, it would be favorable to assess the necessary bone morphology prior to orthodontic treatment. Careful analysis of the bone structure around upper incisors, in deep-bite patients, could be considered as an important step before planning the treatment protocol. The current study showed that the decrease in bone thickness and bone height post intrusion were significantly greater in the miniscrew group than in the intrusion-arch group. This suggests that conventional intrusion mechanics, such as an intrusion utility arch or base-arch in which cinching-back of the arch-wire can be incorporated or miniscrew-assisted intrusion, should be considered. Therefore, from a clinical perspective, the clinician should take in consideration the individual's biological characteristics before choosing the type of the biomechanics used during the orthodontic treatment.

## References

- Bhateja NK, Fida M, Shaikh A. Deep Bite Malocclusion: Exploration of The Skeletal and Dental Factors. *Journal of Ayub Med Coll.* 2016;28(3):449-54.
- Daokar S, Agrawal G. Deep Bite Its Etiology, Diagnosis and Management: A Review. *J Orthod Endod.* 2016;2(4):1-4.
- Ozsoy PO, Ozcirpici AA, Veziroglu F. Miniscrews for upper incisor intrusion. *Eur J Orthod.* 2009;31(4):412-16.
- Aydogdu E, Ozsoy OP. Effects of mandibular incisor intrusion obtained using a conventional utility arch vs bone anchorage. *Angle Orthod.* 2011;81(5):767-75.
- Ozsoy OP, Ozcirpici AA, Veziroglu F, Cetinsahin A. Comparison of the intrusive effects of miniscrews and utility arches. *Am J Orthod Dentofac Orthop.* 2011;139(4):526-32.
- Atik E, Coskuner GH, Guven AB, Taner T. Evaluation of changes in the maxillary alveolar bone after incisor intrusion. *Kor J Orthod.* 2018;48(6):367-76.
- Lund H, Grondahl K, Grondahl HG. Cone beam computed tomography evaluations of marginal alveolar bone before and after orthodontic treatment combined with premolar extractions. *Eur J Oral Sci.* 2012;120(3):201-11.
- Sun Z, Smith T, Kortam S, Kim DG, Tee BC, Fields H. Effect of bone thickness on alveolar bone-height measurements from cone-beam computed tomography images. *Am J Orthod Dentofacial Orthop.* 2011;139(3):e117-e27.
- Sadowsky C, Schneider B. The effectiveness and long-term stability of overbite correction with incisor intrusion mechanics. *Am J Orthod Dentofacial Orthop.* 2005;127(1):47-55.
- Jain RK, Kumar SP, Manjula WS. Comparison of Intrusion Effects on Maxillary Incisors among Mini Implant Anchorage, J-Hook Headgear and Utility Arch. *Journal of Clinical and Diagnostic Research.* 2014;8(7):ZC21-24.
- Davidovitch M, Rebellato J. Two-Couple Orthodontic Appliance Systems Utility Arches: A Two-Couple Intrusion Arch. *Seminars in Orthodontics.* 1995;1(1):25-30.
- Melsen B, Agerbaek N, Markenstam G. Intrusion of incisors in adult patients with marginal bone loss. *Am J Orthod Dentofac Orthop.* 1989;96(3):232-41.
- Yodthong N, Charoemratrote C, Leethanaku C. Factors related to alveolar bone thickness during upper incisor retraction. *Angle Orthod.* 2013;83(3):394-01.
- Tian YL, Liu F, Sun HJ, Lv Pet, Cao YM, *et al.* Alveolar bone thickness around maxillary central incisors of different inclination assessed with cone-beam computed tomography. *Kor J Orthod.* 2015;45(5):245-52.
- Son EJ. A study on the morphologic change of palatal alveolar bone shape after intrusion and retraction of maxillary incisors. *Scientific Reports.* 2020;10(1):144-54.
- Bae SM, Kim HJ, Kyung HM. Long-term changes of the anterior palatal alveolar bone after treatment with bialveolar protrusion, evaluated with computed tomography. *Am J Orthod Dentofacial Orthop.* 2018;153(1):108-17.
- Sun Q, Lu W, Zhang Y, Peng L, Chen S Han. Morphological changes of the anterior alveolar bone due to retraction of anterior teeth: a retrospective study. *Head & Face Medicine.* 2021;17(1):2-12.
- Thongudomporn U, Charoemratrote C, Jearapongpakorn S. Changes of anterior maxillary alveolar bone thickness following incisor proclination and extrusion. *Angle Orthod.* 2015;85(4):549-54.
- Kaied IB, Tanielian RH. Comparative radiographic evaluation of the alveolar bone support changes after incisal intrusion. *Orthodontics (Chig.).* 2012;13(3):60-71.