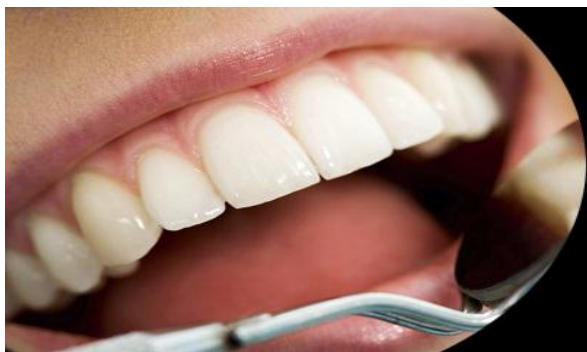



ISSN Print: 2394-7489
ISSN Online: 2394-7497
IJADS 2022; 8(2): 451-454
© 2022 IJADS
www.oraljournal.com
Received: 09-01-2022
Accepted: 16-02-2022

Dr. Nikhil Mahajan
Department of Orthodontics and
Dentofacial Orthopedics, ITS
Dental College and Research
Institute, Uttar Pradesh, India

Dr. Amrita Puri
Department of Orthodontics and
Dentofacial Orthopedics, ITS
Dental College and Research
Institute, Uttar Pradesh, India

Dr. Anshul Singla
Professor and Head, Department
of Orthodontics and Dentofacial
Orthopedics, ITS Dental College
and Research Institute, Uttar
Pradesh, India

Dr. Devansh Kumar
Senior Lecturer, Department of
Orthodontics and Dentofacial
Orthopedics, ITS Dental College
and Research Institute, Uttar
Pradesh, India

Dr. Shruti Sharma
Senior Lecturer, Department of
Orthodontics and Dentofacial
Orthopedics, ITS Dental College
and Research Institute, Uttar
Pradesh, India

Dr. Srishti Sureka
Post Graduate, Department of
Orthodontics and Dentofacial
Orthopedics, ITS Dental College
and Research Institute, Uttar
Pradesh, India

Dr. Mathew Koshy Vaidyan
Post Graduate, Department of
Orthodontics and Dentofacial
Orthopedics, ITS Dental College
and Research Institute, Uttar
Pradesh, India

Corresponding Author:
Dr. Nikhil Mahajan
Department of Orthodontics and
Dentofacial Orthopedics, ITS
Dental College and Research
Institute, Uttar Pradesh, India

Nasoalveolar molding: A review

Dr. Nikhil Mahajan, Dr. Amrita Puri, Dr. Anshul Singla, Dr. Devansh Kumar, Dr. Shruti Sharma, Dr. Srishti Sureka and Dr. Mathew Koshy Vaidyan

DOI: <https://doi.org/10.22271/oral.2022.v8.i2g.1541>

Abstract

Nasoalveolar molding represents a paradigm shift from the traditional presurgical orthopedics in cleft lip and palate patients which has been applied increasingly in the past two decades. Nasoalveolar moulding (NAM) is a nonsurgical way to reshape and align the gingiva, lip and nostrils to reduce the severity of the cleft before the conventional cleft lip and palate surgery. It requires an interdisciplinary approach for achieving the best results. This article is a review of recent literature apropos of objectives, technique, appliance design and adjustments and complications of this technique.

Keywords: Nasoalveolar molding, presurgical orthopedics, interdisciplinary treatment

Introduction

Presurgical infant orthopaedics has been used as a part of the treatment protocol of cleft lip and palate patients for centuries altogether ^[1].

Orofacial clefts, which are inclusive of cleft lip, cleft lip and palate, and cleft palate alone, comprise a range of disorders affecting the lips, gingiva and oral cavity, the causes of which remain largely unknown ^[2]. Multiple effects on speech, hearing, appearance, and cognition may lead to long-lasting adverse outcomes for health and social integration ^[3]. Affected children quite often need multidisciplinary care from birth until adulthood and they also have higher morbidity and mortality throughout their life as compared to unaffected individuals.

Nasoalveolar moulding (NAM) is a nonsurgical way to reshape and align the gingiva, lip and nostrils to reduce the severity of the cleft before the conventional cleft lip and palate surgery.

The objective of the presurgical NAM is to reduce the severity of the original cleft deformity and thereby enable the surgeon to achieve better repair of the alveolus, lip and nose ^[4]. Use of the NAM technique has also eliminated surgical columella reconstruction and the resultant scar tissue in bilateral cleft lip and palate ^[5].

The nasoalveolar moulding technique has been shown to significantly improve the surgical outcome of the primary repair in cleft lip and palate patients compared to other techniques of presurgical orthopaedics ^[4].

Principle of NAM

PNAM works on the principle of “Negative sculpturing” and “Passive molding” of the alveolus and adjacent soft tissues. In passive molding, custom made molding plate of acrylic is used gently to direct the growth of the alveolus to get the desired result later on. While in negative sculpturing serial modifications are made to the internal surfaces of the molding appliance with addition or deletion of material in certain areas to get desired shape of the alveolus and nose ^[7].

Objectives

- Decrease the severity of the primary cleft and provide symmetry to distorted nasal cartilage.
- Nonsurgical lengthening of the columella.
- Approximation of lip segments to decrease tension in the tissues after lip repair and

- reduce scarring.
- To produce additional favourable bone formation by decreasing the size of the cleft and improving nasal tip projection, decreasing the width of nasal alar base and nasal tip.
- Reduce the need for secondary alveolar bone grafts.
- In infants with bilateral CLP, the goal consists of the nonsurgical lengthening of the columella, retraction of premaxilla gently to accomplish continuity with the posterior alveolar cleft segments and centering of the premaxilla along the mid-sagittal plane^[8,9].

Appliance design

Constituent Parts of Nasal Stent

The nasal stent armature is most commonly bent with 0.036-in (0.8-mm) stainless steel wire in a shape resembling a swan's neck. The nasal stent can be divided into the following essential parts or segments (figure-1), each of which has a specific purpose:

- a. Anchorage (embedded) portion
- b. Base of the neck
- c. Upper neck portion
- d. Nasal bulb with upper and lower lobes

The kidney bean-shaped nasal bulb has 2 parts: a relatively larger upper lobe that lies beneath the alar dome and a lower lobe that lies just beneath the nostril rim. Incremental addition of soft denture reline material to the upper lobe and controlled activation of the upper neck portion of the nasal stent support and gently mold the collapsed alar dome, which is clinically reflected by its mild tissue blanching.

With progressive additions of soft reline to the upper lobe during the course of nasal molding, it will become larger than the lower lobe.

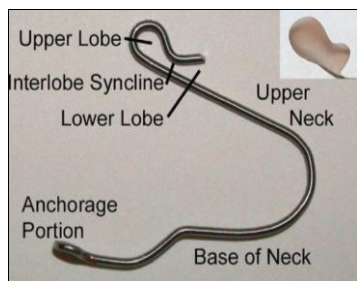


Fig 1: Parts of a Nasal Stent

Technique

The standard technique for the construction of the NAM appliance is done using a heavy-bodied impression material which is used to take the initial impression as soon after birth as possible (figure-2).

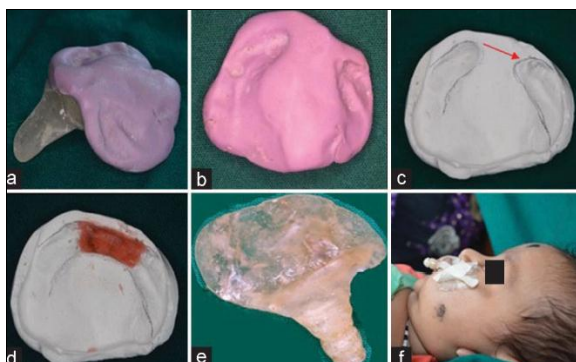


Fig 2: Impression taking in NAM

The infant is held upside down by the surgeon when the impression tray is inserted into the oral cavity. The infant is kept in the inverted position to keep the tongue forward and to allow fluids to drain out of the oral cavity (figure 2).

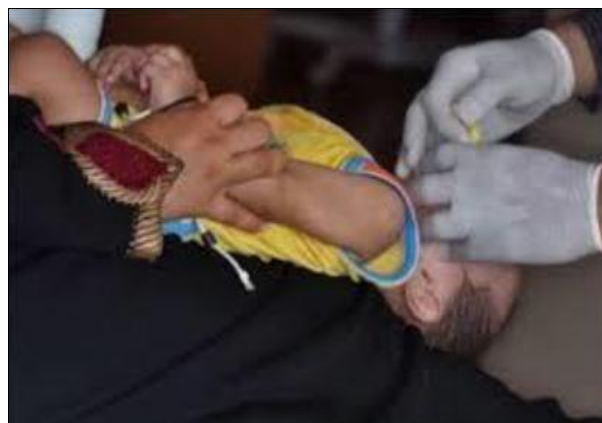

Fig 3: Position of the infant while taking an impression

The molding plate is fabricated on a dental stone model. It is made of a hard clear acrylic and lined with a thin coat of soft denture material.

A 5-mm diameter hole is made in the center of the acrylic palatal vault to provide an airway in the event that the posterior border of the plate drops down onto the tongue. Parents are instructed to ensure full time wear, and to take it out for cleaning as needed, at least once a day. The appliance is secured extra orally to the cheeks, bilaterally by surgical tapes (figure-4), which have an orthodontic elastic band at one end.

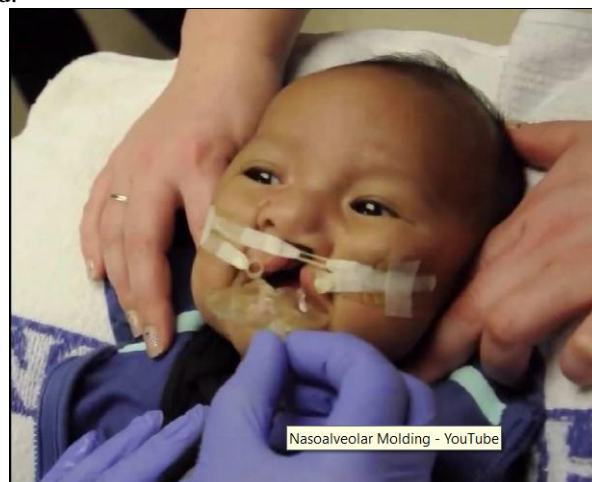

Fig 4: Appliance secured inside the oral cavity

The retention arm is positioned approximately 40° down from the horizontal plane to achieve proper activation and to avoid unseating of the appliance from the palate. The tapes and elastics are changed once a day.

Weekly visits are required to modify the molding plate in order to guide the alveolar cleft segments into the desired position. Closure of the alveolar gap brings the lip segments together, reduces the nasal base width and introduces laxity of the alar rim.

Only one retention arm is attached to the appliance for treatment of the unilateral cleft patient. To determine its location on the labial border of the molding plate, the cleft lip segments are pulled together while centering the philtrum and columella. The vertical position of the retention arm should be at the junction of upper and lower lips at rest. This will allow for approximation of the cleft lip segments and will not interfere with the resting position of the lower lip.

When the retention arms are engaged by the tape elastic system, the

elastics (inner diameter 1/4 in, wall thickness: heavy) should be stretched approximately two times the resting diameter for proper activation force (2 oz). The amount of force may vary depending on the clinical objective and the mucosal tolerance to ulceration. Retraction of the premaxilla will require greater elastic traction force than is required for closure of a unilateral alveolar gap.

Lip taping provides some of the benefits of a surgical lip adhesion without the associated surgical morbidity, hospital admission, cost and scarring. When the cleft alveolar gap is reduced to 5mm or less, the nasal stent is added. The stent is made of .036 gauge round stainless steel wire and takes the shape of a swan neck. In a patient with bilateral clefts, there is a need for two retention arms and nasal stents. (Figure 5)

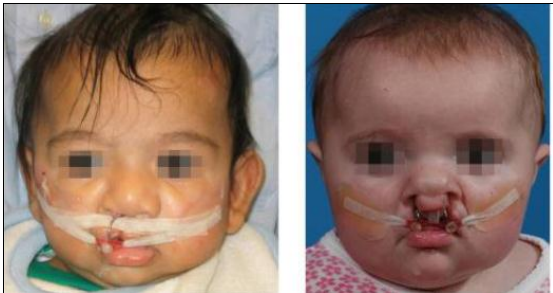

Fig 5: Intraoral stents in place

The intranasal portion consists of a hard acrylic component which is shaped into a bi-lobed form resembling a kidney. A layer of soft denture liner is added to the hard acrylic for comfort. The upper lobe enters the nose and gently lifts the dome until a moderate amount of tissue blanching is evident. The lower lobe of the nasal stent lifts the nostril apex and defines the top of the columella.

After the nasal stents are added, attention is focused on nonsurgical lengthening of the columella. To achieve this objective a horizontal band of soft denture material is added to join the left and right lower lobes of the nasal stents, spanning the base of the columella.

Tape is adhered to the prolabium, underneath the horizontal lip tape, and stretches downward to engage the retention arms with elastics. This vertical pull acts as a counter-stretch to the upward force applied to the nasal tip by the nasal stent.

Taping downward on the prolabium helps to lengthen the columella and vertically lengthens the often-small prolabium. The horizontal lip tape is added after the vertical prolabial tape is in place. Primary surgical closure of the lip and nose is performed from 3 to 5 months of age.

Appliance Adjustment

The infant is seen weekly to make adjustments to the moulding plate to bring the alveolar segments together. These adjustments are made by selectively removing the hard acrylic (figure-6) and adding the soft denture base material to the moulding plate (figure-7,8). No more than 1 mm of modification of the moulding plate should be made at one visit.



Fig 6: Removing hard palate on the palatal side to retract the premaxilla

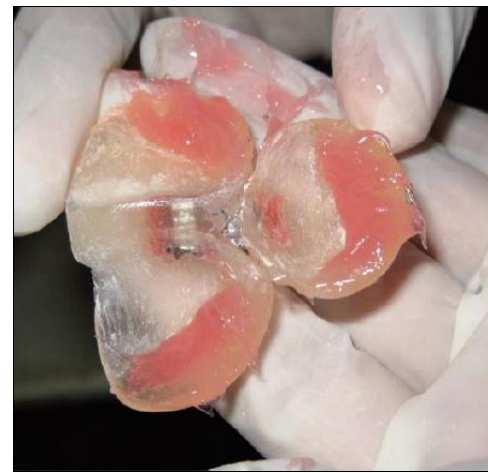


Fig 7: NAM plate during and post relining respectively



Fig 8: NAM plate during and post relining respectively

The alveolar segments should be directed to its final and optimal position. Care must be taken to prevent the soft denture material from building up on the height of the alveolar crest as this will prevent complete seating of the moulding plate.

Instructions for the parents

- Parents should be motivated & educated properly.
- They should be instructed to keep the plate in full time, and to take it out for cleaning as needed, at least once a day.
- Tapes and elastics are changed once a day.
- Ask to apply infant cream over cheeks while changing tapes.
- They are asked to examine the child's mouth daily for any ulceration.

Complications

Complications associated with NAM therapy may increase treatment time and could compromise the final aesthetic treatment outcome. Based on clinical experience, practice, and an intense review of the current literature, three main categories of complications associated with NAM therapy have been described: soft tissue, hard tissue, and compliance related.

Soft Tissue Complications

Intraoral soft tissue complications involve mucosal ulceration, bleeding, tissue fungal infections, and tissue irritation. Ulcerations may be caused by uneven flanges or under relieved areas on the intaglio surface of the moulding plate. Ulceration also may occur as a result of excessive activation of the internal surface of the appliance, resulting in the

impingement of the maxillary mucosa. In the bilateral molding plate, the hard acrylic on the internal palatal surface should not extend into the nasal cavity, so as to prevent nasal septum irritation.

If the molding plate is not removed daily and cleaned regularly, a candidal infection may result. Fungal infestation is treated with Nystatin or Amphotericin ointment. NAM therapy may be further complicated when extraoral surgical tape is used to align alveolar segments and approximate the lip segments.

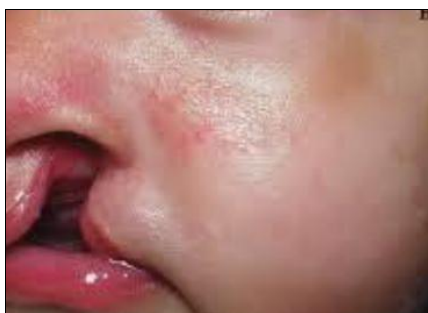
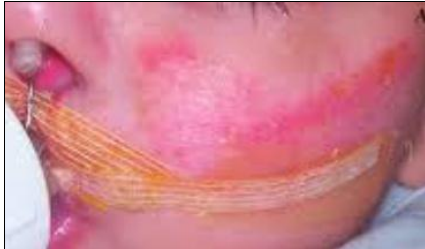
Fig 9: Contact dermatitis

This tape tends to irritate facial epidermal tissues, especially in the zygomatic process areas. Parents/caregivers must remove the appliance once or twice a day for proper hygiene.

Hard Tissue Complications

During the process of modifying the internal surface of the appliance to approximate the alveolar greater and lesser segments, the lesser segment might rotate excessively so as to approach the major segment in a perpendicular manner, resulting in an asymmetric T-shaped configuration. Care must be taken by the clinician to properly modify and monitor segment movements in order to avoid this problem.

An additional complication of the hard tissues involves the premature eruption of primary maxillary incisors through overlying gingival tissue as a result of the pressure exerted by the molding plate (Figure 10).

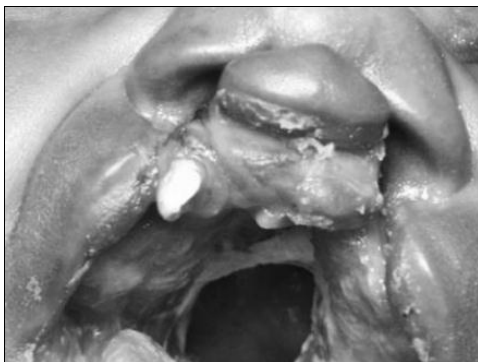

Fig 10: Premature eruption of primary maxillary incisors due to the pressure exerted by the molding plate in a patient with bilateral cleft lip and palate.

Compliance Complications

As with any orthodontic treatment, broken appointments often result in prolonged treatment or compromised final outcomes and may result in additional surgeries (Yang *et al.*, 2003; Pai *et al.*, 2005).

Parents have the primary responsibility for maintaining proper positioning and activation of the appliance and for ensuring that it is adequately cleaned. In addition to caregiver/parent compliance, patient behaviour is critical to the success of NAM. As the infant's neuromuscular system matures during the months of presurgical orthopedic treatment, the child becomes more prone to appliance removal by his/her hands or tongue. Arm restraints can be used to prevent the patient's limb movements toward the mouth (figure 10).

Conclusion

Management of the Cleft lip and palate is one of the greatest challenges for an orthodontist. Success of the NAM treatment depends upon the parent cooperation, age of the infant, proper diagnosis, extent of the cleft, operator expertise and appropriate interdisciplinary treatment approach. All these parameters play an important role when managing cleft lip and palate patients to achieve a better approximation of the 2 segments of the arch before any further surgical intervention.

References

1. Grayson BH, Shetye PR. Presurgical nasoalveolar moulding treatment in cleft lip and palate patients. *Indian Journal of Plastic Surgery*. 2009 Oct;42(S 01):S56-61.
2. Shkoukani MA, Chen M, Vong A. Cleft lip: A comprehensive review. *Frontiers in pediatrics*. 2013 Dec; 27(1):53.
3. Mossey PA, Little J, Munger RG, Dixon MJ, Shaw WC. Cleft lip and palate. *The Lancet*. 2009 Nov, 21;374(9703):1773-85.
4. Mobin SS, Karatsonyi A, Vidar EN, Gamer S, Groper J, Hammoudeh JA, Urata MM. Is presurgical nasoalveolar molding therapy more effective in unilateral or bilateral cleft lip–cleft palate patients. *Plastic and reconstructive surgery*. 2011 Mar, 1;127(3):1263-9.
5. Yang S, Stelnicki EJ, Lee MN. Use of nasoalveolar molding appliance to direct growth in newborn patient with complete unilateral cleft lip and palate. *Pediatr Dent*. 2003;25:253-6.
6. Grayson BH, Maull D. Nasoalveolar molding for infants born with clefts of the lip, alveolus, and palate. *Clin Plast Surg*. 2004;31:149-58.
7. Dubey RK, Gupta DK, Chandraker NK. Presurgical nasoalveolar molding: A technical note with case report. *Indian J Dent Res Rev*. 2011;2:66-8.
8. Retnakumari N, Divya S, Meenakumari S, Ajith PS. Nasoalveolar molding treatment in presurgical infant orthopedics in cleft lip and cleft palate patients. *Arch Med Health Sci*. 2014;29:36-47.
9. Grayson BH, Garfinkle JS. Early cleft management: The case for nasoalveolar molding. *Am J Orthod Dentofacial Orthop*. 2014;145:134-42.