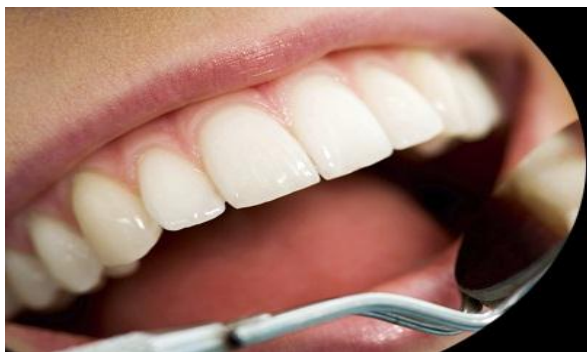



ISSN Print: 2394-7489
ISSN Online: 2394-7497
IJADS 2022; 8(2): 530-533
© 2022 IJADS
www.oraljournal.com
Received: 12-02-2022
Accepted: 19-03-2022

Dr. Drashti Gajre
Postgraduate Student,
Department of Orthodontics and
Dentofacial Orthopaedics
Pacific Dental College &
Hospital, Udaipur, Rajasthan,
India

Dr. Kamlesh Garg
Professor and Head, Department
of Orthodontics and Dentofacial
Orthopaedics, Pacific Dental
College & Hospital, Udaipur,
Rajasthan, India

Dr. Bhavesh Kothari
Professor, Department of
Orthodontics and Dentofacial
Orthopaedics, Pacific Dental
College & Hospital, Udaipur,
Rajasthan, India

Dr. Sagrika Grover
Postgraduate Student,
Department of Public Health
Dentistry, Pacific Dental College
& Hospital, Udaipur, Rajasthan,
India

Dr. Divya Bhagat
Postgraduate Student,
Department of Conservative
Dentistry and Endodontics
Pacific Dental College &
Hospital, Udaipur, Rajasthan,
India

Corresponding Author:
Dr. Kamlesh Garg
Professor and Head, Department
of Orthodontics and Dentofacial
Orthopaedics, Pacific Dental
College & Hospital Udaipur,
Rajasthan, India

Orthodontic management in an adult patient with a class II division 1 malocclusion using T-loop: A case report

Dr. Drashti Gajre, Dr. Kamlesh Garg, Dr. Bhavesh Kothari, Dr. Sagrika Grover and Dr. Divya Bhagat

DOI: <https://doi.org/10.22271/oral.2022.v8.i2h.1552>

Abstract

The most common type of malocclusion encountered in India is a Class II div I malocclusion. They are distinguished by a mild to severe Class II skeletal base with an Angle's Class II molar relation and Class II canine and incisor relations, proclined maxillary incisors, and an increased overjet, as well as a convex profile with incompetent lips. For the treatment of Class II div I malocclusion, various treatment modalities have been presented. This case study features a 15-year-old female with a Class II division 1 malocclusion, an orthognathic maxilla, and an 8mm overjet. Treatment goals included achieving functionally optimal and aesthetically acceptable occlusion, eliminating dental arch crowding, reducing overjet, and achieving competency of lips and a balanced soft tissue profile. The treatment plan called for extraction of the upper first and lower second premolars, followed by space closure with a T-loop. Following treatment, a satisfactory result was obtained with an ideal, static, and functional occlusion, facial profile, smile and lip competence, and treatment result stability.

Keywords: Angle's Class II, malocclusion, T-loop, overjet, extraction

Introduction

In India, Class II div 1 malocclusion is more common than any other type of malocclusion after Class I malocclusion [1]. Class II malocclusion affects approximately 42 percent of all patients, while Class II subdivision dental relationships affect approximately 50 percent [2]. Class II malocclusions can be caused by a more anterior maxillary bone relationship, a more posterior position of the mandibular base, or a combination of the two. In fact, the basal bone discrepancy and the dentoalveolar anomaly can coexist in the same person [3]. Class II malocclusions can be treated in a variety of ways, depending on the problem characteristics, such as anteroposterior discrepancy, age, and patient compliance [4]. Extraoral appliances, functional appliances, and fixed appliances associated with Class II intermaxillary elastics are examples of methods. Historically, the indications for extractions in orthodontic practice have been contentious [5]. For a variety of reasons, different authors have recommended variations in extraction sequences that include upper and lower first or second premolars. Extractions for Class II malocclusion correction in non-growing patients can involve two maxillary premolars or two maxillary and two mandibular premolars [6]. After extraction, the space can be closed by anterior retraction with group A anchorage, posterior protraction with group C anchorage, or a combination of both with group B anchorage. Two types of mechanics are used in the space closure stage of orthodontic tooth movement. The first is sliding mechanics, and the second is loop mechanics. The T-loop has been proposed as a mechanism for controlling anchorage movement during extraction space closure; the T-loop works by creating differential moments between the anterior and posterior segments. This case report describes the treatment of an adult with Class II div 1 malocclusion with increased overjet and deep bite using the universal T-loop technique, which resulted in successful space closure [7].

Case Report

A 15-year-old female patient presented to the Department of Orthodontics and Dentofacial Orthopaedics complaining of forwardly placed teeth in the upper front region of the jaw.

Clinical Examination

The patient's extraoral features revealed a convex profile and incompetent lips. There were no temporomandibular signs or symptoms detected or reported (Fig. 1). Intraoral features revealed that the patient's maxillary and mandibular anterior teeth were proclined. The overjet measured 8mm, and the overbite measured 3mm.

The molar and canine relationships, as well as the Class II div 1 incisor relationship, were discovered to be end-on bilaterally. The maxillary and mandibular arches were in shape, with mild crowding in the maxillary arch and moderate crowding in the mandibular arch. The dental midlines were aligned (Fig.2). The alveolar bone level was normal, with

impacted third molars in all four quadrants, according to a panoramic radiograph. All teeth had completed root formation. All the teeth appeared to be free of caries, with no pathological lesions visible (Fig.3).

With $SNA = 82^\circ$ and $SNB = 81^\circ$, cephalometric interpretations suggested a normal maxilla and mandible. An ANB of 1° indicated that the patient's skeletal pattern was Class I. He had an acute gonial angle and a horizontal growth pattern, with $GoGn-Sn = 24^\circ$ and $FMA = 20^\circ$ values. The maxillary central incisors were proclined and forwardly positioned, with a $UI-NA$ linear of 14mm and an angular angle of 55° . The mandibular incisors were also proclined and retropositioned, with $LI - NB$ linear -5mm, angular 25° , and $IMPA$ of 98° . In soft tissue, the upper lip - S line was 0mm, indicating a protruding upper lip, while the lower lip - S line was 0mm, indicating a protruding lower lip. The nasolabial angle was measured at 97° . (Fig.3).



Fig 1: Photographs of extra oral pretreatment

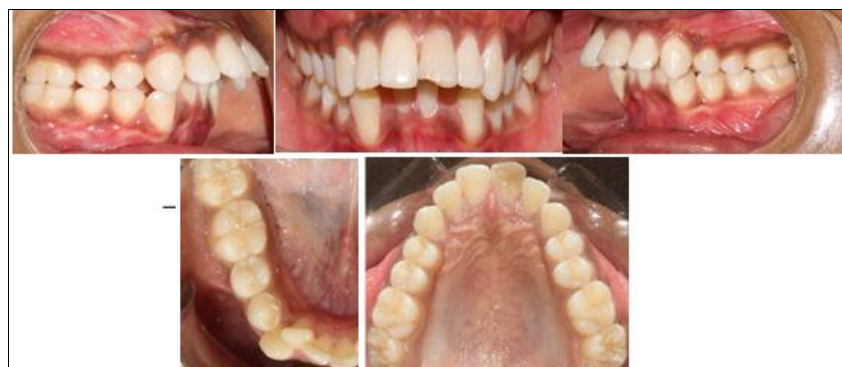

Fig 2: Photographs of Intraoral Pretreatment

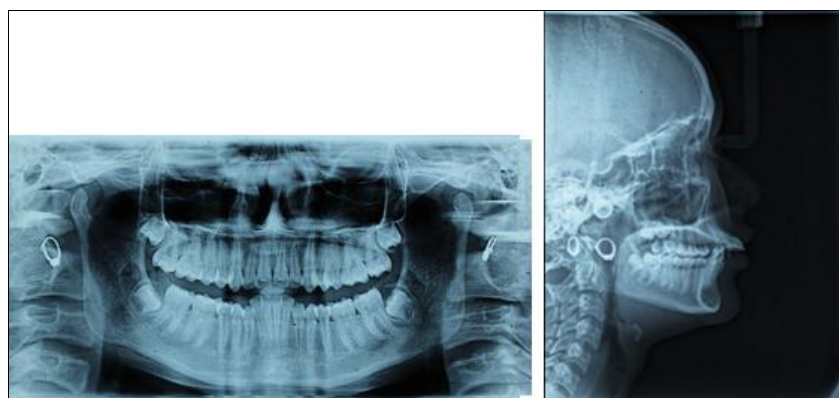


Fig 3: Pre treatment radiographs

Objectives

1. To achieve a functionally optimal and aesthetically pleasing occlusion
2. Accept the Skeletal Class II pattern.
3. Eliminate dental crowding from both the maxillary and mandibular arches.

4. Increased overjet correction.
5. Alignment and coordination of the dental arches.
6. Correction of upper and lower incisor inclination and interincisal angle.
7. Achieve lip competency and a balanced soft tissue profile.
8. Maintain achieved results.

Treatment Progress

Upper 4 and lower 5 extraction treatment plans were developed after careful consideration of all aspects of the case, beginning with fixed mechanotherapy in the upper and lower arches (Standard edge wise MBT 0.018" slot bracket). The first step was bonding and band cementation in the upper arch, which was followed by extraction of the upper right first and lower right second premolars. Bonding was performed in the lower arch, followed by extraction of the upper left first premolar and lower left second premolar.

Alignment and leveling was carried out with 0.012, 0.014, 0.016, 0.018 NiTi for four months. 0.016 SS wire was placed in upper arch for crossbite correction and cross elastics (3.05 Oz) were given for upper second and lower first premolars on both sides. A T-loop canine retractor was used to perform mass retractions of the six anterior teeth. (TMA-19x25 SS) (Fig.4). As the camouflage treatment with 2 premolar extractions requires anchorage conservation and to reinforce our anchorage, with TPA in upper arch. In lower arch 0.018 SS with reverse curve of speed was given. A step wise activation of T-loop 1-2 mm was done every month to close the extracted tooth space. For lower arch space closure was carried out by 19x25 SS wire with boot hooks. After the closure of the premolar extraction space, the extraction site was stabilized with a figure of eight ligation between the molars. A 0.016 nickel titanium arch wire was placed to level the arch and for the occlusal settling.

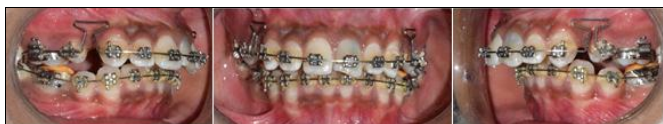

Fig 4: Retraction of upper anterior segment using T-Loop.

Results

With functionally acceptable occlusion, the patient's aesthetic was improved. Crowding in both the upper and lower dental arches was addressed. The patient's overjet and overbite were also corrected. Both the upper and lower dental arches were correctly aligned. The anterior teeth were successfully retracted, and the results were stable. The patient was pleased and satisfied with the outcome. (Fig. 5.)

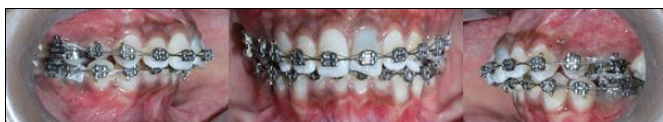

Fig 5: Occlusal settling on 0.014 Niti wire

Discussion

The goal of treatment is to correct the occlusion by orthodontically repositioning the teeth in the jaws so that the dental occlusion is acceptable, and the facial appearance is pleasing. The treatment options for this patient included dislocating the teeth that were relative to their supporting bone. The movement of teeth, as in the retraction of a protruding tooth^[8].

Historically, the indications for extractions in orthodontic practice have been contentious. Because they are conveniently located between the anterior and posterior segments, premolars are probably the most extracted teeth for orthodontic purposes^[9]. Different authors have recommended different extraction sequences, which include the upper and lower first or second premolars, for a variety of reasons. The treatment of complete Class II malocclusions by extracting premolars necessitates the use of an anchorage to prevent posterior segment mesial movement during anterior tooth retraction^[10].

The next step was to close the space. One of the most difficult steps in orthodontic treatment is space closure. The orthodontist can establish anchorage and treatment options based on the biomechanical basis of space closure. For this case, a frictionless mechanic was chosen, and a T-loop was used. The T-loop has long been recognized as an effective spring for achieving controllable tooth movement between the anterior and posterior segments^[11]. The 0.019 x 0.025 T-loop is used to close space symmetrically. T loops have a higher M/F ratio and provide more constant force over a wider deactivation range than vertical loops^[12].

The orthodontist is limited in how high the loop can be made due to the depth of the vestibule. To solve this problem, a horizontal wire, such as a T-loop, can be added^[13]. Thus, in this case, T loop was used for space closure, and we were able to achieve full anterior retraction with minimal anchor loss by using a continuous T loop arch wire. Reduced proclination also leads to less lip protrusion, which improves the soft tissue profile^[14]. Because the patient's main reason for seeking treatment was for aesthetics, the patient was very pleased with the results. Thus, we were able to achieve structural balance, functional efficiency, and aesthetic harmony using this method.

Conclusion

Adults with Class II, division 1 malocclusions are always difficult to treat. If the incisor inclination and interincisal angle are ignored, relapse is quite common. The key to achieving predictable results with minimal side effects is to apply proper knowledge of biomechanical principles when executing the mechanics plan/protocol.

Wires, techniques for leveling-aligning, as well as T-loop reactivated-activated, and anchorage are required for appliance and assessment selections. These are critical for achieving the best possible outcome. It is suggested that an appropriate treatment plan be considered to make good progress. To achieve aesthetic and functional goals, the orthodontist and patient should agree on treatment options.

References

1. Hossain MZ, Haque S, Yasmin S, Haque A, Bahar R. Prevalence of malocclusion and treatment facilities at Dhaka Dental College and Hospital. *J Oral Health*. 1994;1(1):5-11.
2. Rose JM, Sadowsky C, BeGole EA, Moles R. Mandibular skeletal and dental asymmetry in Class II subdivision malocclusions. *American Journal of Orthodontics and Dentofacial Orthopaedics*. 1994 May 1;105(5):489-95.
3. Vitral RW, de Souza Telles C, Fraga MR, de Oliveira RS, Tanaka OM. Computed tomography evaluation of temporomandibular joint alterations in patients with class II division 1 subdivision malocclusions: condyle-fossa relationship. *American Journal of Orthodontics and*

- Dentofacial Orthopaedics. 2004 Jul 1;126(1):48-52.
4. Salzmann JA. Practice of orthodontics. Philadelphia: J. B. Lippincott Company; p. 701-24;1966.
 5. McNamara Jr JA. Components of Class II malocclusion in children 8–10 years of age. The Angle Orthodontist. 1981 Jul 4;51(3):177-202.
 6. Case CS. The question of extraction in orthodontia. American Journal of Orthodontics and Dentofacial Orthopaedics. 1964 Sep 1;50(9):660-91.
 7. Case CS. The extraction debate of 1911 by Case, Dewey, and Cryer. Discussion of Case: the question of extraction in orthodontia. American Journal of Orthodontics and Dentofacial Orthopaedics. 1964 Sep 5;90(1):900-58.
 8. Tweed CH. Indications for the extraction of teeth in orthodontic procedure. American Journal of Orthodontics and Dentofacial Orthopaedics. 1944 Aug 1;30(8):405-28.
 9. Staggers JA. A comparison of results of second molar and first premolar extraction treatment. American Journal of Orthodontics and Dentofacial Orthopaedics. 1990 Aug 5;90(1):555-67.
 10. Rajcich MM, Sadowsky C. Efficacy of intraarch mechanics using differential moments for achieving anchorage control in extraction cases. American Journal of Orthodontics and Dentofacial Orthopaedics. 1997 Oct 1;112(4):441-8.
 11. Nanda R. Biomechanics and Esthetic Strategies in Clinical Orthodontics, St. Louis: Elsevier Saunders; 2005.
 12. Burstone CJ. The segmented arch approach to space closure. American Journal of Orthodontics and Dentofacial Orthopaedics. 1982 Nov 1;82(5):361-78.
 13. Graber LW, Vanarsdall RL, Vig KW. Orthodontics Current Principles and Techniques, 4th ed. St. Louis: Elsevier Mosby. 2005.
 14. Siatkowski RE. Continuous arch wire closing loop design, optimization, and verification. Part I. American Journal of Orthodontics and Dentofacial Orthopaedics. 1997 Oct 1;112(4):393-402.