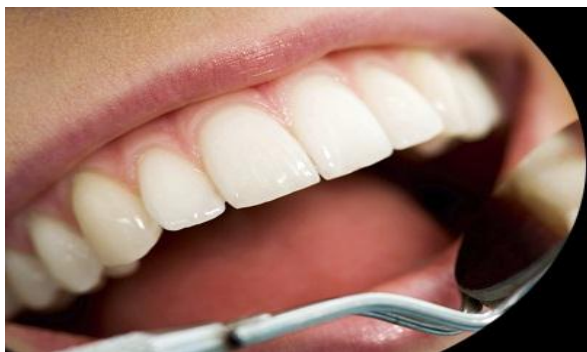



International Journal of Applied Dental Sciences

ISSN Print: 2394-7489
ISSN Online: 2394-7497
IJADS 2022; 8(2): 537-544
© 2022 IJADS
www.oraljournal.com
Received: 23-02-2022
Accepted: 28-03-2022

MDS Lizeth Alejandra Reyes Alvarado
Professor at the Universidad Autónoma de Coahuila, M.D.S. with emphasis in Periodontology, School of Dentistry, Torreon Unit, Coahuila, Mexico

DS Alma Viridiana Castro Quiñones
Universidad Autónoma de Coahuila, M.D.S. with emphasis in Periodontology, School of Dentistry, Torreon Unit, Coahuila, Mexico

MDS María de los Ángeles Pietschmann Santamaría
Professor at the Universidad Autónoma de Coahuila, M.D.S. with emphasis in Periodontology, School of Dentistry, Torreon Unit, Coahuila, Mexico

MDS Martha Margarita Aguado Arzola
Profesora at the Universidad Autónoma de Coahuila, M.D.S. with emphasis in Periodontology, School of Dentistry, Torreon Unit, Coahuila, Mexico

DBS Dora María López Trujillo
Professor at the Universidad Autónoma de Coahuila, M.D.S. with emphasis in Periodontology, School of Dentistry, Torreon Unit, Coahuila, Mexico

DS Julissa Ramírez Ramírez Student at the Universidad Autónoma de Coahuila, M.D.S. with emphasis in Periodontology, School of Dentistry, Torreon Unit, Coahuila, Mexico

Israel Abisai del Rio Balderrama
Student at the Universidad Autónoma de Coahuila, School of Dentistry, Torreon Unit, Coahuila, Mexico

Corresponding Author:
MDS Lizeth Alejandra Reyes Alvarado
Professor at the Universidad Autónoma de Coahuila, M.D.S. with emphasis in Periodontology, School of Dentistry, Torreon Unit, Coahuila, Mexico

Lip repositioning with crown lengthening as an alternative to excessive gingival exposure: Clinical case

MDS Lizeth Alejandra Reyes Alvarado, DS Alma Viridiana Castro Quiñones, MDS María de los Ángeles Pietschmann Santamaría, MDS Martha Margarita Aguado Arzola, DBS Dora María López Trujillo, DS Julissa Ramírez Ramírez and Israel Abisai del Rio Balderrama

DOI: <https://doi.org/10.22271/oral.2022.v8.i2h.1554>

Abstract

Introduction: excess gummy smile is frequent and appears as a manifestation of intraoral and extraoral etiological factors. Objective: to document the management of a gummy smile associated with lip hypermobility, altered passive eruption and exostoses.

Clinical case: 23-year-old female patient with excessive gummy smile. Treatment: surgical lip replacement technique combined with coronary lengthening.

Results: 7-month postoperative follow-up with minimal recurrence and the patient reported that she noticed a change in her profile and in the implantation of her nasal wings that was narrower than before surgery.

Conclusions: The technique restricts the traction of the levator lip muscle, the depth of the vestibule is shortened, reducing the amount of gingiva that is shown when smiling; the crown lengthening allows to increase the tooth length in the smile.

Keywords: Lip replacement, crown lengthening, gummy smile

Introduction

Smiling is an expression that denotes pleasure, joy, fun, happiness; smiling is something that everyone understands regardless of race, sex or religion and by smiling we express emotions that are understood around the world [1].

Smile harmony is determined by the shape, position, color and gingival tissues. The gingival margin must be healthy and harmonious to achieve an esthetic smile. The amount of exposed gingiva when smiling depends on the location of the smile line which is defined as the relationship between the upper lip and the visible teeth and gingival tissues. (Figure 1)

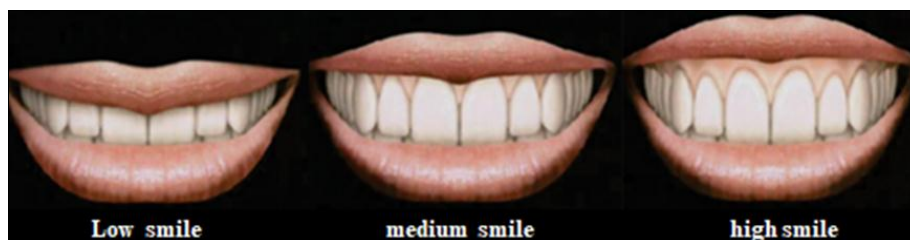

Fig 1: Freadeani, 2006

Britto in 2018 describes as a normal gingival smile between the lower lip border, the upper lip and the gingival margin of the maxillary central incisors of 1 to 2 mm in contrast with a distance greater than 4 mm between the gingival margin and the lip is considered an unattractive smile [2].

The lip line, assessed when the patient is in full smile, can be classified into: "smile line" classification upper-interdental lip and marginal gingiva.3 (Table 1).

Table 1: Smile line classification. Jensen J. Joss A. *et al.* [3]

Class	Type: description	Evaluation
0.	low smile line IDG: <25% visible	M: Not visible, masked teeth
1.	average/ideal smile line 3 individual teeth	IDG: 25-75% visible, M: Visible on
2.	high smile line IDG:>75% visible	M: <3mm visible (in general)
3.	very high smile line wide, gingival	IDG: Completely visible, M: >3mm

Maxillary band visible beyond the mucogingival line "gingival smile".
 IDG= interdental gingiva; M = Gingival margin

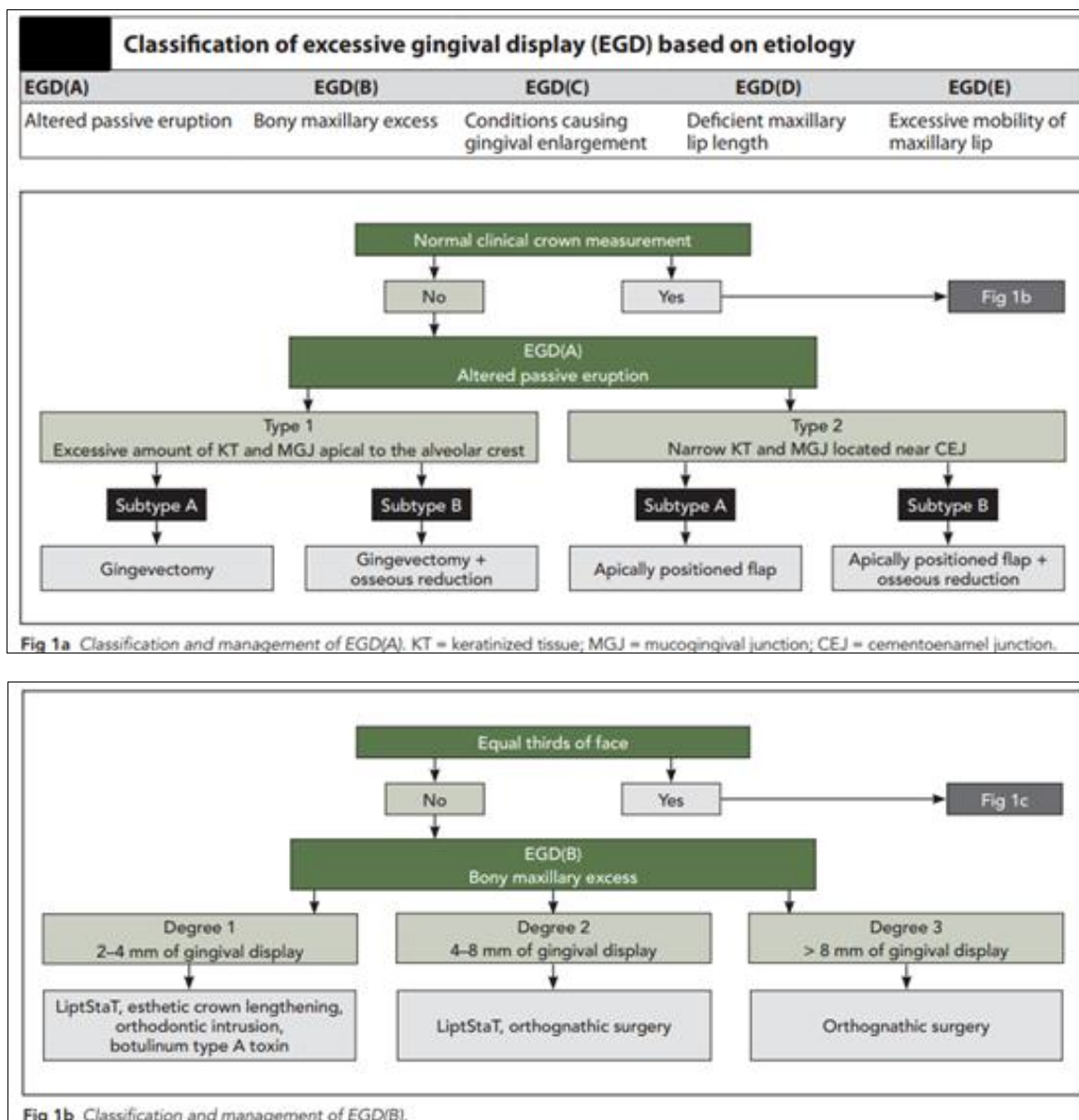
This condition affects 10.5% of the population between 20 and 30 years of age with a female predominance of 2:1 and decreases with age as a consequence of the loss of muscle tone in the upper and lower lip.

Monish Bholia in 2015 classifies the extraoral etiology of gummy smile into 3 groups: Acquired, hereditary or skeletal

in nature with possible intraoral factors altered passive eruption, maxillary excess, conditions causing gingival enlargement lip deficiency, excessive upper lip mobility.

In 2015 Monish Bola published a classification of the gummy smile based on etiology and added treatment of choice (Table 2).

Table 2: Monish Bola 2015



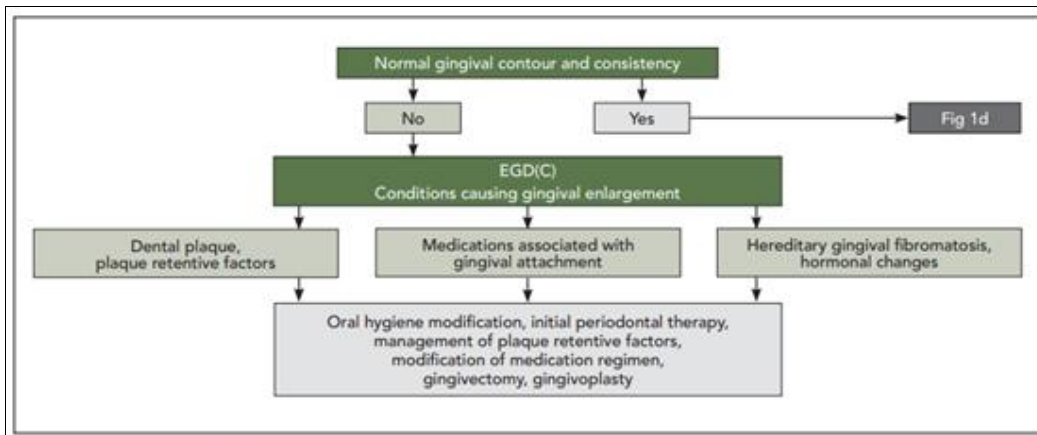


Fig 1c Classification and management of EGD(C).

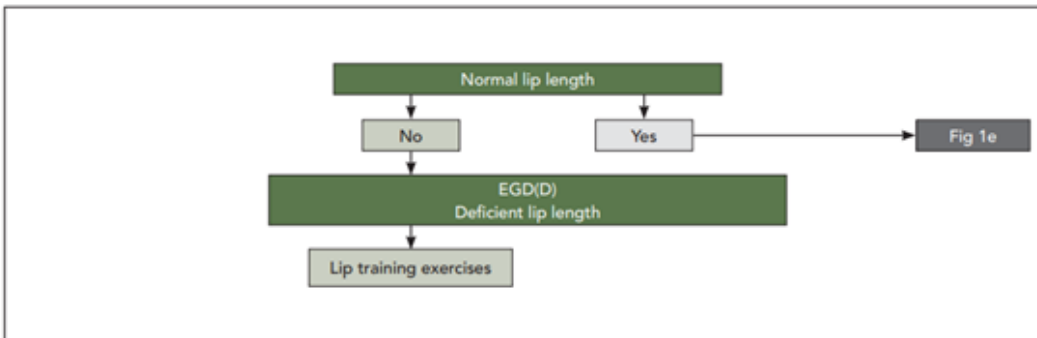


Fig 1d Classification and management of EGD(D).

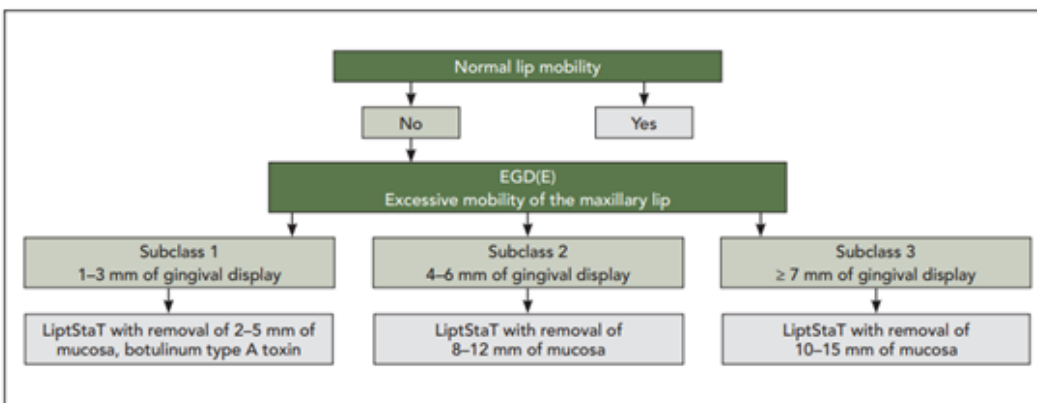


Fig 1e Classification and management of EGD(E).

A. If the clinical crown measurements are not normal, it is considered to have altered passive eruption.

Type 1: The patient has equal facial thirds with excessive keratinized gingiva and mucogingival attachment apical to the alveolar ridge, in this case if there is only gingival enlargement the patient enters subtype A as the treatment of choice will be gingivectomy, if there is mucogingival attachment apical to the alveolar ridge the patient will be a subtype B and it will be necessary to perform gingivectomy with osteotomy.

Type 2: Narrow keratinized gingiva close to the cemento-enamel junction. Subtype A will be sufficient with an apical repositioning technique, if it presents keratinized gingiva close to the cemento-enamel junction with bone crest level beyond the cemento-enamel junction the treatment will be apical repositioning technique with osteotomy.

B. The thirds of the face are not equal and it enters the classification in maxillary excess

Grade 1: Sample of 2 to 4 mm of gingival tissue. In this case lip repositioning, esthetic crown lengthening, orthodontic movements or botulinum toxin is indicated.

Grade 2: 4 to 8 mm sample of gingival tissue. Treatment will be lip repositioning or orthognathic surgery.

Grade 3: Exposure is greater than 8 mm. The indicated treatment is orthognathic surgery.

C. Abnormal gingival contour and consistency. The factor will be the conditions that cause gingival enlargement

1. Dental plaque, Plaque retentive factors.
2. Medications associated with gingival enlargement.
3. Hereditary gingival fibromatosis or caused by hormonal changes.

The treatment of choice is to eliminate the etiologic factor, plaque control, modification of oral hygiene, management of retentive factors, modification of medication regimen, gingivectomy and gingivoplasty.

D. Deficient length of the upper lip.

E. Normal lip height. Excessive upper lip mobility.

Subclass 1: Shows 1-3 mm of gingival tissue will require lip repositioning with 2 to 5 mm of mucosal removal and/or botulinum toxin.

Subclass 2: Sample 4-6 mm Lip repositioning with removal of 4 to 6 mm.

Subclass 3: Shows more than 7 mm lip repositioning with mucosal removal of 10 to 15 mm.

Lip mobility deficiency, it will be convenient for the patient to perform lip training movements [4].

Factors to be considered in an esthetic crown lengthening for the maxilla in anterior teeth:

Labial position, occlusal plane, dental alignment, texture, color, incisal edge, phenotype, gingival zenith and symmetry.

Crown lengthening is a resective surgical procedure that Sonick in 1997 classified as follows:

I. Only gingival reduction - bone remodeling not necessary

1. Gingivectomy
2. Gingival flap surgery

II. Mucoperiosteal flap with ostectomy-necessary bone removal

A) Single-stage procedures, which require one of the following

1. Flap, ostectomy, apical repositioning

2. Flap, ostectomy, gingivectomy, positioning
3. Gingivectomy, flap, ostectomy, positioning

B) A 2-phase procedure that requires the following:

- 1) Flap, ostectomy, repositioning, and 4-6 days later gingivectomy [5].

Materials and Methods

Case report

The 23 year old female patient went to the prosthodontist stating that she did not like her smile and was referred to the periodontics area. On taking a medical history, she had no history of systemic disease or drug addiction, so she was considered an ASA type 16 patient according to the American Association of Anesthesiologists and a healthy patient for dental management according to the Malamed classification [7]. In the intraoral analysis there are no caries or pathological gingival alterations. There is no mobility, fringing or crowding. Class 1 canine and molar occlusion is observed.

In the periodontal examination there is no probing greater than 2 mm, there is no evidence of bleeding areas or inflammation. When smiling the smile line exceeds the mucogingival junction, the dental proportion is observed short from the gingival margin to the incisal edge in relation to the mesiodistal measurement, based on the relationship documented by Sterret in 1999 [8]. (Figure 2) Figure 3 shows the initial periapical radiographs.

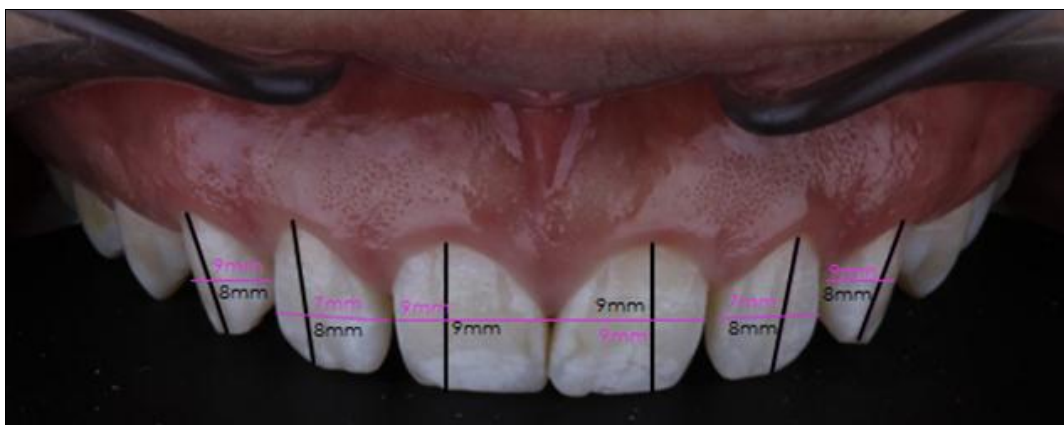

Fig 2: Shows wider mesiodistal ratio in relation to apicoronal length apicoronal length. (Own elaboration)

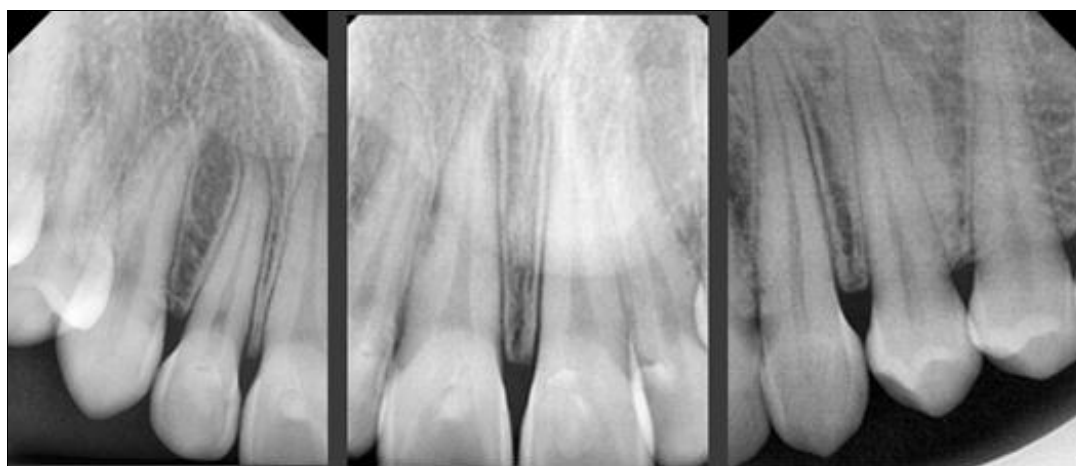


Fig 3: Initial periapical radiographs. (Own elaboration)

In the extraoral examination, when analyzing the facial thirds, the middle third is slightly larger than the middle and upper third. (Figure 4)




Fig 4: Division of the facial thirds, the lower third is slightly larger than the middle and upper third. (Own elaboration)

The data collected from the extraoral, intraoral and systemic clinical examination of the patient were entered into the periotoools online application where the information is processed and based on the study by Niklaus P. Langa and Maurizzion Tonnetti in 2003 [9]. The patient is at low periodontal risk. It is explained in the following polygonal graph.10 (Figure 5)

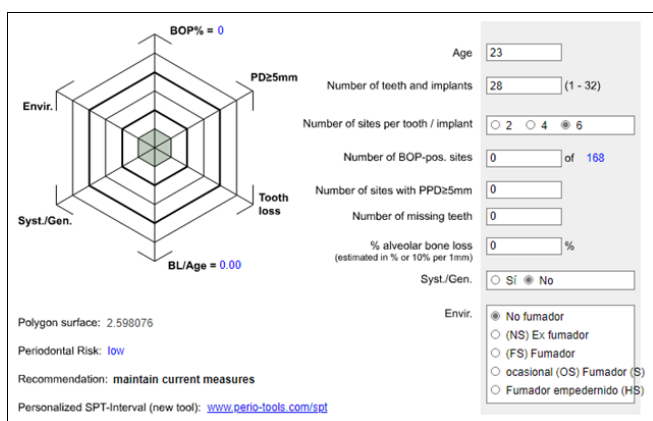


Fig 5

Diagnosis

According to the 2018 classification [1] the patient is considered a healthy patient with intact periodontium. Within the Monish Bola Gingival Smile diagnosis classification Gingival smile associated with altered passive eruption lip hypermobility and osseous exostosis [4].

Based on the clinical and diagnostic data, a comprehensive treatment plan is elaborated as listed below. In periodontics it is divided into 3 phases:

Phase I: Hygienic, consisting of plaque control, dental cleaning.

Phase II: Surgical which consists of performing: Esthetic crown lengthening, resective surgery of vestibular exostoses, surgical repositioning of upper lip.

Phase III: Periodontal maintenance consisting of prophylaxis and periodic plaque control.

Restorative dentistry: Tooth whitening and reconstruction of canine cusps with resin.

Procedure

Prior to the anesthesia, intraoral and extraoral disinfection

was performed, a sterile surgical field was placed on the face and neck of the patient and a 20% benzocaine topical anesthetic was placed with a swab on the maxillary mucosa, After a couple of minutes the regional anesthesia was performed by infiltrating 4 cartridges of articaine 4% with epinephrine 1% in the vestibular sac fundus of the canines, right and left incisor region, in the vestibular and palatine incisor papilla with a carpulle syringe and a disposable 0 gauge needle [27]. Once the nerve block had taken effect approximately 5 minutes after the infiltration, we proceeded to plan the coronary lengthening, starting with the gingivectomy, for which it was necessary to have the following instruments: examination kit, periodontal probe, Orban scalpel, scalpel handle, 15c scalpel blade and Goldman fox scissors, Prichard periosteal elevator and a ck6 curette.

With the help of the periodontal probe the tooth length was measured and the excess gingival tissue was marked with "bleeding points" (Figure 6), once marked with the help of the blunt end of the Prichard elevator these points were joined creating a guide line that was then incised with the #15 scalpel blade making an internal bevel cut. (Figure 7)

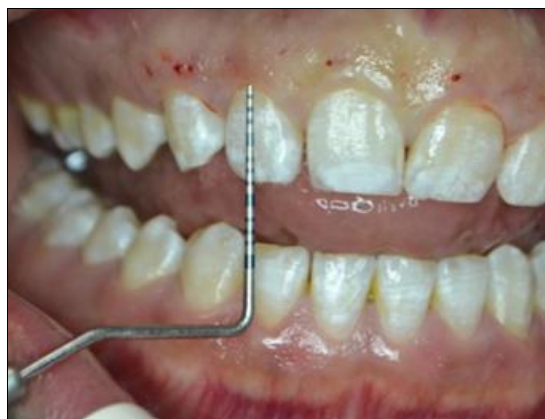

Fig 6: Delimitation of the cutout.

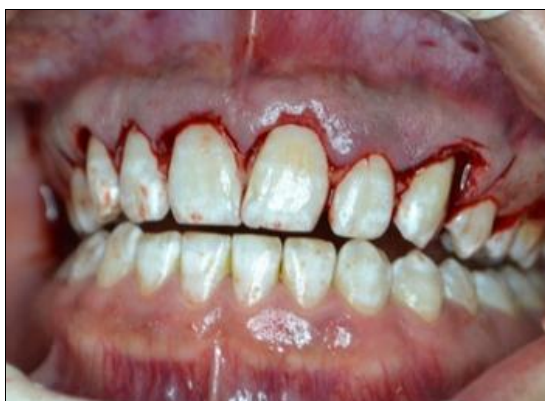

Fig 7: After gingivectomy. (Own elaboration)

With the help of the curette the excess tissue was removed and with the Goldman fox scissors and the Orban scalpel the excess tissue was completely removed in the areas that were difficult to access, for example in interproximal areas. Once the gingivectomy was completed, a full-thickness flap was elevated to remove the exostoses and delimit the 3 mm ridge to create an adequate biological thickness. A scalpel handle, a 15 c blade, a Prichard elevator, a bone file, a 13k reverse action chisel, a low-speed handpiece pine-shaped surgical bur, a 50 cc syringe for irrigation with saline solution as a coolant were used. The technique used was the one described by Ramfjord and Niesle in 1979 known as modified Widman's

flap11, the bottom of the gingival sulcus is incised directing the scalpel blade parallel to the major axis of the tooth from first premolar to first premolar and two liberatrices are made, one at each end of the intrasulcular incision and with the help of a Prichard periosteal elevator perpendicular to the root surface of the tooth displacing the gingival tissue. liberatrices one at each end of the intrasulcular incision and with the help of a Prichard periosteal elevator perpendicular to the root surface of the tooth displacing the gingival tissue with the blunt end of the instrument upwards exposing the periosteum. (Figure 8)

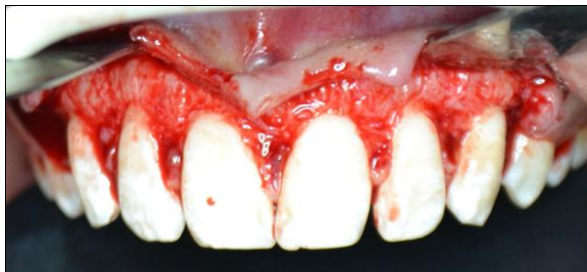

Fig 8: When the full-thickness flap is elevated, the irregular and prominent bone tissue is exposed, at 11 and 21 above the cement enamel junction. (Own elaboration)

Once the bone tissue is exposed with a pine-shaped surgical bur, the excess bone is removed, always irrigating with saline solution to avoid bone necrosis, and the irregular surfaces are refined with the help of the bone file and the 13k chisel to obtain the ideal biological thickness and a regular bone scalloping. The flap is repositioned and simple 4-0 nylon stitches are placed. In the same procedure, the upper lip is retracted with the help of a lip retractor and the amount of mucosa in the cul-de-sac that needs to be removed to correct the lip hypermobility is marked with an indelible pen. (Figure 9)

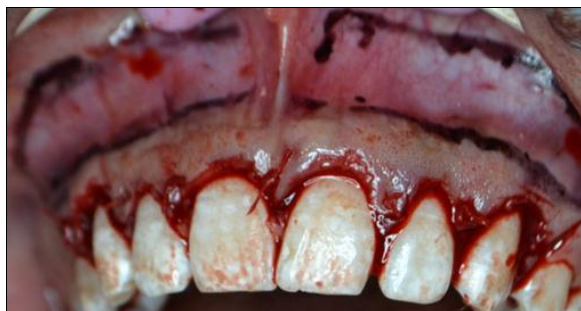

Fig 9: Marking that delimits the mucosa to be removed. (Own elaboration)

With a 15c scalpel blade a partial thickness incision is made on the mucogingival line from first premolar to first premolar without touching the anterior frenulum since this anatomical formation serves as a reference when repositioning the lip, a second incision also of partial thickness is made parallel to the first one at a distance of 14 mm, then both incisions are joined with another perpendicular incision at both ends, the epithelium is removed leaving the underlying connective tissue exposed, the mucosa is sutured with the lower edge of the first incision, on the mucogingival line (Figure 10).

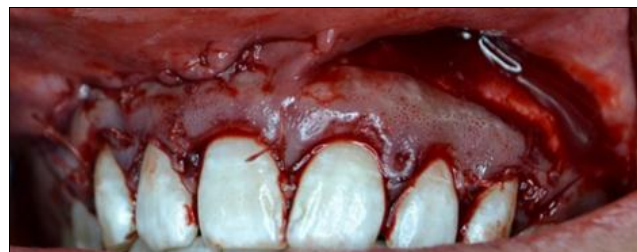

Fig 10: Left side lower cut on the mucogingival line, the space corresponds to the 14 mm of mucosa removed and the exposed connective tissue. The right side shows the tissue already repositioned and in the midline the frenulum is still maintained as an anatomical reference. (Own elaboration)

After finishing suturing the right and left side, the frenulum is removed and repositioned at the level of the adjacent sutures. (Figure 11 and 12)

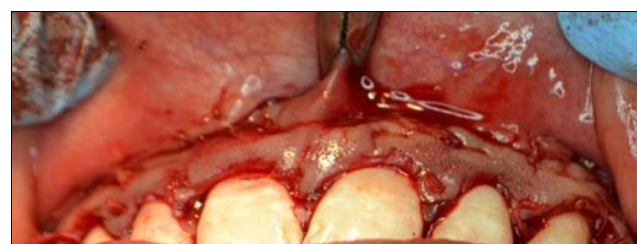

Fig 11: Hemostatic forceps holding the upper anterior labial frenulum prior to frenullectomy.

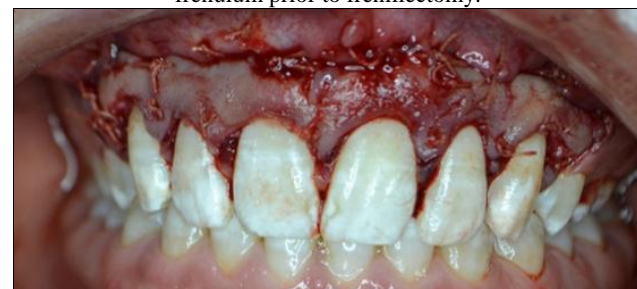

Fig 12: Final suture of the lip repositioning in the immediate postoperative period. (Own elaboration)

The patient was instructed in writing to take hygienic dietary care: Do not eat solids until the anesthetic effect has passed, do not eat fats, irritants, hot or spicy food for the next 7 days. Do not expose to heat sources in the 72 hours. Close to the postoperative period. Apply external ice packs for the next 72 hours. In case of bleeding, apply pressure with gauze. Use for 2 weeks 0.12% chlorhexidine rinses twice a day, keep one minute in the mouth, spit and stay 30 minutes without taking water or food. Avoid brushing the area with suture for 7 days. Avoid gesticulating and smiling widely to avoid losing the stitches.

Pharmacotherapy: Betamethasone 8mg. Injectable single dose. Loxoprofen 60 mg one tablet every 8 hours for 3 days. Amoxicillin with clavulanic acid 875/125 mg every 12 hours for 7 days and ketorolac 30 mg. A sublingual tablet in case of pain. Appointment was made for revision and removal of stitches after 7 days. The patient was followed up at 3 months where teeth whitening was performed to eliminate superficial pigmentation of the teeth (Figure 13) and was reviewed at 7 months postoperatively. (Figure 14)

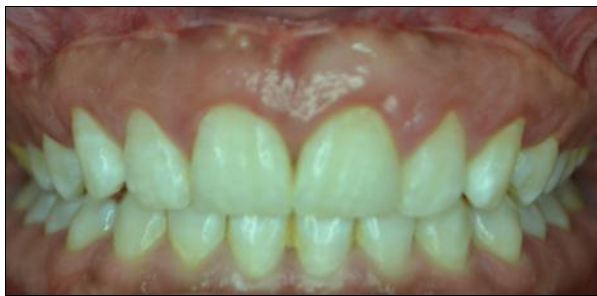

Fig 13: Healing at 3 months.

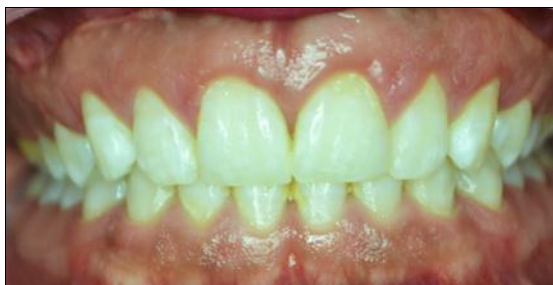

Fig 14: 7 months postoperative. (Own elaboration)

Discussion

Lip repositioning is a safe alternative for the correction of the gummy smile since the side effects are minimal, the most common ones documented by Peres [13], which have been reported are discomfort and swelling, the alternative to avoid less aggressive postoperative effects, without requiring the use of sutures is repositioning using diode laser with the only disadvantage of high cost of equipment [14]. Another less invasive treatment of choice is the application of botulinum toxin type A in a dose of 1.25 units on each side to limit the neuromuscular impulse and limit lip hyperfunction, however its use is limited to 4 mm of gingival exposure and that the etiological factor is lip hypermobility. Nunes documented in 2014 after monthly periodic evaluations that the main disadvantage is that the neuromotor response is reestablished after 6 months and the lip returns to its original site, he recommends the use for cases of smile asymmetry caused by incorrect repositioning [15]. The technique described in this case is considered a modified technique of the original one since the frenulum is kept with two adjacent lines of intact tissue to avoid having deviations of the midline and it is eliminated once both sides are repositioned [16], the technique used to eliminate the frenulum is described as Frenectomy or apical repositioning of the frenulum: This technique is based on the V-Y plastic technique, a V cut is made and at the time of suturing the scar is seen in a Y shape, it is advisable to suture at the bottom of the vestibule to avoid the loss of vestibular depth, however here there is a variation to the apical suture since it is intended to eradicate the depth of vestibule [17]. Ishida recommends myotomy of the upper lip elevator to prevent a recurrence of the original position, this cut also decreases the tension in the stitches in this case we only incise the labial mucosa considering the successful result figure 15 (before and after) based on the meta analysis published in 2020 by Dos Santos-Pereira where he made a systematic review of 368 cases and in the selection were 8 that met the same surgical standards and patient selection the average decrease in gingival smile was 2.87 mm in the immediate postoperative period, 3 months later decreased by an average of 2.71 and at 12 months by 2.10 in 95% of the cases despite the decrease in efficacy the results were still satisfactory for the patients, the range of variation in terms of

myotomy vs mucosal resection was 0.02 lower recurrence in cases with myotomy [18].

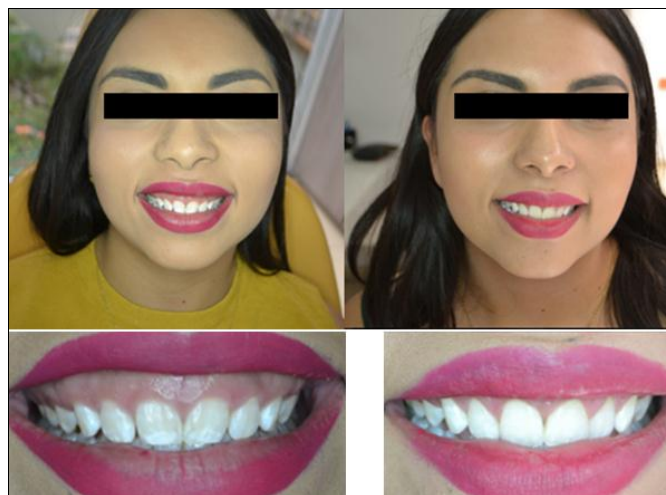

Fig 15: Preoperative 7 months postoperative period. (Own elaboration)

Conclusion

With proper treatment planning and communication, a predictable, controlled, esthetic and harmonious result can be achieved for many patients. The modified technique allows for midline guidance and avoids the morbidity associated with maxillary frenulum removal. Correct sequencing in diagnosis and choice of treatment will result in more successful outcomes.

References

1. Simon Z, Rosenblatt A, Dorfman W. eliminating a gummy smile with surgical lip repositioning. *J Cosmet Dent.* 2007;23:102-109.
2. Falcón-Guerrero B. Tratamiento de la sonrisa gingival excesiva mediante reposicionamiento labial *Revista ADM.* 2018;75(2):112-116.
3. Jensen J, Joss A, Lang NP. The smile line of different ethnic groups in relation to age and gender. *Acta Med Dent Helv.* 1999;4:38-46.
4. Monish Bhola, Peter J, Fairbairn M, Stephen J. Chu, Tamaara Morris,. *LipStat: The Lip Stabilization Technique-Indications and Guidelines for Case Selection and Classification of Excessive Gingival Display, The International Journal of Periodontics & Restorative Dentistry.* 2015;35:4.
5. Sonick M. Esthetic crown lengthening for maxilar anterior teeth. *Compend Contin Educ Dent.* 1997;18:807-812.
6. Dra. Gloria Patricia López-Herranz, Dra. Olga Gabriela Torres-Gómez Variabilidad de la clasificación del estado físico de la Sociedad Americana de Anestesiólogos entre los anestesiólogos del Hospital General de México. *Investigación Original.* 2017;40:3. Julio-Septiembre 190-194.
7. Sánchez Trocino, Díaz Acevedo. Valoración y clasificación de los pacientes en la consulta dental, *Revista odontológica latinoamericana.* 2016;8(1):8-16.
8. Sterret JD, Oliver T, Robinson F, Fortson W, Knaak B, Russell CM. Width/length ratios of normal clinical crowns of the maxillary anterior dentition in man. *Journal of clinical periodontology.* 1999;26(3):153-157.
9. Lang NP, Tonetti MS. Periodontal risk assessment (PRA) for patients in supportive periodontal therapy (SPT). *Oral*

- health & preventive dentistry. 2003;1(1):7-16.
10. Periodontal Chart online - www.perio-tools.com (periodontalchart-online.com).
 11. Tonetti MS, Greenwell H, Kornman KS. Staging and grading of periodontitis: Framework and proposal of a new classification and case definition. *J. Periodontol.* 2018;89(Suppl 1):S159-S172.
 12. Ramfjord SP. Present status of the modified Widman flap procedure. *Journal of Periodontology* Sep. 1977;48(9):558-65.
 13. Peres M, Peres R. Does Lip-Repositioning Surgery Improve Long-Term Smile Outcome and Dental Esthetics in Patients with Excessive Gingival Display? A Review of the Current Literature. *Clin Adv. Periodontics.* 2014;4:280-287.
 14. Myriam A, Pulido Rozo. Gingivoplastía y frenilectomía labial con láser de alta intensidad: presentación de caso *Revista Clínica de Periodoncia, Implantología y Rehabilitación Oral.* 2015;8(2):157-162.
 15. Levy Nunes A, José Peixoto Ferrão. Tratamiento de la sonrisa gingival con la toxina botulínica tipo A: caso clínico Junior revespcir oral maxilofacial. 2015;37(4):229-232.
 16. Shivaprasad BM. Smile correction using repositioning, crown lenghtenin and depigmentation, *International Journal of scientific research.* 2018;7(9):5-7.
 17. Fabrizi S, Barbieri Petrelli G, Vignoletti F, Bascones Martínez A. Tratamiento quirúrgico vs terapia periodontal básica: estudios longitudinales en periodoncia clínica. *Av Periodon Implantol.* 2007;19(2):161-175.
 18. Ishida L, Ishida C. Myotomy of the levator labii superioris muscle and lip repositioning: a combined approach for the correction of gummy smile. *Plast reconstr surg.* 2010 sep;126(3):1014-1019.