



# International Journal of Applied Dental Sciences

ISSN Print: 2394-7489  
ISSN Online: 2394-7497  
IJADS 2022; 8(2): 519-523  
© 2022 IJADS  
[www.oraljournal.com](http://www.oraljournal.com)  
Received: 07-02-2022  
Accepted: 15-03-2022

**Dr. Anshul Jain**  
PG Student, Department of  
Conservative Dentistry and  
Endodontics, Jaipur Dental  
College, Rajasthan, India

**Dr. Prachi**  
Reader, Department of  
Conservative Dentistry and  
endodontics, Jaipur Dental  
College, Jaipur, Rajasthan, India

**Dr. Manjari Agarwal**  
Reader, Department of  
Prosthodontics and Crown &  
bridge, Jaipur Dental College,  
Rajasthan, India

**Dr. Revtee Birajdar**  
Senior Lecturer, Department of  
Conservative dentistry and  
Endodontics, Jaipur Dental  
College, Jaipur, Rajasthan, India

**Dr. Gitanjali Singh**  
Senior Lecturer, Department of  
Conservative dentistry and  
Endodontics, Jaipur Dental  
College, Jaipur, India

**Dr. Tanya Aggarwal**  
PG Student, Department of  
Conservative dentistry and  
Endodontics, Jaipur Dental  
College, Jaipur, India

**Corresponding Author:**  
**Dr. Anshul Jain**  
PG Student, Department of  
Conservative Dentistry and  
Endodontics, Jaipur Dental  
College, Rajasthan, India

## Traumatic injuries on teeth

**Dr. Anshul Jain, Dr. Prachi, Dr. Manjari Agarwal, Dr. Revtee Birajdar,  
Dr. Gitanjali Singh and Dr. Tanya Aggarwal**

DOI: <https://doi.org/10.22271/oral.2022.v8.i2g.1550>

### Abstract

Dental traumatic injuries is one of the most common dental problems faced by the masses, yet little is known about the prevalence of dental trauma at the national level. Sports, accidents, falling, fight and hitting items or people are among common etiologic factors. In both younger and older age groups, males have a higher prevalence of maxillary and mandibular incisal trauma than females. Trauma to the dentoalveolar region is common, and it can result in tooth displacement and fracture, bone crushing or fracturing, and soft tissue injuries such as contusions, abrasions, and lacerations. Traumatic dental injuries are medical emergencies that must be treated as soon as possible to relieve pain and restore function and aesthetics. Unmet treatment demands and insufficient emergency management of TDIs have recently surfaced in dental literature, revealing that some TDIs come late for treatment, potentially creating complications in treatment.

**Keywords:** Incisal trauma, prevalence, dentoalveolar

### 1. Introduction

Clinicians all throughout the world face a dilemma with traumatic dental injuries. Damage to the tooth, as well as the supporting tissues is common in dental injuries. Dental trauma rarely involves just a single tooth rather TDIs are injuries also to the supporting structures.

Traumatic dental injuries can harm hard dental tissues as well as pulpal and periodontal structures, impairing function and appearance as well as causing mental concerns, particularly in children and teenagers<sup>[1]</sup>.

The soft tissue injuries should be assessed; displaced and lacerated tissues should be immediately repositioned and sutured wherever necessary. When teeth and their supporting structures are hit by a hard object, the consequence is either a separation or a crushing injury, or a combination of the two. Crushing injuries cause more harm because tissue cells and intercellular components are destroyed. Displacement of teeth against surrounding alveolar bone is an example of this type of injury, with invasive luxation being the worst. So, it becomes necessary to consider the cellular and humoral elements in wound healing to design suitable treatment procedures for a traumatized dentition<sup>[3]</sup>.

Homes, schools and streets are the most common places of TDIs and the most common injuries are enamel fracture and enamel and dentin fracture without pulp exposure<sup>[2]</sup>.

Some guidelines have been updated by International Association of Dental Traumatology board of directors in 2012 which includes:

Part 1: Permanent tooth fractures and luxation

Part 2: Avulsion of permanent teeth

Part 3: Injuries in primary dentition<sup>[4]</sup>.

### Etiology

Dental trauma can be caused by many ways. It is very important to know the cause of the injury as it will help in diagnosis, treatment planning and prognosis of the injury. Trauma can be due to direct or indirect impact. Sudden direct hit of the object comes under direct impact whereas impact which occurs due to trauma because of sudden forceful closure of the mandibular teeth with the maxillary opponents comes under indirect impact.

Children and adolescents are affected unequally by dental trauma. Some individuals are not affected at all or just once, while others may experience repeated trauma episodes, with no gender differences, and with repeated trauma episodes to the same teeth [5].

The aetiology shows falls as the major reason followed by traffic injuries, acts of violence, collisions and sports injuries. The accident locations were subdivided into 5 categories such as home, street, school, sports and other. The aetiology is broadly classified as:

#### 1) Human behaviour

- Risk taking
- Peer relationship problem
- Hyperactivity
- Stress behaviour

#### 2) Environmental factors

- Deprivation
- Overcrowding

#### 3) Unintentional Injuries

- Falls and collisions
- Physical leisure activities
- Traffic accidents
- Inappropriate use of teeth
- Biting hard items
- Presence of physical limitations or learning difficulties.

#### 4) Intentional Injuries

- Physical abuse
- Iatrogenic procedures

#### 5) Physical leisure activity

- High risk sports: American football, hockey, ice hockey, martial sports, rugby and skating.
- Medium risk sports: basketball, diving, squash, gymnastics, parachuting and water polo

#### Epidemiology

Despite TDIs relatively high occurrence, severe impact on individuals and society, and a sound body of knowledge regarding its causal elements and treatment, traumatic dental injuries remain a neglected oral ailment. Moreover, the remarkable decline of the prevalence and severity of dental caries amongst children in many countries may have made TDI the most serious dental public health challenge among youth in those countries. This is because traumatic dental injuries effects mainly the front teeth, thus aesthetic and facial attraction, while dental caries in children with low levels of the disease present only small occlusal caries in molars. Furthermore, most treatments needed for TDI are more complex and expensive than treatment of occlusal caries. [6]

Worldwide the proportion of maxillofacial trauma in relation to all types of traumas reported from hospital accident and emergency departments varies from 9% to 33% [7].

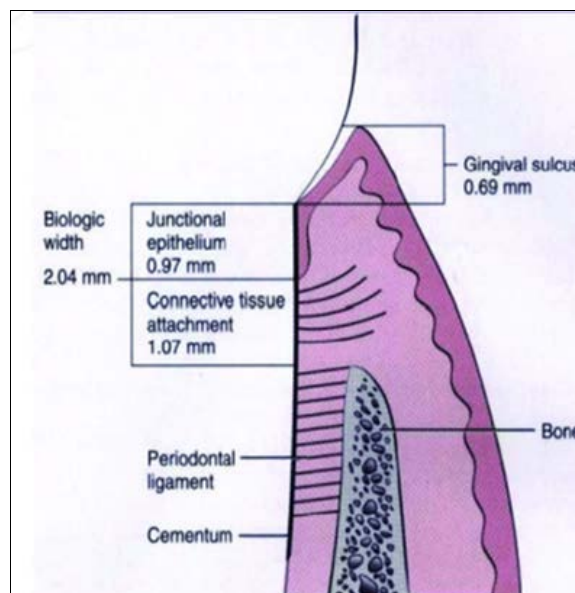
#### Anatomical considerations

Dentoalveolar trauma involves many tissues and structures. When assessing the impact of trauma, planning correct treatment, and evaluating the outcome, knowing the typical structure of teeth and their supporting tissues is beneficial [8]. Enamel, dentin, and cementum are the three hard tissues that make up a tooth. Dentin is formed by pulp cells and

cementum is formed by periodontal ligament cells [9].

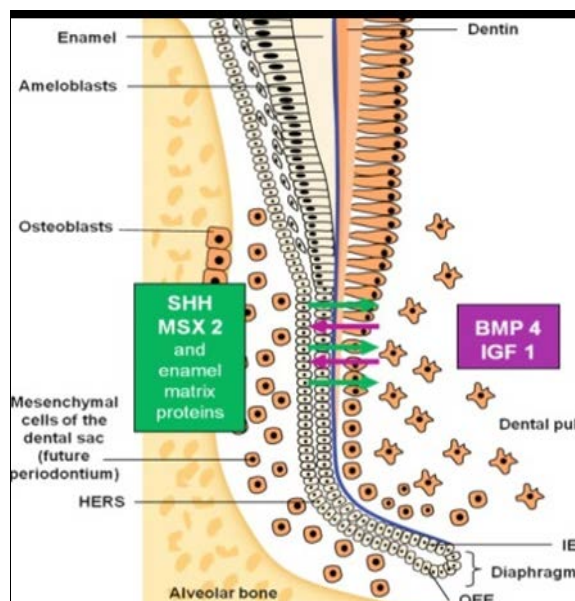
Embryologically, the alveolar bone is composed of the alveolar bone proper and the alveolar process. The alveolar bone proper (lamina dura) is the compact bone (cortical bone) within the alveolus and is formed by periodontal ligament cells.

The periodontal membrane situated between the alveolar bone and the cementum, is connected to the tooth and the alveolar bone or gingival connective tissue with the help of Sharpey's fibres. This connective tissue attachment on the alveolar bone margin is usually about 1mm wide, and the epithelial attachment is approximately 1mm coronally. This 2mm width is called the biologic width [10]



**Fig 1:** The connective tissue attachment and epithelial attachment form the 'biologic width' averaging 2mm.

The reduced enamel epithelium separated from the enamel was originally Hertwig's epithelial root sheath. The inner and outer enamel epithelium unite in the reduced enamel epithelium tissue. The epithelial sheath of the Hertwig is crucial for root development [8].



**Fig 2:** A proliferation of epithelial cells found in the cervical loop of the enamel organ in a developing tooth is known as the hertwig's epithelial root sheath.

### Events of wound healing

The generally accepted definition of wound healing is: 'a reaction of any multicellular organism on tissue damage to restore the continuity and function of the tissue or organ'. This is a functional definition that says very little about the process and the elements that influence it.

Wound healing mechanisms in the periodontium, pulp, and possibly related soft tissue are common in traumatic dental injuries. The final healing result is determined by the outcome of these. The general response of these tissues to surgical and traumatic injuries is a sensitive process, where even very small changes in the treatment procedure may have an impact upon the rate and quality of healing <sup>[11]</sup>.

Whenever the injury destructs the tissue, a sequence of events is initiated whose final goal is to heal the damaged tissue. The sequence of events which occurs after wounding is control of bleeding; establishing a line of defence against infection; cleansing the wound site of necrotic tissue elements, bacteria or foreign bodies; closing the wound gap with newly formed connective tissue and epithelium; and ultimately modifying the primary wound tissue to a more functionally suitable and stable tissue <sup>[11]</sup>.

It is important to define various terms in relation to wound healing such as repair and regeneration. In this context, it has been proposed that the term regeneration refers to "a biologic process in which the structure and function of disrupted or lost tissue are fully restored", whereas repair or scar formation refers to "a biologic process in which the continuity of the disrupted or lost tissue is regained by new tissue that does not restore structure and function".

The process of wound repair can often lead to scarless healing for small superficial wounds <sup>[12]</sup>.

### Classification

Dental injuries have been classified according to a variety of factors, such as aetiology, anatomy, pathology or therapeutic considerations.

#### ✦ Ellis and davey's classification 1960 <sup>[13]</sup>

This classification is based on numeric system though it is simple and is only applicable to the permanent dentition. This is one of the most widely accepted methods of classification on numeric system. It is simple but only applicable to permanent dentition.

Class I – Simple crown fracture with little or no dentin involved.

Class II – Extensive fracture of the crown involving part of dentin, but not the dental pulp.

Class III – Extensive fracture of the crown involving dentin and the dental pulp.

Class IV – Teeth that have been traumatised and have become non-vital, with or without loss of crown structure.

Class V – Teeth lost because of trauma.

Class VI –Root fractures can occur with or without crown structural loss.

Class VII –Displacement of a tooth without a crown or root fracture.

Class VIII– Fracture of crown in masse and its replacement.

#### ✦ Sweet's classification of anterior teeth (1955) <sup>[14]</sup>

This classification is mainly based on the anatomy and morphology of the tooth structure.

Class I – A fracture of crown exposing no dentin

Class II – A fracture of crown involving little dentin.

Class III – Extensive fracture of crown involving more dentin

but no pulp exposure.

Class IV – Crown fracture with extensive pulp exposure.

Class V – Complete crown fracture exposing pulp.

Class VI –Root fracture with (or without) crown structure loss.

Class VII – Tooth loss because of trauma.

### Examination and diagnosis

A dental injury should be handled as an emergency and treated as soon as possible to alleviate discomfort, facilitate tooth reduction, and enhance prognosis in some cases. Minor injuries, on the other hand, can often be treated later.

An accurate diagnosis is required for rational therapy, which can be accomplished using a variety of diagnostic approaches. The clinician will use the information gathered from various evaluation techniques to define these trauma components and determine treatment priorities. It is important to recognise that an insufficient examination might lead to erroneous diagnosis and treatment failure.

An adequate clinical examination depends upon a thorough examination of the entire injured area and the use of special examination techniques. Data registration can be aided by using standardised examination charts. The following is a summary of these diagnostic procedures:

1. Recording of extraoral wounds and palpation of the facial skeleton.
2. Recording of injuries to the gingiva or oral mucosa.
3. The existence and extent of fractures, pulp exposures, and colour changes are all examined on the crowns of teeth.
4. Recording of displacement of teeth (i.e. lateral displacement, avulsion, intrusion, extrusion).
5. Occlusal disturbances.
6. Abnormal mobility of alveolar fragments or teeth.
7. Palpation of the alveolar process.
8. Teeth sensitivity to percussion and a change in percussion tone (ankylosis).
9. Teeth's reaction to pulpal sensitivity tests.

Extra-oral wounds are usually present in cases resulting from traffic accidents. The position of these wounds can indicate where and when dental injuries should be suspected, for example, a wound under the chin signals premolar and molar dental injuries, as well as a simultaneous fracture of the mandibular condyle and/or symphysis. Jaw fractures can be discovered by palpating the facial skeleton. A jaw fracture can be indicated by submucosal hematomas under the tongue, in the vestibular area, or in the palate.

Subcutaneous hematomas can potentially be a sign of a facial bone fracture.

Oral mucosa or gingiva injuries should be recorded.

Gingival lacerations are often associated with displaced teeth. Non-lacerated marginal gingiva bleeding implies periodontal ligament injury.

### Crown fracture

Out of all dental traumatic injuries the crown fractures account for the highest percentage.

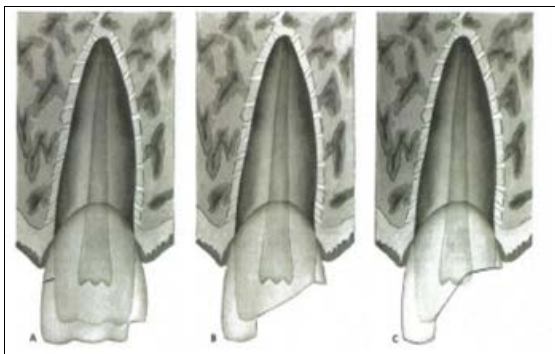
Crown fractures take in 26 to 76% of dental injuries in permanent dentition <sup>[15]</sup>.

#### Types of Crown Fracture (fig.3)

A) Enamel fracture - a fracture with loss of tooth substance confined to enamel (uncomplicated crown fracture)



- B) Enamel-dentin fracture: A tooth fracture that involves only the enamel and dentin and does not involve the pulp (uncomplicated crown fracture)
- C) Enamel-dentin fracture involving the pulp (complicated crown fracture).



### Intrusive luxation

Intrusive luxation is the displacement of the tooth into the alveolar bone along the axis of the tooth along with comminution or fracture of the alveolar socket.

Intrusive luxation is a common type of dental injuries in the primary dentition but it occurs less frequently in permanent incisors. Intrusive injuries can often lead to severe complications and due to which this is the most serious and difficult to manage group of dental injuries. The complications include pulp necrosis, inflammatory tooth resorption, ankylosis and replacement resorption, and loss of marginal bone support [16].

### Extrusive luxation

Partial displacement of the tooth out of its socket [17]. The frequency of extrusive luxation has been found to be 7% among traumatized permanent teeth examined at a major trauma centre [18]. The afflicted tooth appears enlarged clinically, is frequently displaced in the palatal direction, and has considerable mobility. The percussion sound is dull.

Extruded teeth show an expanded periodontal space especially apically [19].

Extrusion is treated by relocating the extruded tooth as soon as possible and stabilising it with a splint for up to three weeks [20].

### Subluxation

An injury to the tooth-supporting structures with abnormal loosening, but without Displacement [21]. In a study from a larger trauma centre, frequency of 21% was found for subluxation [22]. Subluxated teeth maintain their regular dental arch position. However, the tooth is mobile in a horizontal direction and sensitive to percussion and occlusal forces.

### Concussion

Concussion is characterized by an injury to the supporting structures of the tooth, with no displacement and only minor damage to the periodontal ligament. [23]

In a study from a larger trauma centre, frequency of 23% was found for concussion. [22]

Even though these injuries are considered minor, they can lead to problems including pulp canal obliteration, external inflammatory resorption, or pulp necrosis with infection.

Concussion can lead to the injury to the neurovascular bundle in the apical region and this may lead the injury to the innervation of the tooth and the affected teeth do give

response to sensitivity tests. [24]

### Avulsion

Tooth avulsions suggest total tooth displacement out of its socket. The most commonly avulsed teeth are the maxillary central incisors, while the lower jaw is rarely impacted. Teeth avulsion is most common in youngsters between the ages of 7 and 9, when the permanent incisors are erupting.

The weakly organised periodontal ligament and low mineralized bone surrounding growing teeth offer relatively minor resistance to an extrusive force at this age. Avulsion involves a single tooth most frequently, but multiple avulsions can also be seen which may involve more than one tooth [25].

### Prevention

Traumatic dental and maxillo-facial injuries are very common and appear world-wide to affect approximately 20-30% of permanent dentition and with often serious psychological, economic, functional and aesthetic consequences for the individual. With such a high rate of injuries, preventing them becomes a top priority. Such an approach must take its origin in an identification of common causes for these injuries and whether such causes can be avoided or if preventive measures can be used to reduce the impact of such injuries. The best way to prevent dental and oral injuries is definitely to educate yourself on how to avoid them and how to deal with them if they happen.

Appliances to Prevent Dental Injuries

- Mouth guard
- Faceguard
- Helmets [11]

### Conclusion

Traumatic dental injuries have become a major public health and dental concern. Prevention and treatment of TDI should be emphasized to the public, the health professional and the policy maker. Dental injuries are common, and some people experience many injuries. In addition to treatment time, the family's efforts are time and money intensive.

The most ignored aspect of the traumatic dental injury is patients' mental health concerns. The situations like loss of a tooth or parts of teeth often resulted in a compromised psychological condition. The case's prognosis is determined by the accurate diagnosis and treatment provided. It is also important to have proper documentation, not only for medico legal reasons but to have a baseline reference regarding the traumatic injury. With precise documentation during the initial assessment, future treatment modalities and outcomes can be effectively managed.

### References

1. Juliana Vilela Bastos<sup>1</sup>, Eugenio Marcos Andrade Goulart<sup>2</sup>, Maria Ilma de Souza Cortes. Pulpal response to sensibility tests after traumatic dental injuries in permanent teeth *Dental Traumatology*. 2014;30:188-192.
2. Hayriye sonmez the prevalence of traumatic injuries treated in the pedodontic clinic of Ankara university, turkey, during 18 months.
3. Marie Therese Flores, Barbro Malmgren guidelines for the management of traumatic dental injuries'. primary teeth
4. International association of dental traumatology, dental trauma guidelines, revised 2012.
5. Forsberg CM, Tedestam G. Etiological and predisposing factors related to traumatic injuries to permanent teeth.

- Swedish dental journal. 1993;17(5):183-90.
6. Marcenes W, Al Beiruti N, Tayfour D, Issa S. Epidemiology of traumatic injuries to the permanent incisors of 9- 12-year-old schoolchildren in Damascus, Syria. *Endod Dent Traumatol.* 1999;15:117-123. Munksgaard, 1999
  7. Hayter, JP Ward AJ, Smith EJ. Maxillofacial trauma in severely injured patients. *British journal of Oral and Maxillofacial surgery.* 1991;29:370-373.
  8. Tsukiboshi M. Treatment planning for traumatized teeth. *Quintessence;* 2000 Feb 1.
  9. Ten Cate AR. *Oral Histology, Development, Structure and Function*, ed 3, St. Louis: Mosby, 1989.
  10. Babitha Nugala, Santosh Kumar BB, Sahitya S, Mohana Krishna P. Biologic width and its importance in periodontal and restorative dentistry *J Conserv Dent.* 2012;15(1):12-17.
  11. Andreasen JO, Andreasen FM. *Textbook and Color Atlas of Traumatic Injuries to the Teeth*, ed 3. Copenhagen: Munksgaard. 1993, 316-256.
  12. Anthony Atala, Darrell J. Irvine, Marsha Moses, and Sunil Shaunak *Regeneration: Role of the Tissue Environment in Regenerative Medicine MRS BULLETIN*, 2010 August, 35.
  13. Shobha Tondon. *Textbook of pedodontics.* 2nd Edition; Paras Publishing: 2008, (18).
  14. Pagadala S, Tadikonda DC. An overview of classification of dental trauma. *IAIM*, 2015;2(9):157-164
  15. Olsburgh S, Jacoby T, Krejci I. Crown fractures in the permanent dentition: pulpal and restorative considerations. *Dent Traumatol* 2002;18:103-115. #Blackwell Munksgaard, 2002
  16. Oulis C, Vadiakas G, Sisko G. Management of intrusive luxation injuries. *Endod Dent Trainnatol* 1996; 12: 11.VI 19. © Munksgaard, 1996
  17. Zafer C, Cehreli, DDS, PhD Sezgi Sara, DDS Burak Aksoy, DDS *Revascularization of Immature Permanent Incisors After Severe Extrusive Luxation Injury* Originally published in the *Journal of the Canadian Dental Association*; *J Can Dent Assoc* 2012;78:c4. Reprinted with permission.
  18. ANDREASEN F M, VESTERGAARD PEDERSEN B. Prognosis of luxated permanent teeth the development of pulp necrosis. *Endod Dent Traumatol* 1985; (in press). 16
  19. Andreasen FM, Atidreaseen JO. Diagnosis of luxation injuries: The importance of standardized clinical, radiographic and photographic techniques in clinical investigations. *Endod Detit 'Traumatol.* 1985;1:160-169.
  20. Pontifical Catholic University of Paraná, Curitiba, Paraná, Brazil *Treatment of extrusive luxation by intentional replantation International Journal of Paediatric Dentistry.* 2007;17:134-138.
  21. Rock WP, DDS FDS, DOrth MC. Grundy, FDS RCS The effect of luxation and subluxation upon the prognosis of traumatized incisor teeth *Journal of Dentistry*, 9, No. 3, 1981, 224-230 Printed in Great Britain
  22. Mette Kit Borum, Jens Ove Andreasen *therapeutic and economic implications of traumatic dental injuries in Denmark; international journal of paediatric dentistry.* 2001;11:249-258.
  23. Darley RM, Fernandes e Silva C, Costa FDS, Xavier CB, Demarco FF. Complications and sequelae of concussion and subluxation in permanent teeth: A systematic review and meta-analysis. *Dent Traumatol.* 2020;00:1-11.
  24. Michiel de Cleen, DDS *Obliteration of pulp canal space after concussion and subluxation: Endodontic considerations (Quintessence Int.* 2002;33:661-669.
  25. Andreasen JO, Borum M, Andreasen FM. Replantation of 400 avulsed permanent incisors. I. Diagnosis of healing complications. *Endod Dent Traumatol.* 1995;11:69-75.