



ISSN Print: 2394-7489
ISSN Online: 2394-7497
IJADS 2022; 8(3): 95-103
© 2022 IJADS
www.oraljournal.com
Received: 02-05-2022
Accepted: 10-06-2022

Dr. Hussain Mookhtiar
Assistant Professor, Department of
Conservative dentistry and Endodontics,
M.A. Rangoonwala dental college and
research centre, Pune, Maharashtra,
India

Dr. Vivek Hegde
Professor and HOD,
Department of Conservative Dentistry
and Endodontics, M.A. Rangoonwala
dental college and research centre, Pune,
Maharashtra, India

Dr. Mehrosh Khan
Post graduate Student,
Department of Conservative Dentistry
and Endodontics, M.A. Rangoonwala
dental college and research centre, Pune,
Maharashtra, India

Dr. Dhananjay Ghunawat
Associate Professor, Department of
Conservative Dentistry and
Endodontics, M.A. Rangoonwala dental
college and research centre, Pune,
Maharashtra, India

Dr. Preet Soni
Private Practitioner, Mumbai,
Maharashtra, India

Dr. Taha Attarwala
Assistant Professor, Department of
Prosthodontics M.A. Rangoonwala
dental college and research centre, Pune,
Maharashtra, India

Zahra Shakil Memon
Under graduate Student,
Department of Conservative Dentistry
and Endodontics, M.A. Rangoonwala
dental college and Research centre,
Pune, Maharashtra, India

Asiya Zaynab Malik
Under graduate Student,
Dept. of Conservative Dentistry and
Endodontics, M.A. Rangoonwala dental
college and research centre, Pune,
Maharashtra, India

Corresponding Author:
Dr. Hussain Mookhtiar
Assistant Professor, Department of
Conservative dentistry and Endodontics,
M.A. Rangoonwala dental college and
research centre, Pune, Maharashtra,
India

Recent trends in post endodontic restorations: A comprehensive case series

Dr. Hussain Mookhtiar, Dr. Vivek Hegde, Dr. Mehrosh Khan, Dr. Dhananjay Ghunawat, Dr. Preet Soni, Dr. Taha Attarwala, Zahra Shakil Memon and Asiya Zaynab Malik

DOI: <https://doi.org/10.22271/oral.2022.v8.i3b.1590>

Abstract

Root canal treatment is said to be completely successful when the tooth is restored and comes back to normal function. A more complex restoration is required after endodontic treatment when compared to normal tooth restoration, because of factors such as extensive caries, post-treatment root canal dentin and even the economics condition of the patient. With the availability of newer high strength materials like lithium disilicate dentists are now able to offer better esthetics and high strength restoration which withstands heavy occlusal forces with even thin layers. Thus, the aim of this case series is to summarize the recent advances of post endodontic restorations, various new materials their indications depending on the remaining tooth structure and the teeth that needs to be restored.

Keywords: post endodontic restorations, onlay, overlay, crownlay, endocrowns, vonlay

1. Introduction

Endodontically treated teeth are at a higher risk of fracture as compared to vital teeth as root canal treatment leads to weakening of tooth structure as a result of changes in tooth architecture, changes in properties of dentin and changes in proprioception [1]. The remaining tooth structures quality and quantity should be considered in order to decide the best available restorative option for each case, as extensive restoration leads to destruction of remaining tooth structure [1].

According to the cuspal coverage, the type of restoration can be classified as onlays where at least one cusp is covered, inlays where no cusp is covered and overlays wherein all the cusps are covered. Cuspal coverage protects the remaining tooth structure from heavy occlusal loading which extends the life of the tooth [2, 3]. A recent advancement is the introduction of endocrowns, zirconia post and core and crownlays which assembles the intra-radicular post, the core and the crown in one component giving it a monoblock effect [4]. With the availability of newer high strength materials like lithium disilicate dentists are now able to offer better esthetics and high strength restoration which withstands heavy occlusal forces with even thin layers [5]. One of these are Veenerlay or vonlay which is a blend of an onlay with an extended buccal veneer surface for use in premolar region, where there is sufficient enamel present to bond. With the properties of both vonlay provides esthetics as well as resistance to the heavy loading forces [6, 7, 8].

So, the purpose of this case series is to summarize the recent advances of post endodontic restorations, various new materials their indications depending on the remaining tooth structure and the teeth that needs to be restored.

Case no 1: Zirconia Cast Post and core

A 40 years old female came to the Department of Conservative Dentistry and Endodontics at M.A. Rangoonwala College of Dental Sciences and Research Centre, Pune with the chief complaint of repetitive dislodgement of crown in upper anterior region of jaw.

The tooth 11 i.e maxillary right central incisor was RC treated and the patient needed it to be restored. The medical history was non-contributory. After clinical and radiographical evaluation, zirconia cast post and core was planned with 11 after taking consent from the patient. (Figure 1).

Post Space Preparation and Fabrication

Post- space preparation was done using Peeso-reamers leaving around 5mm of gutta percha within the canal. Pattern

resin (GC India) was used for making the pattern of the canal. (Figure 2 and 3) A single unit Zirconia post and core was fabricated using CAD-CAM milling technique. (Figure 4). After evaluating the zirconia post and core intra orally, luting was done using resin luting cement. After the completion of tooth preparation impression was made with polyvinyl siloxane impression material of light and putty consistency using a double-mix single-stage technique for the fabrication of crown. (Figure 5 and 6).

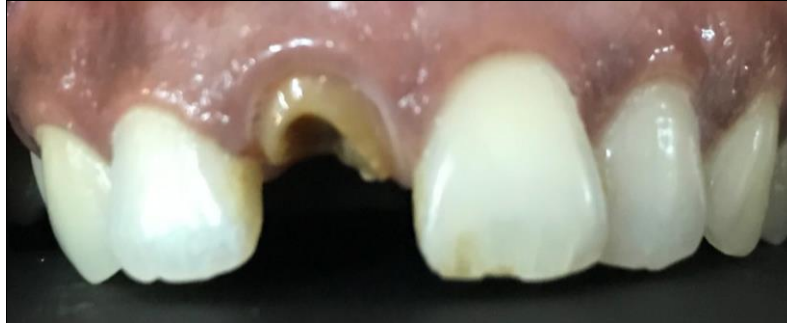

Fig 1: Pre-operative

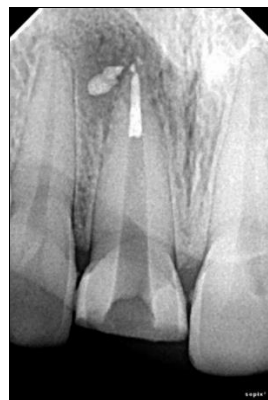

Fig 2: Post-space preparation

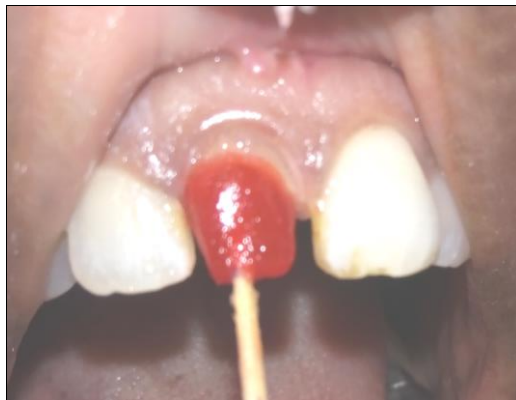

Fig 3: Pattern using pattern resin

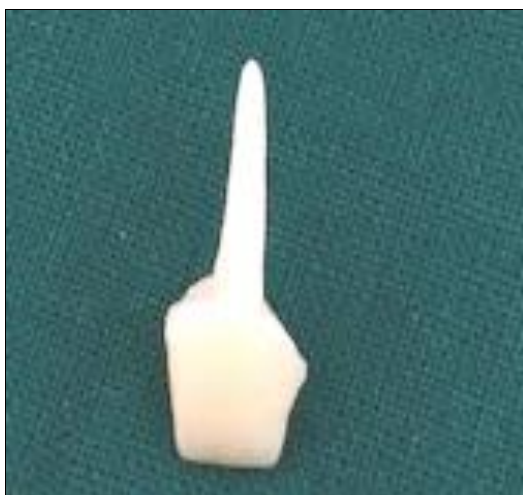

Fig 4: Fabricated Zirconia Post and Core

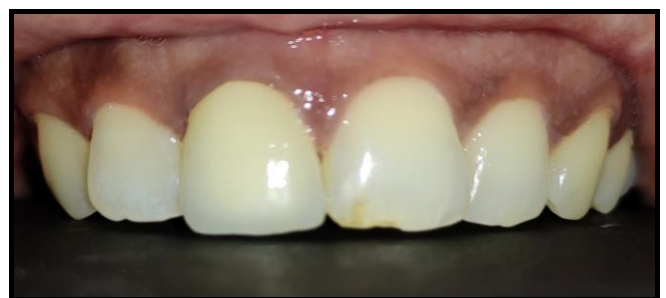

Fig 6: Post-operative

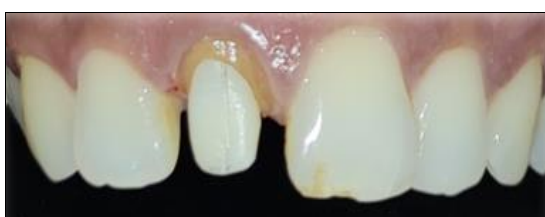

Fig 5: Post Cementation

Case No 2: Endocrown

A 42-year-old female was referred to the Department of Conservative Dentistry and Endodontics at M.A. Rangoonwala College of Dental Sciences and Research Centre, Pune. He suffered from major coronal destruction and needed to have her 1st Mandibular Right Molar restored. Radiographic and clinical examinations were performed initially, to check the amount of remaining tooth structure and the apical status of the previous endodontic treatment. The patient had an acceptable oral hygiene and a favourable occlusion after which at endocrown restoration was recommended because of the amount of remaining tooth structure and the thickness of the walls. The prosthetic decision was to restore tooth (46) with an endocrown fabricated from monolithic Lithium Disilicate (IPS E.Max).

Prior to commencement of preparation, shade selection was done. (Figure 7).

Tooth Preparation

The aim was to achieve an overall reduction in the height of the occlusal surface of at least 2 mm in the axial direction and to get a cervical margin or “cervical sidewalk” in the form of a butt joint. The cervical margin has to be supragingival and enamel walls less than 2 mm have to be eliminated. Axial preparation using a tapered bur included only removal of undercuts from the access cavity. Total occlusal convergence of 7° to create continuity between the coronal pulp chamber and endodontic access cavity. (Figure 8) After the completion

of tooth preparation impression was made with polyvinyl siloxane impression material of light and putty consistency using a double-mix single-stage technique. (Figure 9) The Lithium Disilicate was milled using CAD/CAM milling technique. (Figure 10) After verifying the fit, the endocrown was cemented intraorally using resin luting cement. The inner surface was etched with 10% hydrofluoric acid was washed with water and dried. Silane coupling agent was applied for 1 min and dried. The tooth was etched for 10 seconds and washed and dried using botting paper. Adhesive was applied and cured for 20 secs. Resin cement was applied on the inner surface and endocrown was cemented using resin cement. (Figure 11).

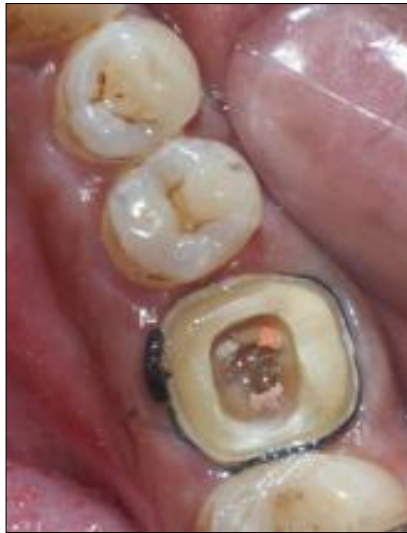

Fig 7: Pre-operative

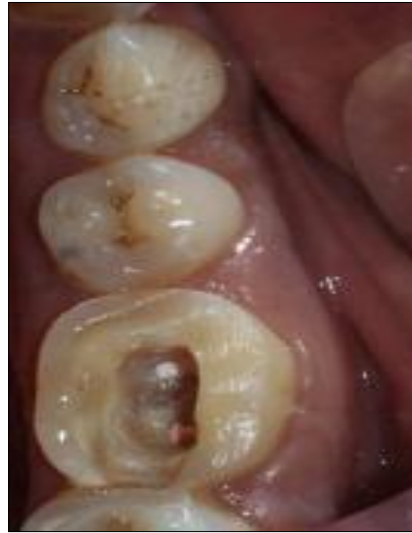

Fig 8: Endocrown preparation

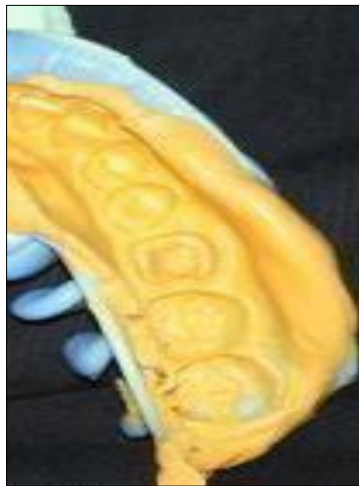

Fig 9: Putty Impression

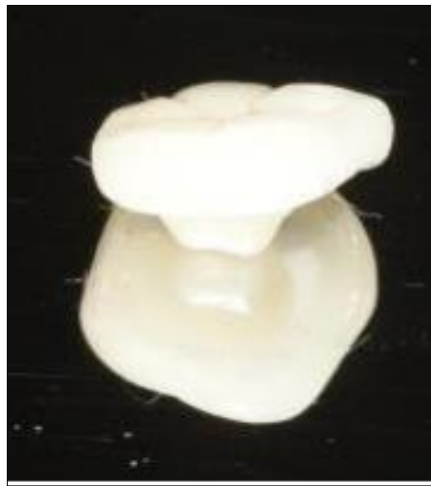


Figure 10: Fabricated Endocrown

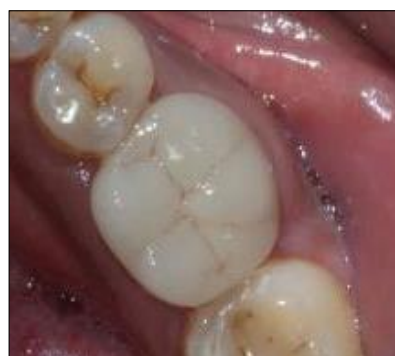
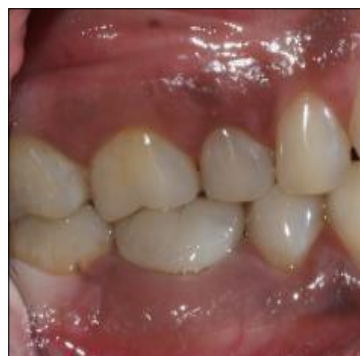
Fig 11: Post Cementation

Case no 3: Crownlay

A 29-year-old male was referred to the Department of Conservative Dentistry and Endodontics at M.A. Rangoonwala College of Dental Sciences and Research Centre, Pune. He suffered from gross crown destruction and needed to have maxillary 1st left Molar and mandibular 1st molar restored due to caries. Radiographic and clinical examinations were performed initially, to check the amount of remaining tooth structure and the apical status of the previous endodontic treatment. The patient's oral hygiene was acceptable and a favourable occlusion after which crownlay restorations was recommended because of the amount of remaining tooth structure and the thickness of the walls. The prosthetic decision was to restore tooth (26 and 36) with crownlay fabricated from monolithic lithium disilicate (IPS e.max). Prior to commencement of preparation, shade selection was done. (Figure 12 and 13).

Crownlay Preparation

An overall reduction in the height of the occlusal surfaces of at least 2 mm in the axial direction and to get a Occlusal table or "Occlusal sidewalk" in the form of a butt joint was achieved. Occlusal Preparations were done using a flat ended tapered diamond bur to achieve a shoulder finish line for the

seating of the ceramic crownlays. Axial preparation using a tapered bur included only removal of undercuts from the access cavity. Total occlusal convergence of 7° to create continuity between the coronal pulp chamber and endodontic access cavity similar to that of an endocrown was prepared. Finishing of the preparations were done using fine grit finishing bur. (Figure 14, 15, 16)

After the completion of tooth preparations impressions were made with polyvinyl siloxane impression material of light and putty consistency using a double-mix single-stage technique using a triple tray. (Figure 17 and 18) The Lithium Disilicate was milled using CAD/CAM milling technique. (Figure 19)

After verifying the fit, the crownlays was cemented intraorally using resin luting cement. The inner surface was etched with 10% hydrofluoric acid was washed with water and dried. Silane coupling agent was applied for 1 min and dried. The tooth was etched for 10 seconds and washed and dried using botting paper. Adhesive was applied and cured for 20 secs. Resin cement was applied on the inner surfaces and crownlays was cemented using light cure. The gross occlusal discrepancies were marked with articulating paper strips and later removed before cementation. Post cementation radiographic view showed appropriate seating of the crown. (Figure 20, 21, 22).

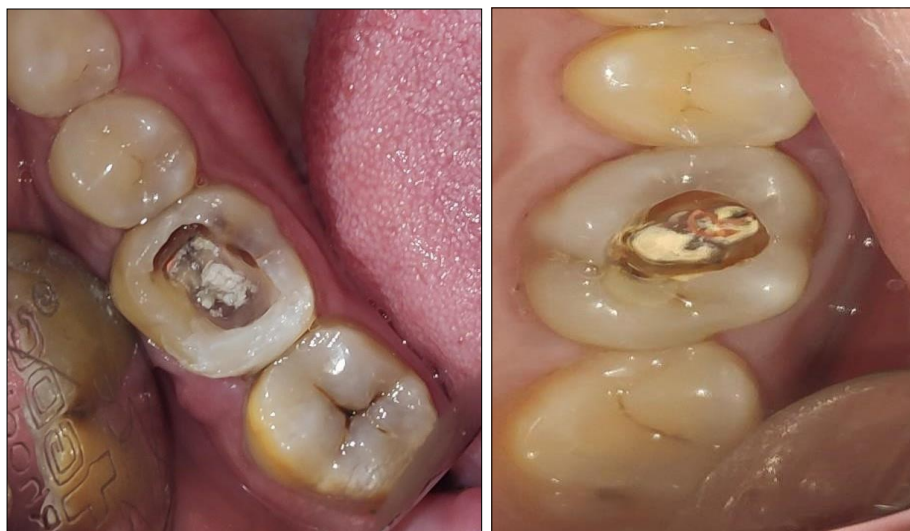

Fig 12 and 13: Pre-operative

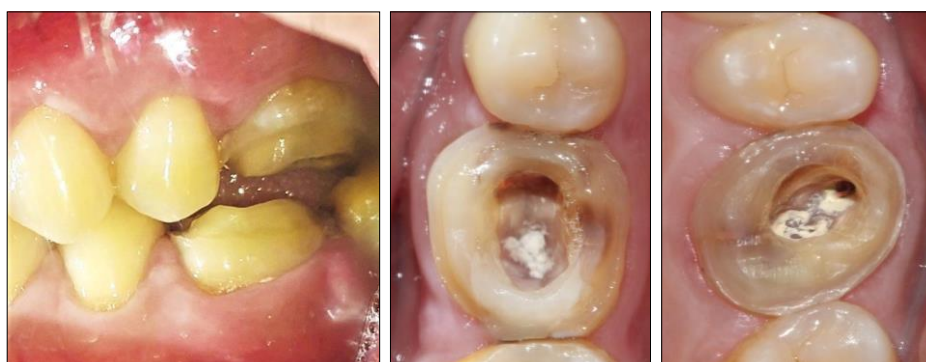

Fig 14-16: Tooth Preparation

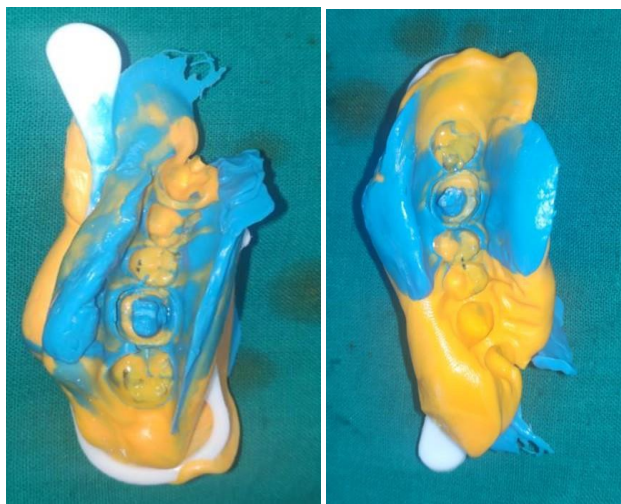


Fig 17 and 18: Triple tray putty impression

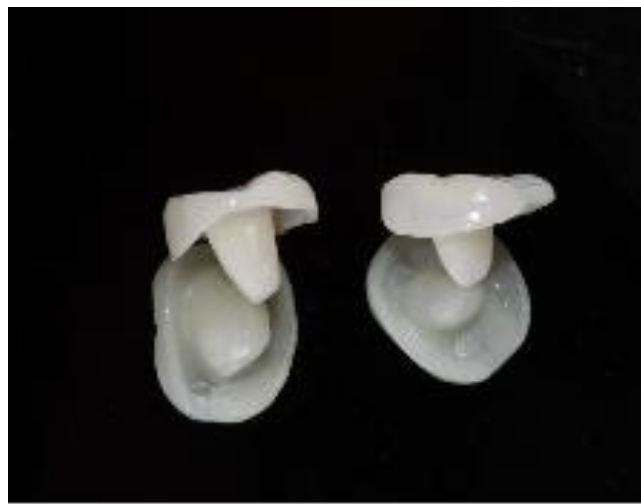

Fig 19: Fabricated Crownlay

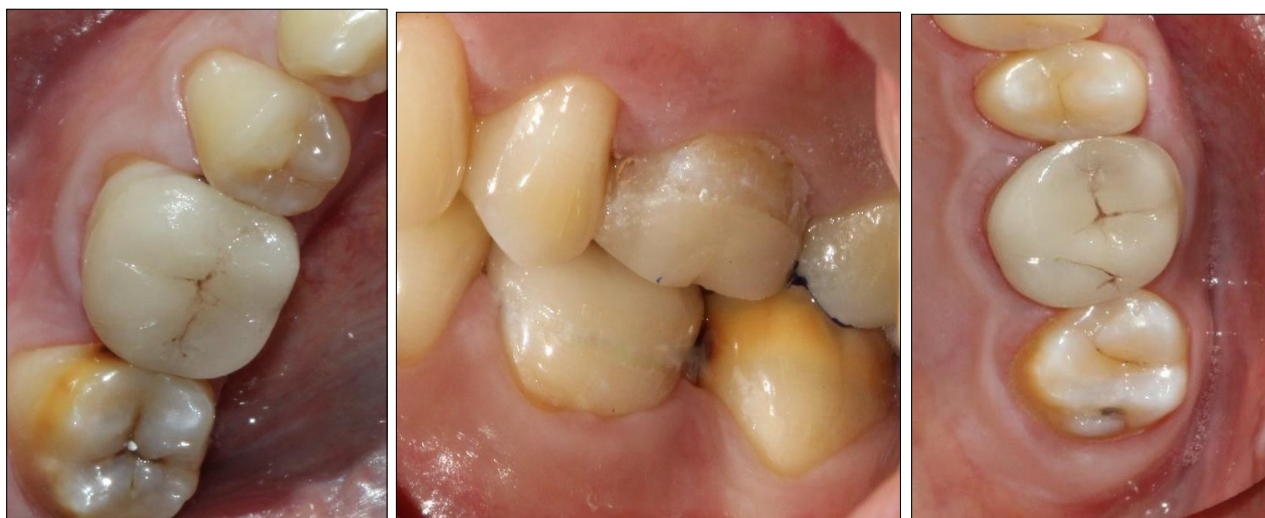

Fig 20-22: Post-operative

Case no 4 Vonlay

A 26-year-old female was referred to the Department of Conservative Dentistry and Endodontics at M.A. Rangoonwala College of Dental Sciences and Research Centre, Pune. She suffered from deep occlusal carious lesion suspected of pulpal involvement. After radiographic and clinical examinations, the amount of remaining tooth structure and confirmation of pulpal involvement, non-surgical endodontic treatment was proposed to the patient and performed. For Post endodontic treatment planning after patient's oral hygiene considerations was acceptable and a favourable occlusion and aesthetic consideration vonlay restoration fabricated from monolithic lithium disilicate (IPS e.max) was proposed as an alternative to full crown which was agreed by the patient. Prior to commencement of preparation, shade selection was done. (Figure 23 and 24)

Occlusal Preparation (Onlay)

The aim was to achieve overall reductions in the height of the occlusal surfaces of at least 2 mm in the axial direction and to get a Occlusal table or "Occlusal sidewalk" in the form of a butt joint. Occlusal Preparations were done using a flat ended tapered diamond bur to achieve a shoulder finish line for the seating of the ceramic onlay.

Buccal Preparation (Veneer)

Depth cuts were placed on the buccal surface using diamond depth cutting bur. The remaining enamel was removed using round end tapered diamond bur to obtain a supragingival chamfer finish line which will aid in placement of the veneer. Proximal reduction was performed using round end tapered diamond bur parallel to the long axis of the tooth. The proximal reduction was stopped just short of breaking the contact. The final finishing of the preparation was done using fine grit diamond bur. (Figure 25, 26 and 27)

After the completion of tooth preparation impression was made with polyvinyl siloxane impression material of light and putty consistency using a double-mix single-stage technique. The Lithium Disilicate was milled using CAD/CAM milling technique. (Figure 28)

After verifying the fit, the vonlay was cemented intraorally using resin luting cement. The inner surface was etched with 10% hydrofluoric acid was washed with water and dried. Silane coupling agent was applied for 1 min and dried. The tooth was etched for 10 seconds and washed and dried using botting paper. Adhesive was applied and cured for 20 secs. Resin cement was applied on the inner surface and vonlay was cemented using light cure. The gross occlusal discrepancies were marked with articulating paper strips and later removed before cementation. (Figure 29 and 30).

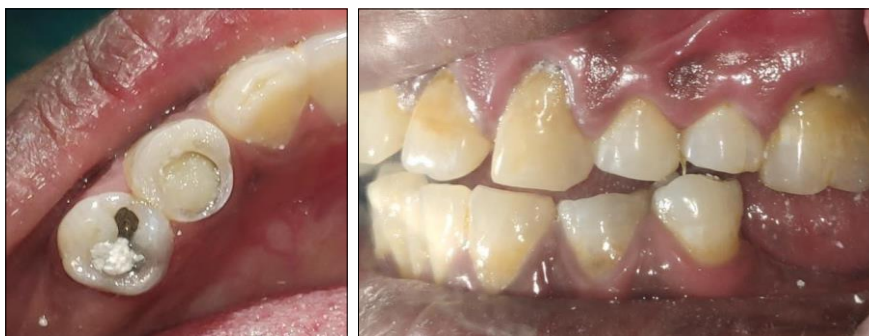

Fig 23 and 24: Pre-operative

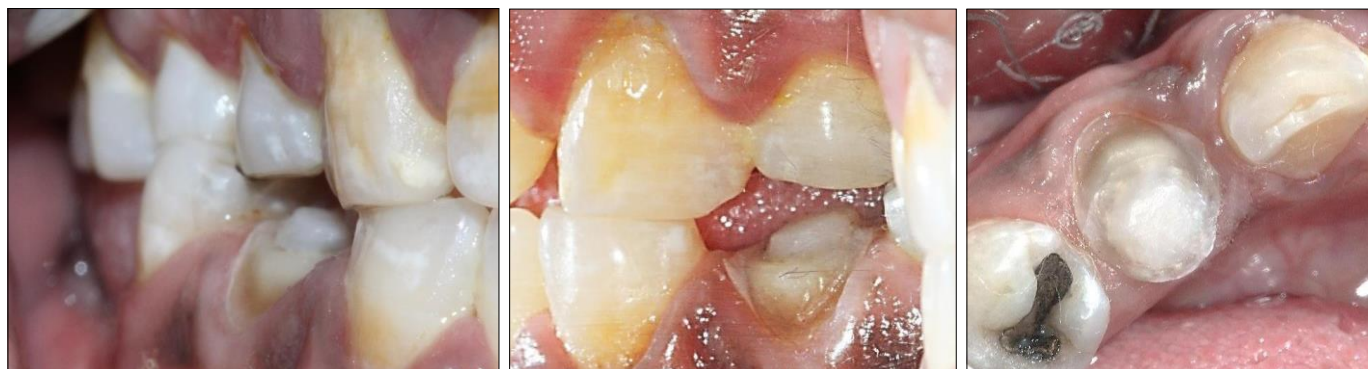

Fig 25-27: Tooth Preparation

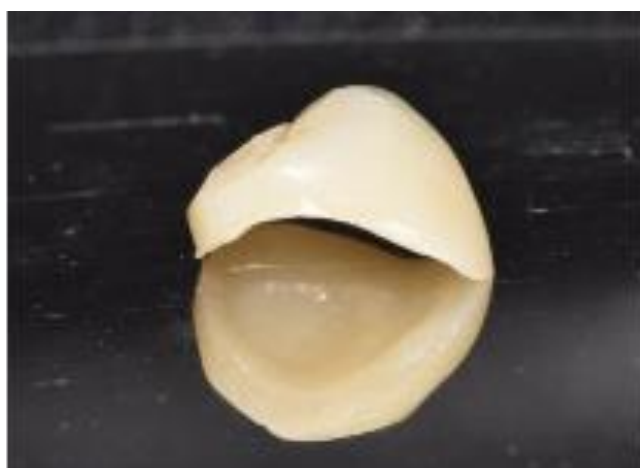

Fig 28: Fabricated Vonlay

in the lower left back region of jaw. Radiographic and clinical examinations concluded for endodontic treatment with respect to 36. Following endodontic treatment, post endodontic treatment planning was planned after patient’s oral hygiene considerations was acceptable and a favourable occlusion and aesthetic consideration zirconia overlay restoration was fabricated with 36. (Figure 31).

Overlay preparation:

The pulp chamber was sealed using light cured restorative material. An overall reduction in the height of the occlusal surface of at least 2 mm in the axial direction was done on the functional cusps and a cervical margin or “cervical sidewalk” in the form of a butt joint was given. Occlusal Preparations were done using a flat ended tapered diamond bur to achieve a shoulder finish line for the seating of the ceramic overlay. Margins were placed on the cervical third of the crown. (Figure 32).

After the completion of tooth preparation impression was made with polyvinyl siloxane impression material of light and putty consistency using a double-mix single-stage technique. Zirconia overlay was milled using CAD/CAM milling technique. (Figure 33).

After verifying the fit, the overlay was cemented intraorally using resin luting cement. The inner surface was etched with 10% hydrofluoric acid was washed with water and dried. Silane coupling agent was applied for 1 min and dried. The tooth was etched for 10 seconds and washed and dried using botting paper. Adhesive was applied and cured for 20 secs. Resin cement was applied on the inner surface and overlay was cemented using light cure. The gross occlusal discrepancies were marked with articulating paper strips and later removed before cementation. (Figure 34).

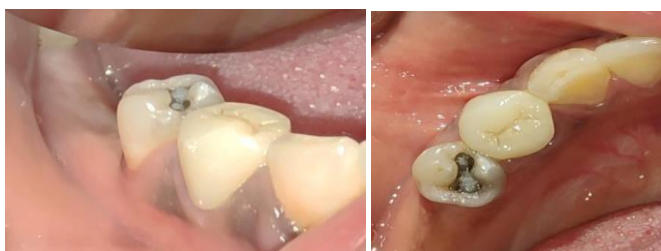

Fig 29 and 30: Post-operative

Case no 5: Overlay- Occlusal Preparation (Overlay):

A 29-year-old female was referred to the Department of Conservative Dentistry and Endodontics at M.A. Rangoonwala College of Dental Sciences and Research Centre, Pune with the chief complaint of grossly carious tooth

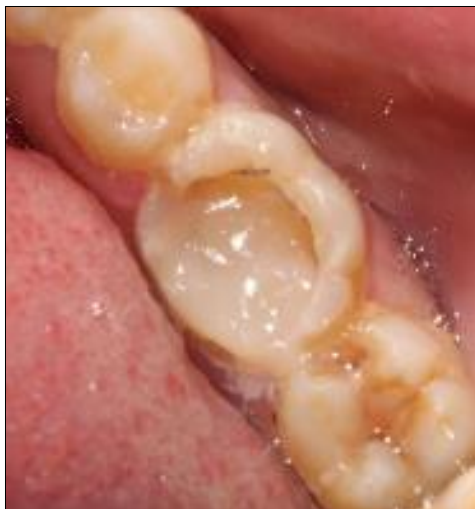

Fig 31: Pre-operative

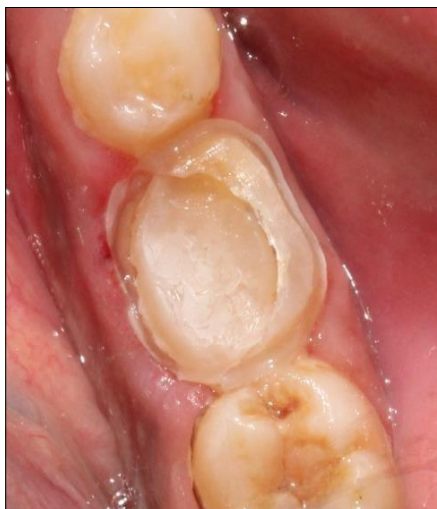

Fig 32: Tooth Preparation

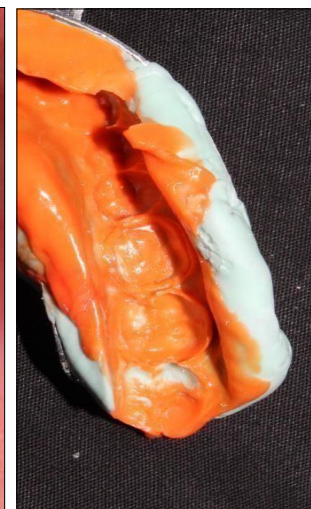

Fig 33: Impression

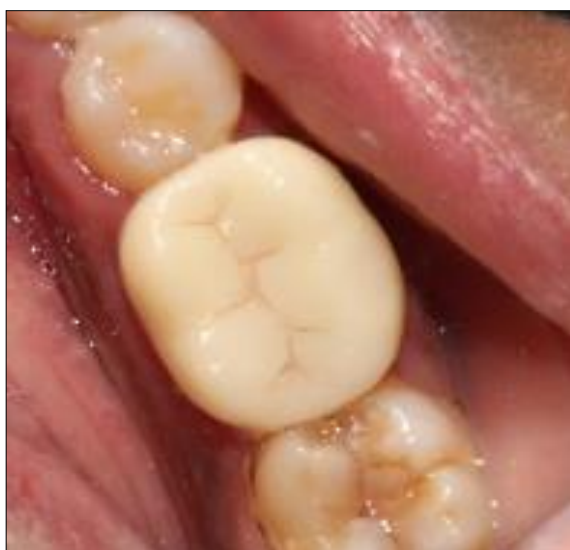

Fig 34: Post-Cementation

Case no 6 Onlay

A 32-year-old male was referred to the Department of Conservative Dentistry and Endodontics at M.A. Rangoonwala College of Dental Sciences and Research Centre, Pune with the chief complaint of decayed tooth in lower right back region of jaw. Radiographic and clinical examinations were performed initially, which concluded to mesio-occluso-distal caries approaching the pulp which required endodontic treatment. Following endodontic treatment, post endodontic treatment was planned after patient's oral hygiene considerations were acceptable and a favourable occlusion and aesthetic consideration zirconia onlay restoration was fabricated with 36 after consent from the patient. Shade selection was performed prior to commencement of treatment. (Figure 35).

Onlay preparation

The pulp chamber was sealed using a light cured restorative material.

Proximal Preparation:

Cavity preparation was done on the mesial, distal and occlusal surfaces using a 271 carbide bur internal angles were rounded using 271 bur and occlusal divergence of 10 deg. was achieved. Occlusal bevel was given using flame shaped diamond finishing bur. Gingival bevel on the mesial and distal

axial walls were given using flame shaped finishing diamond.

Occlusal Preparation

The aim was to achieve overall reductions in the height of the occlusal surfaces of at least 2 mm in the axial direction and to get a Occlusal table or "Occlusal sidewalk" in the form of a butt joint. Occlusal Preparations were done using a flat ended tapered diamond bur to achieve a shoulder finish line for the seating of the ceramic onlay. Functional cusp bevel was given on the functional cusps using flame shaped finishing bur. (Figure 36).

After the completion of tooth preparation impression was made with polyvinyl siloxane impression material of light and putty consistency using a double-mix single-stage technique. (Figure 37) Zirconia onlay was milled using CAD/CAM milling technique.

After verifying the fit, the onlay was cemented intraorally using resin luting cement. The inner surface was etched with 10% hydrofluoric acid was washed with water and dried. Silane coupling agent was applied for 1 min and dried. The tooth was etched for 10 seconds and washed and dried using botting paper. Adhesive was applied and cured for 20 secs. Resin cement was applied on the inner surface and onlay was cemented using light cure. The gross occlusal discrepancies were marked with articulating paper strips and later removed before cementation. (Figure 38).

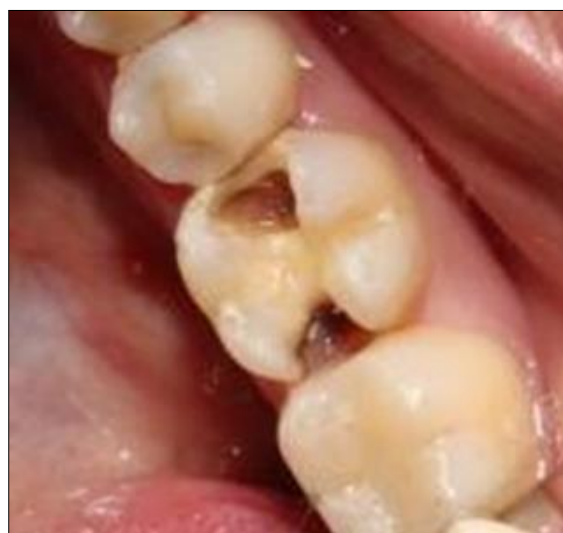

Fig 35: Pre-operative

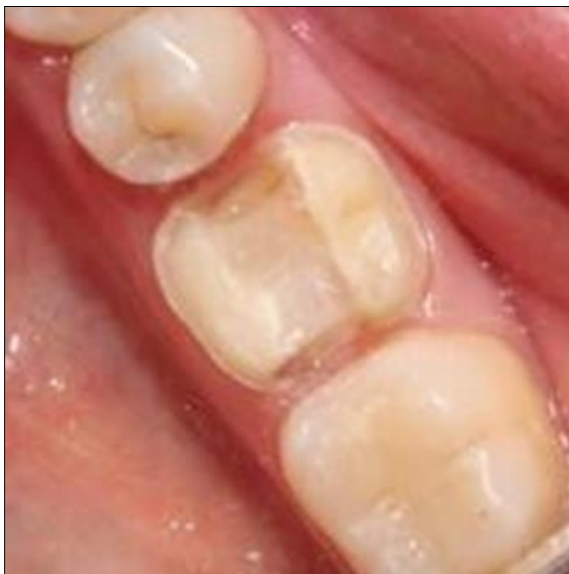

Fig 36: Tooth preparation

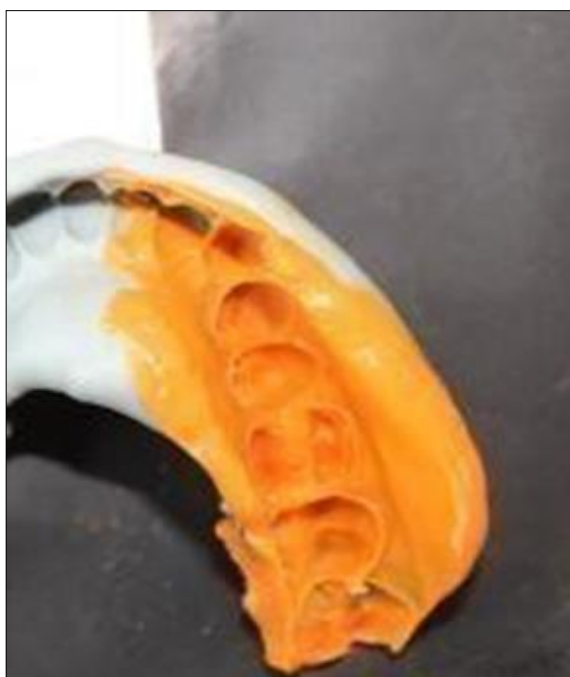

Fig 37: Impression

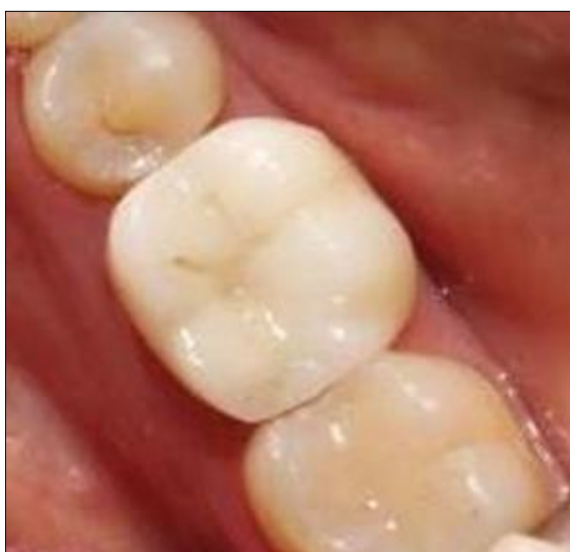

Fig 38: Post-operative

Discussion

Post endodontic restorations have evolved from the traditional metal posts and cores to fibre posts and cores to partial coverage restorations which bond to tooth structure. There are two broad categories of fixed dental prosthesis; old category known as conventional restorations that depend on frictional or mechanical retention and recent category known as minimally invasive MI or adhesive restorations that depend on adhesives [9]. Conventional restorations can be fabricated from esthetic or non-esthetic materials whereas MI restorations are fabricated from esthetic materials only. Nowadays, selecting the best restorative option for posterior teeth is a challenge because of many minimally invasive restorations available [10].

Traditionally, if a patient requires restoration in the posterior region, full coverage restoration was thought to be the ideal treatment option, however the problem encountered with the full coverage restoration which includes increasing the amount of tooth reduction which may lead in some cases to pulp involvement resulted in a shift to recently introduced minimally invasive dentistry which aims to preserve as much tooth structure as possible whenever feasible. So, Partial coverage restorations have been introduced in the dental field trying to fulfill the idea of conservative preparation where minimal preparation of the teeth is done, thus enhancing mechanical resistance and retention forms. The rationale behind Ceramic onlays, Endocrowns, Vonlays and Crownlays is that a monolithic ceramic bonded restoration with a butt joint keeping as much as possible enamel for improved adhesion and aesthetics [11].

A concept given by Bindl and Mörmann the rationale behind Endocrown is that a monolithic ceramic bonded restoration with a supragingival butt joint keeping as much as possible enamel for improved adhesion. The endocrown will invade the pulp chamber only thus the remaining dentin of the root canal is not affected [12].

In 2012, Biacchi *et al.* compared the fracture strength of 2 types of full ceramic crowns: indirect conventional crowns retained by glass fibre posts and endocrowns. They came to the conclusion that endocrowns were more resistant to compressive forces than the first ones [11]. Da Cunha *et al.* and Silva-Sousa *et al.* in their studies concluded that stress levels with endocrowns were lower than in teeth with prosthetic crowns [13, 14].

Dr. Ronald E Goldstein is “Veenerlay” or “Vonlay”. Vonlay is a blend of an onlay with an extended buccal veneer surface for use in premolar region, where there is sufficient enamel present to bond. Vonlay that are considered a conservative combination approach combining the veneer and the onlay restorations and can be used as an alternative to full coverage restoration in the posterior region. It covers the buccal and occlusal surfaces of the teeth. The buccal surface is covered by veneer which can fulfil the aesthetic considerations as well as partial coverage restoration. Veneers are rarely given for premolar restoration [15]. According to a study conducted by Nadig RR *et al.* inferred that stress seen with indirect onlay, Vonlay as post endodontic restorative designs were relatively less and can be regarded as suitable alternative to full crown restorations for restoring ETT maxillary premolar [16].

Concept of Crownlays are similar to endocrown, however they are minimally invasive preparations than endocrowns. Crownlays and Endocrowns will invade the pulp chamber only, thus the remaining dentin of the root canal is not affected. The pulpal chamber shape and cavity warrants stability and retention. Unfortunately, too many research

articles are not published on crownlays and clinical as well as research evidences should be made for this new technique [17]. A proposal is to be also made in the near future for the change in name from Crownlay to Hu-crown in the near future.

Bonded onlays are mainly indicated when there is a prerequisite for protective coverage of the tooth cusps without doing conventional crown to preserve the amount of remaining tooth structure. Also, they can be used for treatment of advanced occlusal wear and reinforcement of teeth with cracked tooth syndrome. Unlike the conventional MOD onlays, the preparation for bonded onlays is defect specific, non-retentive with no sharp corners or acute angles and ensuring sufficient thickness of ceramic materials [18].

Conclusion

With the evolution in post endodontic restorations, bonded minimally invasive bonded ceramic restorations represents a very hopeful treatment alternative for endodontically treated teeth. It allows maintaining of tooth structure, it is compatible with minimally invasive dentistry, and it is adequate for the concept of bio-integration along with aesthetics. It is a conservative approach for mechanical and aesthetic restoration of nonvital teeth. More research projects and clinical cases are needed to be published in the near future for long term success of endodontically treated teeth.

References

- Heling I, Gorfil C, Slutzky H, Kopolovic K, Zalkind M, *et al.* Endodontic failure caused by inadequate restorative procedures: Review and treatment recommendations. *J Prosthet Dent.* 2002;87(6):674-678.
- Sturdevant CM, Sturdevant JR. Cavity preparation for cast metal onlay. *The Art and Science of Operative Dentistry.* 5 th ed. Roberson T, Heyman H, Swift Ed editors. New Delhi: Elsevier, 2010, 301
- Badr F, Jin Seong W, Perdigão J. Restoring the Endodontically Treated Tooth: Treatment Planning Considerations. *Restoration of Root Canal-Treated Teeth,* 2016, 45-66.
- Yoldas O, Akova T, Uysal H. An experimental analysis of stresses in simulated flared root canals subjected to various post-core applications. *J Oral Rehabil.* 2005;32(6):427-43
- Larson TD. 25 years of veneering: What have we learned? *Northwest Dent.* 2003;82(4):35-39
- Heffernan MJ, Aquilino SA, Diaz-Arnold AM, *et al.* Relative translucency of six all ceramic systems. Part I: core materials. *J Prosthet Dent.* 2002;88(1):4-9.
- Lin CL, Chang YH, Pa CA. Estimation of the risk of failure for an endodontically treated maxillary premolar with MODP preparation and CAD/CAM ceramic restorations. *J Endod.* 2009;35:1391-5
- Nishtha A. Comparison of fracture resistance of endodontically treated single rooted premolar restored using a cast post and onlay, with a new design Sharonlay. Unpublished Post-Doctoral Dissertation. Rajiv Gandhi University of Health Sciences, 2014.
- Dejak B, Mlotkowski A. 3d-finite element analysis of molars restored with endocrowns and posts during masticatory simulation. *Dent Mater.* 2013;29(12):e309-317
- Govare N, Contrepolis M. Endocrowns: A systematic review. *The Journal of Prosthetic Dentistry.* 2020 Mar 1;123(3):411-8.
- Biacchi GR, Mello B, Basting RT. The endocrown: an alternative approach for restoring extensively damaged molars. *Journal of Esthetic and Restorative Dentistry.* 2013 Dec;25(6):383-90.
- Bindl A, Mörmann WH. Clinical evaluation of adhesively placed cerec endo-crowns after 2 years – preliminary results. *J Adhes Dent.* 1999;1:255-65
- L. Fernandes da Cunha, J. Mondelli, C. M. Auersvald *et al.*, Endocrown with leucite-reinforced ceramic: case of restoration of endodontically treated teeth, *Case Reports in Dentistry*, vol. 2015, Article ID 750313, 4 pages, 2015.
- Silva-Sousa Y, Gomes EA, Dartora NR, *et al.*, Mechanical behavior of endodontically treated teeth with different endocrowns extensions, *Dental Materials.* 2017;33(1):e73-e74.
- McLaren EA, Figueira J, Goldstein RE. Vonlays: A conservative esthetic alternative to full-coverage crowns. *Compend Contin Educ Dent.* 2015;36(4):282-286-9.
- Nadig RR, Garian R. Stress distribution pattern in endodontically treated mesio occlusally involved premolars restored with ceramic onlay, vonlay and full crown restorations.
- Sultan S, Al Garni H, Al Onazi M, Gangi KK, Al Otha S, Al Ruwaili F, *et al.* Minimally Invasive Posterior Full Crown Competitors: Onlays, Occlusal Veneers, Vonlays and Endocrowns: A Review and Proposed Classification. *Journal of International Dental and Medical Research.* 2021;14(4):1617-22
- Mainjot AKJ. The One step-No prep technique: A straightforward and minimally invasive approach for full-mouth rehabilitation of worn dentition using polymer infiltrated ceramic network (PICN) CAD-CAM prostheses. *J Esthet Restor Dent.* 2020;32(2):141-9.