



ISSN Print: 2394-7489
ISSN Online: 2394-7497
IJADS 2023; 9(1): 160-162
© 2023 IJADS

www.oraljournal.com

Received: 16-10-2022

Accepted: 25-11-2022

Dr. Kaustubh Chandwale
Postgraduate Student,
Department of Orthodontics and
Dentofacial Orthopaedics,
Government Dental College and
Hospital, Mumbai, Maharashtra,
India

Dr. Amrita Batho
Postgraduate Student,
Department of Periodontology,
Government Dental College and
Hospital, Mumbai, Maharashtra,
India

Dr. Gopinath Kallampilly
Professor, Department of
Orthodontics and dentofacial
Orthopaedics, Government
Dental College and Hospital,
Mumbai, Maharashtra, India

Dr. CD Dhalkari
Professor, Department of
Periodontology, Government
Dental College and Hospital,
Mumbai, Maharashtra, India

Dr. Suryakant Powar
Associate Professor, Department
of Orthodontics and Dentofacial
Orthopaedics, Government
Dental College and Hospital,
Mumbai, Maharashtra, India

Dr. Rajesh Gaikwad
Associate Professor, Department
of Periodontology, Government
Dental College and Hospital,
Mumbai, Maharashtra, India

Dr. Afra Sultan
Postgraduate Student,
Department of Orthodontics and
Dentofacial Orthopaedics,
Government Dental College and
Hospital, Mumbai, Maharashtra,
India

Corresponding Author:
Dr. Kaustubh Chandwale
Postgraduate Student,
Department of Orthodontics and
Dentofacial Orthopaedics,
Government Dental College and
Hospital, Mumbai, Maharashtra,
India

Management of palatal entrapment of mini-implant supported pendulum appliance: A case report

Dr. Kaustubh Chandwale, Dr. Amrita Batho, Dr. Gopinath Kallampilly, Dr. CD Dhalkari, Dr. Suryakant Powar, Dr. Rajesh Gaikwad and Dr. Afra Sultan

DOI: <https://doi.org/10.22271/oral.2023.v9.i1c.1674>

Abstract

This case report describes the surgical management of mucosal entrapment of a mini-implant-supported molar distalization appliance.

A 17-year-old female patient was referred for removal of a implant-supported pendulum appliance entrapped in the palatal mucosa, which is used for molar distalization by the Department of Orthodontics. The clinical findings suggested that the overlying soft tissue was non-inflammatory and occurred due to forceful impingement of the wire component on the palatal mucosa.

Surgical intervention was planned for removal of the mucosal entrapped appliance. A V-shaped incision was made under local anesthesia to expose the wire. The Appliance was completely removed, and silk sutures were placed for proper primary closure. Healing was uneventful, with minimal discomfort.

While there are risks associated with orthodontic treatment with fixed and removable appliances, they can be avoided by adopting the required measures during treatment and educating patients about their responsibilities.

Keywords: Mini-implant supported pendulum appliance, palatal mucosa, soft tissue, entrapment, encapsulated

Introduction

Unexpected traumatic injuries to oral soft tissues may occur during or after treatment due to the misuse of dental instruments, chemicals, or appliances, in addition to the potential known complications of any given dental treatment, which the patient should be informed of prior to therapy. Orthodontic treatment is no exception to this. The fixed orthodontic appliance may have wires, brackets, bands, tubes, hooks and other supporting parts including elastomeric chains, coil springs, ligature wires, elastic modules, and orthodontic mini-screws placed inside the oral cavity that might rub against the mucosa and irritate it [1]. These components also act as nidi for plaque accumulation, increasing the need for oral hygiene maintenance [2]. Trauma to the soft tissue and soft tissue growth over the orthodontic appliances may occur because of operators' faulty appliance delivery to the patient or improper maintenance of the appliance by the patient [3]. Gingival and mucosal trauma and impingement lesions may secondarily become infected and worsen the situation. The therapy for dental trauma should always begin with a thorough evaluation of the affected area in order to make a good diagnosis and start the right course of action [4]. The examination should involve a thorough assessment of the hard tissues, including the teeth and bone, clinical and radiographic examinations, pulp vitality, percussion, and mobility tests. In addition, it is necessary to examine the soft tissues inside and outside the mouth.

This case report describes the surgical treatment of mucosal entrapment of a mini-implant-supported molar distalization appliance.

Case report

A 17-year-old female patient was referred to Department of periodontics for removal of a mini-implant-supported pendulum appliance entrapped in the palatal mucosa in which is used for molar distalization [5] by the Department of Orthodontics. During the patient's fixed orthodontic therapy, the appliance was in place for last eight months (figure 1).

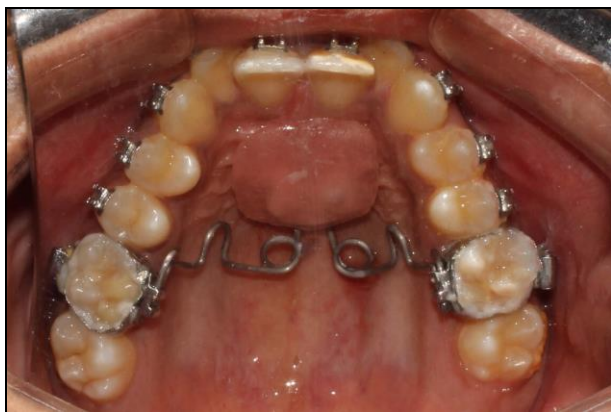

Fig 1: Mini-implant-supported pendulum appliance

During the follow-up visit, mucosal entrapment of the palatal appliance was observed (figure 2). An intraoral inspection revealed that the wire component of the appliance on the left side was embedded in the hard palatal mucosa. The mucosal cover did not show any signs of inflammation or bleeding. The affected area was non-tender upon palpation. The clinical findings suggested that the overlying soft tissue was non-inflammatory and occurred due to forceful impingement of wire component on the palatal mucosa.

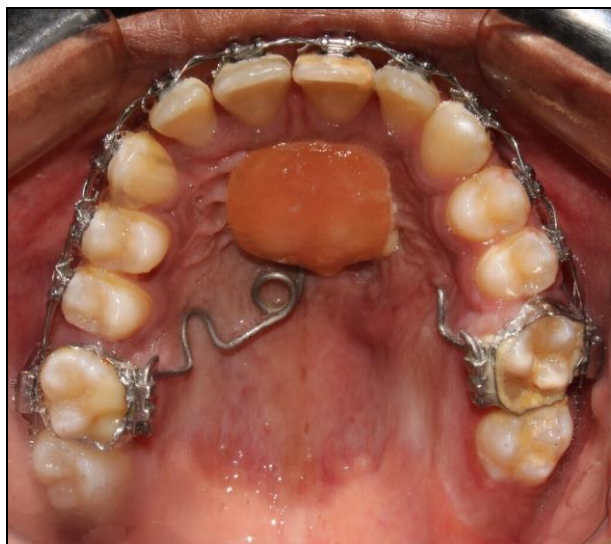

Fig 2: Partial palatal soft tissue entrapment of orthodontic appliance

Case management

A pre-surgical mouth rinse with 10 ml 0.2% chlorhexidine gluconate solution was performed for 1 min. Local anesthesia was induced in the palate using a greater palatine and incisive nerve block with 2% lignocaine with a 1:200,000 concentration of adrenaline. The acrylic palatal button covering the mini-implant was removed (figure 3), and the underlying food debris and composite resin material were cleaned, followed by removal of the mini-implants using implant driver as adequate molar distalization was achieved (figure 4). Soft-tissue probing was performed to locate the metallic component of the appliance in the palatal tissue to minimize soft-tissue injury. The distal end of the wire was disengaged, the helix was traced, and a V-shaped incision was made to expose the wire. Using a wire cutter, the helix component was cut on the mesial side and removed from the tissue. The remaining wire was traced in a similar manner and removed from the palatal tissue with a minimal incision. For primary closure, silk sutures were placed which were

removed a week later (figure 5). All the removed components of the appliances were assessed to eliminate the possibility of entrapping the remaining parts (figure 6). Postoperative instructions were given, and the patient was prescribed antibiotic Amoxicillin 500 mg thrice daily for 3 days and analgesic Aceclofenac (100 mg) and paracetamol (500 mg) combination, twice daily for 3 days. Betadine mouth rinse was prescribed twice daily for one week. Healing was uneventful, with minimal discomfort (figure 7).

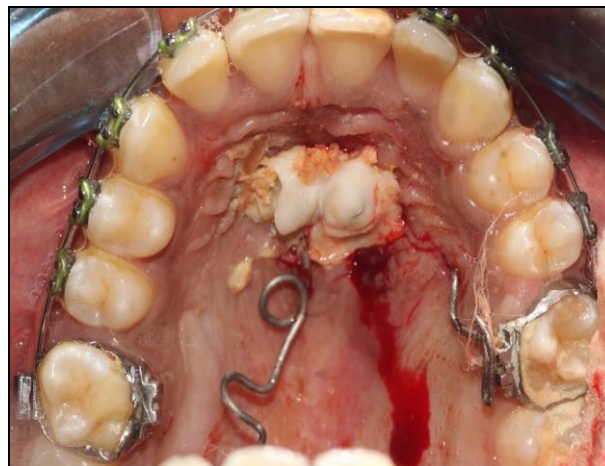

Fig 3: Removal of acrylic button to access mini-implants

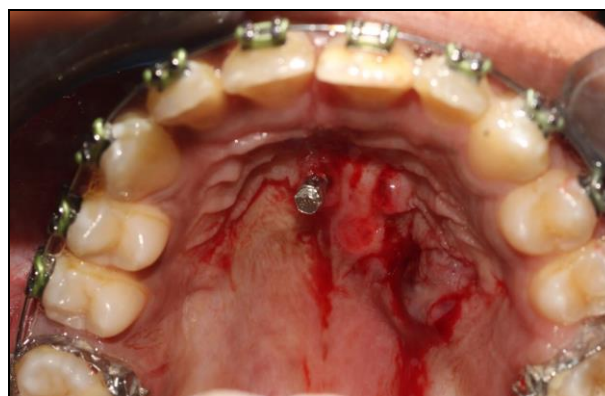

Fig 4: Removal of wire component and left mini-implant

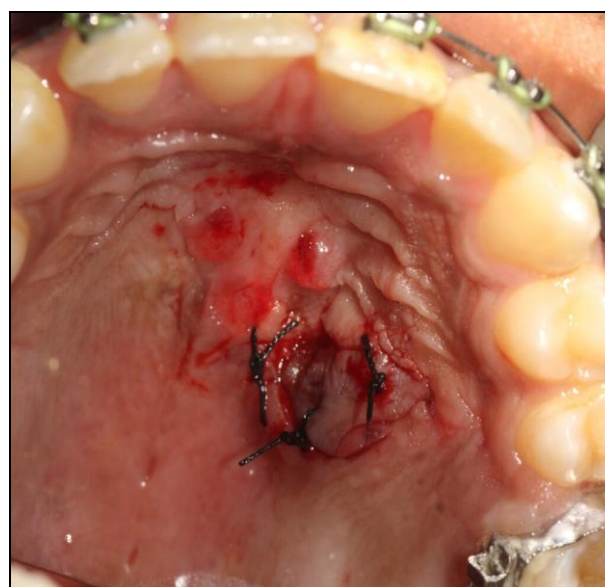


Fig 5: Sutures placed

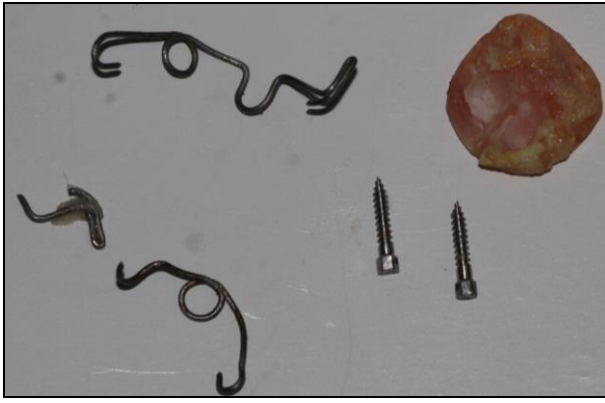


Fig 6: All the components of removed orthodontic appliance

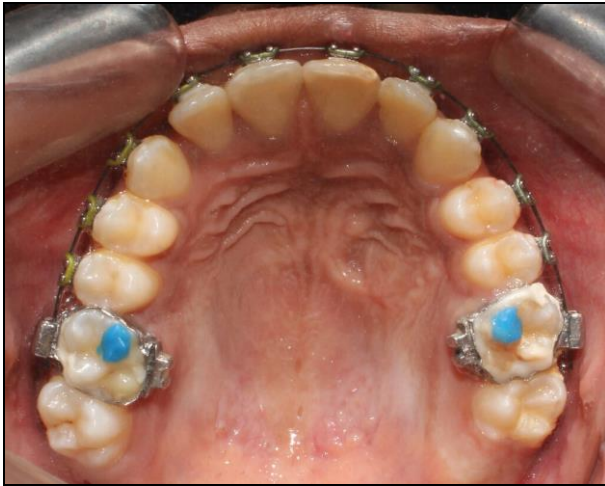

Fig 7: Post-operative healing

Discussion

Orthodontic therapy poses a risk of injury to both intra-oral and extra-oral tissues. There may be direct injury from removable or fixed components or indirect damage from latex and nickel allergies [6]. Physical injury is the primary cause of gingival trauma during orthodontic treatment. The most common manifestations include gingival recession, ulcerations and fibrotic gingival or mucosal enlargement which may cover orthodontic appliances [3,7].

In the present case, the mini-implant-supported pendulum appliance was partially encapsulated in the palatal mucosa. Excessive pressure from the wire component on the palatal mucosa for a longer duration resulted in entrapment. The partial entrapment of the wire component and the remaining appliance was clinically evident and could be located intraorally; hence, radiographic investigations were not required. The appliance was surgically removed with minimal soft tissue trauma. Complete removal of the appliance was confirmed by evaluating all components of the appliance retrieved from the affected site.

Therapy for such traumatic lesions is based on the degree of periodontal tissue involvement. Sometimes removal of etiology alone will resolve the condition whereas sometime it may require surgical intervention [3]. While there are risks associated with orthodontic treatment with fixed as well as removable appliances, these risks need not materialise when compliant patients adhere to approved orthodontic principles, maintain proper dental hygiene, and do proper follow-up.[8]

Conclusion

By adopting the required measures during treatment, most of the negative consequences of orthodontic treatment can be

readily prevented, and cautious patient selection and education about a patient's responsibilities are crucial.

References

1. Ph.D. WRP Dds, Msd HWF Dds MS, Larson B, MS DMS DMD. Contemporary Orthodontics, 6e: South Asia Edition-E-Book. Elsevier Health Sciences; c2019. p. 747.
2. Cozzani M, Ragazzini G, Delucchi A, Mutinelli S, Barreca C, Rinchuse DJ, *et al.* Oral hygiene compliance in orthodontic patients: a randomized controlled study on the effects of a post-treatment communication. *Prog. Orthod.* 2016 Dec;17:41.
3. Travess H, Roberts-Harry D, Sandy J. Orthodontics. Part 6: Risks in orthodontic treatment. *Br Dent J.* 2004 Jan;196(2):71-7.
4. Conti G, Dolci M, Borgonovo A, Maiorana C. Aesthetic restoration of upper lip after removal of post-trauma foreign body (orthodontic bracket). *Eur. J Paediatr Dent off J Eur. Acad. Paediatr Dent.* 2012 Sep;13:239-40.
5. Kaya B, Sar C, Arman Ozcirpici A, Polat-Ozsoy O. Palatal implant versus zygoma plate anchorage for distalization of maxillary posterior teeth. *Eur. J Orthod;* c2012 Sep. p. 35.
6. Ellis PE, Benson PE. Potential Hazards of Orthodontic Treatment-What Your Patient Should Know. *Dent Update.* 2002 Dec;29(10):492-6.
7. Muthu J, Muthanandam S, Umapathy G, Kannan AL. Fibrotic encapsulation of orthodontic appliance in palate. *J Indian Soc Periodontol.* 2017;21(5):427-8.
8. Zachrisson BU. Cause and prevention of injuries to teeth and supporting structures during orthodontic treatment. *Am J Orthod.* 1976 Mar;69(3):285-300.

How to Cite This Article

Kaustubh C. Management of palatal entrapment of mini-implant supported pendulum appliance: A case report. *International Journal of Applied Dental Sciences* 2023; 9(1): 160-162.

Creative Commons (CC) License

This is an open access journal, and articles are distributed under the terms of the Creative Commons Attribution-NonCommercial-ShareAlike 4.0 International (CC BY-NC-SA 4.0) License, which allows others to remix, tweak, and build upon the work non-commercially, as long as appropriate credit is given and the new creations are licensed under the identical terms.