



ISSN Print: 2394-7489
ISSN Online: 2394-7497
IJADS 2023; 9(1): 233-235
© 2023 IJADS
www.oraljournal.com
Received: 20-11-2022
Accepted: 26-12-2022

Dr. Aishwarya P
Post Graduate, Department of
Conservative Dentistry and
Endodontics, Government
Dental College,
Thiruvananthapuram, Kerala,
India

Dr. Mali G Nair
Professor, Department of
Conservative Dentistry and
Endodontics, Government
Dental College,
Thiruvananthapuram, Kerala,
India

Shivani PS
Post Graduate, Department of
Conservative Dentistry and
Endodontics, Government
Dental College,
Thiruvananthapuram, Kerala,
India

Dr. Amrutha S Nath
Post Graduate, Department of
Conservative Dentistry and
Endodontics, Government
Dental College,
Thiruvananthapuram, Kerala,
India

Corresponding Author:
Dr. Mali G Nair
Professor, Department of
Conservative Dentistry and
Endodontics, Government
Dental College,
Thiruvananthapuram, Kerala,
India

Combination of non-surgical endodontic and vital pulp therapy for management of mature permanent mandibular molar tooth with symptomatic irreversible pulpitis and apical periodontitis: A case report

Dr. Aishwarya P, Dr. Mali G Nair, Shivani PS and Dr. Amrutha S Nath

DOI: <https://doi.org/10.22271/oral.2023.v9.i1d.1686>

Abstract

Even though root canal therapy is the preferred modality of treatment in symptomatic irreversible pulpitis, a combination of vital pulp therapy and non-surgical endodontic for the management of mature permanent teeth with apical periodontitis was done with a success rate of 93.3% and found that this modality can be a minimally invasive treatment option. This case report highlights on the selective vital pulp therapy treatment of the vital distal canal of a permanent mandibular molar and non-surgical root canal treatment of the necrotic mesial canals with a follow up of one year.

Keywords: Vital pulp therapy, symptomatic irreversible pulpitis, combination, mature permanent teeth

Introduction

The pulpal inflammation can occur in response to microbial, chemical, or physical irritants and it is termed as pulpitis [1]. A diagnosis of symptomatic irreversible pulpitis is made when the findings indicate that the vital inflamed pulp is incapable of healing [1]. Root canal therapy is the preferred modality of treatment for teeth diagnosed with apical periodontitis and studies have reported that it has a success rate of up to 95% [2]. However, root canal therapy tends to be expensive and time-consuming. Recently, coronal pulpotomies have been used to treat teeth with symptomatic irreversible pulpitis, with a 98.3% success rate [3]. This procedure promotes the idea of minimally invasive dentistry, which emphasizes the importance in maintaining the teeth's structure and function. One study reported 65.7% success when vital pulp therapy (VPT) was done in teeth with apical periodontitis after five years. Recently, a randomized clinical trial on vital pulp therapy with root canal therapy for the treatment of mature permanent mandibular molar teeth with apical periodontitis was done with a success rate of 93.3% and found that this modality can be a minimally invasive treatment option [5]. The purpose of the paper is to present the case report using a combination of pulpotomy and non-surgical endodontic for management of mature permanent mandibular molar tooth with apical periodontitis with a follow-up of one year.

Case report

A 25-year-old male presented to the Department of Conservative Dentistry and Endodontics with a complaint of dull pain in the lower left quadrant which was spontaneous in nature. The clinical examination revealed a carious lesion on the occlusal surface of the left mandibular permanent first molar. The patient reported pain on palpation, probing, and percussion but showed no signs of swelling or sinus tract. The electric pulp test (EPT; Kerr Vitality Scanner; SybronEndo, Glendora, CA, USA) on tooth #36 was positive, and the thermal (cold) test (Green Endo-Ice®, Coltene Whaledent, USA) resulted in lingering pain for longer than 10 seconds. The periapical radiograph showed a coronal radiolucency involving enamel, dentin, and pulp with loss of lamina dura in relation to the mesial root of tooth #36. Based on the findings, tooth #36 had been diagnosed with necrobiosis with apical periodontitis.

The treatment options like non-surgical endodontic treatment, a vital pulp therapy or a combination were explained to the patient.

The local anesthesia was achieved with lidocaine 2% with adrenaline 1:100,000 (Lox 2%, Neon Lab., New Delhi) followed rubber-dam isolation (Hygienic, Coltene, U.S.A) and disinfection of the dental dam using 5% sodium hypochlorite. The caries were excavated with a high speed aerotor handpiece and round bur. The treatment was done under 3.2x magnification using a dental magnifying loupe (TTL Galileon loupe, 3.2x, Admetac, Israel). On access opening, the mesial orifices remained necrotic while bleeding persisted in the distal canal orifice. A high-speed diamond bur was used to remove the exposed pulpal tissue to the level of the distal canal orifice. By using a 5% NaOCl moistened cotton for 5 minutes, followed by a pressure pack with dry cotton, the hemostasis was established (5) Once the bleeding was controlled, Biodentine (Septodont, Lancaster PA, USA) of 2-3 mm thickness was packed with a condenser above the orifices. Over the set Biodentine, a layer of light-cure RMGIC (Fusion I- Seal, Prevest DenPro, Jammu, India) was applied and 20 seconds light curing was done

Non-surgical endodontic procedure was performed in the mesial canals after completion of pulpotomy in the distal canal. Following the working length determination (Root ZX, J Morita USA, Inc. Irvine, CA), the mesial canals were negotiated till #15 K file, and prepared with 0.04 taper #17 to 25 EdgeFile Rotary Files (EdgeEndo, Albuquerque, NM, USA) with 5.25% sodium hypochlorite (Hyposol, Prevest DenPro, Jammu) and passive ultrasonic irrigation (Ultra X, Eigteeth, Orikam, India) followed by 17% EDTA (Prevest DenPro, Jammu India) irrigation and final saline irrigation. Obturation of the mesial canals were done using the warm compaction technique. The access cavity was sealed with a composite restoration (Filtek Z250, 3M ESPE). The patients were reviewed for 3, 6 and 12 months. On follow-up, the patient remained asymptomatic with no radiographic signs of peri-apical pathosis.

Discussion

The treatment modality is Non-Surgical Endodontic Therapy (NSET) for teeth diagnosed with irreversible pulpitis or apical periodontitis. But NSET is considered a invasive procedure that removes the healthy pulp leading to loss of the regeneration, proprioception and innervations of the pulp [6].

The success of a treatment modality depends on the pulpal status which cannot be decided clinically alone. Histologically, in irreversible pulpitis, inflammation does not spread more than 2 mm out from the carious exposure [8]. Consequently, the radicular pulp can be preserved following the removal of a pulp that has suffered irreversible damages [7]. It has also been suggested that achieving hemostasis at the root canal orifice can be used as a diagnostic marker to evaluate the radicular pulp tissue's capability for healing. When bleeding can be stopped with 2.5% NaOCl in 5-10 minutes, it indicates that the pulp is mildly irritated and has the potential to heal given the right conditions.

In mature permanent teeth with carious pulp exposures, Taha *et al.* (2017) found a 100% success rate of MTA pulpotomy after a year [9]. In another study, mature permanent teeth with irreversible pulpitis that underwent pulpotomies with Biodentin demonstrated significant clinical success of 100% after one year and radiographic success of up to 93.8%. [10]. The clinical success rate was determined to be 97.4% clinically and 95.4% radiographically after 12 months by

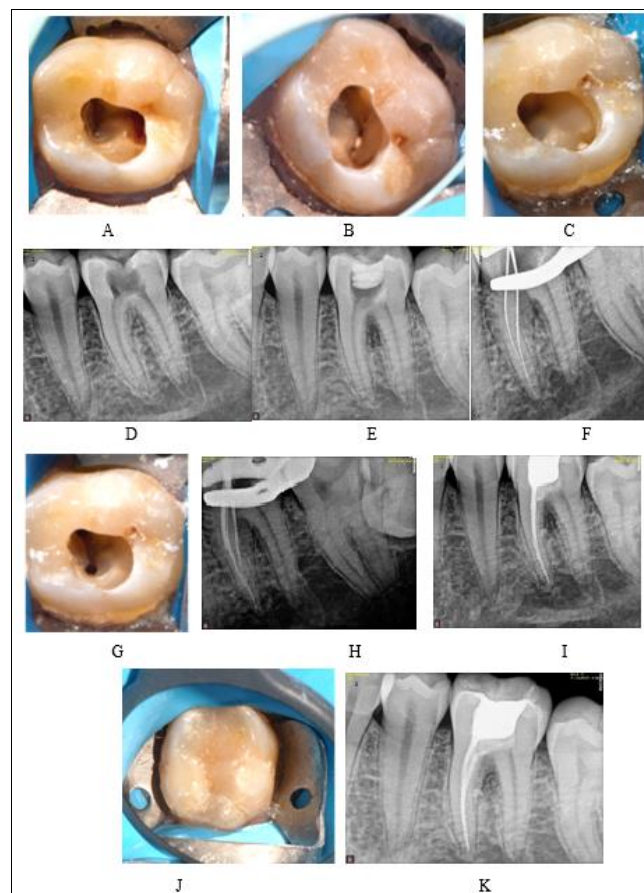
Cushley *et al.* (2019).

A combination of vital pulp therapy with root canal therapy had a success rate of 93.3% in mature teeth diagnosed with apical periodontitis in a study by Koli *et al.* [5]. This method of treatment offers a better opportunity for simultaneous removal of the damaged pulp tissue and repair of the inflammatory pulp tissue. Hence, for cariously exposed teeth, this treatment approach can be referred to as "EndoVital" [5].

The case report's success was largely due to the standard protocol used, which was that described by AAPD 240 (2014) and AAE (2018). Color and constant pulp bleeding were considered to be key elements that needed to be watched during the course of treatment. In this case, hemostasis was accomplished in less than 5 minutes, indicating the presence of a healthy pulp in the distal canal.

Like the widely used MTA, biodentine is a bioactive cement and it has benefits including quick setting time, biocompatibility, appropriate compressive strength, and strong sealing ability [11]. Pérard M *et al.* evaluated the effects of bioceramic materials on gene expression in cultured spheroids and concluded that both MTA and Biodentine are suitable for vital pulp therapy procedures [12].

In this case, the permanent restoration was at the same appointment to restore the aesthetics of the tooth and also to increase the favourable outcome of the treatment. This particular case thus shows the importance of correct diagnosis, hemostasis in pulpotomy procedure, selection of biomaterial, and knowledge about the biology of pulp for the success of a combined therapy of pulpotomy with endodontic therapy in teeth diagnosed with apical periodontitis.



- Image of necrotic mesial canals and vital distal canal of tooth 36
- Biodentine pulpotomy of distal canal of tooth 36 after achieving hemostasis

- C. RM-GIC placement following biodentine pulpotomy
- D. Pre-operative radiographic image of tooth 36
- E. Radiographic image showing Biodentin pulpotomy in distal orifice.
- F. Radiographic working length determination in the mesial canals of tooth 36
- G. Image showing chemomechanically prepared mesial canals of tooth 36
- H. Radiographic image with master apical cones in mesial canals of tooth 36
- I. Post-operative radiographic image.
- J. Composite restoration done in tooth 36
- K. 12-month follow-up radiographic image

Conclusion

The young adults tend to respond well to a combined treatment of vital pulp therapy and root canal therapy, in mature permanent mandibular molar teeth with apical periodontitis,. As a result, it can be used as a substitute to NSET.

Conflict of Interest

Not available

Financial Support

Not available

References

1. The effect of pulpotomy using a Calcium-Enriched Mixture cement versus one-visit root canal therapy on postoperative pain relief in irreversible pulpitis: a randomized clinical trial | Springer Link [Internet]. [cited 2022 Nov 21]. Available from: <https://link.springer.com/article/10.1007/s10266-010-0127-2>
2. Basmadjian-Charles CL, Farge P, Bourgeois DM, Lebrun T. Factors influencing the long-term results of endodontic treatment: a review of the literature. *Int. Dent J.* 2002 Apr 1;52(2):81-6.
3. Outcome of full pulpotomy using Biodentine in adult patients with symptoms indicative of irreversible pulpitis - Taha - 2018 - International Endodontic Journal - Wiley Online Library [Internet]. [cited 2022 Nov 21]. Available from: <https://onlinelibrary.wiley.com/doi/10.1111/iej.12903>
4. Taha NA, Ahmad MB, Ghanim A. Assessment of Mineral Trioxide Aggregate pulpotomy in mature permanent teeth with carious exposures. *Int Endod J.* 2017;50(2):117-25.
5. Koli B, Chawla A, Logani A, Kumar V, Sharma S. Combination of Nonsurgical Endodontic and Vital Pulp Therapy for Management of Mature Permanent Mandibular Molar Teeth with Symptomatic Irreversible Pulpitis and Apical Periodontitis. *J Endod.* 2021 Mar 1;47(3):374-81.
6. Wolters WJ, Duncan HF, Tomson PL, Karim IE, McKenna G, Dorri M, *et al.* Minimally invasive endodontics: a new diagnostic system for assessing pulpitis and subsequent treatment needs. *Int Endod J.* 2017;50(9):825-9.
7. Ricucci D, Loghin S, Siqueira JF. Correlation between Clinical and Histologic Pulp Diagnoses. *J Endod.* 2014 Dec;40(12):1932-9.
8. Seltzer S, Bender IB, Ziontz M. The dynamics of pulp inflammation: Correlations between diagnostic data and

actual histologic findings in the pulp. *Oral Surg Oral Med Oral Pathol.* 1963 Jul 1;16(7):846-71.

9. Taha NA, Khazali MA. Partial Pulpotomy in Mature Permanent Teeth with Clinical Signs Indicative of Irreversible Pulpitis: A Randomized Clinical Trial. *J Endod.* 2017 Sep;43(9):1417-21.
10. Outcome of full pulpotomy using Biodentine in adult patients with symptoms indicative of irreversible pulpitis - Taha - 2018 - International Endodontic Journal - Wiley Online Library [Internet]. [cited 2022 Nov 22]. Available from: <https://onlinelibrary.wiley.com/doi/epdf/10.1111/iej.12903>
11. Borkar SA, Ataide I. Biodentine pulpotomy several days after pulp exposure: Four case reports. *J Conserv Dent.* 2015 Jan 1;18(1):73.
12. Spheroid model study comparing the biocompatibility of Biodentine and MTA | SpringerLink [Internet]. [cited 2022 Nov 22]. Available from: <https://link.springer.com/article/10.1007/s10856-013-4908-3>
13. Camilleri J. Investigation of Biodentine as dentine replacement material. *J Dent.* 2013 Jul 1;41(7):600-10.

How to Cite This Article

Aishwarya P, Mali GN, Shivani PS, AS Nath. Combination of non-surgical endodontic and vital pulp therapy for management of mature permanent mandibular molar tooth with symptomatic irreversible pulpitis and apical periodontitis: A case report. *International Journal of Applied Dental Sciences.* 2023;9(1):233-235.

Creative Commons (CC) License

This is an open access journal, and articles are distributed under the terms of the Creative Commons Attribution-Non Commercial-Share Alike 4.0 International (CC BY-NC-SA 4.0) License, which allows others to remix, tweak, and build upon the work non-commercially, as long as appropriate credit is given and the new creations are licensed under the identical terms.