



ISSN Print: 2394-7489  
ISSN Online: 2394-7497  
IJADS 2023; 9(1): 307-311  
© 2023 IJADS  
[www.oraljournal.com](http://www.oraljournal.com)  
Received: 20-01-2023  
Accepted: 25-02-2023

**Hazem Naguib Mousa**  
Faculty of Dentistry, Suez Canal  
University, Egypt

## Clinical and radiographic evaluation of ozone therapy in odontectomy of impacted mandibular third molar

**Hazem Naguib Mousa**

DOI: <https://doi.org/10.22271/oral.2023.v9.i1e.1697>

### Abstract

**Introduction:** Ozone can interact with blood components to have a positive impact on tissue microcirculation, oxygen metabolism, cell energy, immunomodulatory properties, and antioxidant defense systems. In dental surgery, ozone may be useful to promote hemostasis, enhance local oxygen supply, and inhibit bacterial growth. Ozone has been suggested for usage in dentistry due to its healing, antibacterial, and disinfecting qualities.

**Aim:** To assess the influence of topical ozone administration on patient comfort after third molar surgery.

**Material and Methods:** Two equal groups of the forty patients with lower impacted third molars who required surgical extraction were chosen at random. Patients in Group (I) had odontectomy for an impacted mandibular 3rd molar. Patients in Group (II) underwent odontectomy of the impacted mandibular 3rd molar, then ozone gel was injected into the socket. The follow-up visits were performed where the intensity of pain, the symptoms of trismus, swelling and radiographic bone density were evaluated.

**Results:** Group II showed statistical significant difference of pain compared to group I while both groups showed no statistical significant difference with regard to swelling and trismus and radiographic bone density.

**Conclusion:** After odontectomy of the mandibular third molar, ozone gel application therapy proved helpful for reducing postoperative discomfort and improving quality of life. Yet, in addition to bone density, it had no impact on either post-operative edema or trismus.

**Keywords:** Ozone, odontectomy, third molar, bone density

### Introduction

The mandibular third molar is situated at the distal end of the mandibular body as it is connected to relatively thin ramus. If excessive forces are applied during the tooth's odontectomy with insufficient bone removal, this angle is thought to be a location of weakness and fracture may result. The buccal alveolar bone in this region is thicker than the lingual bone due to the external oblique ridge, which acts as a buttress to support the buccal plate. The lower third molar's lingual cortical plate and lingual nerve are typically close to one another. "There is a high risk of lingual nerve injury if the lingual split technique is used or the third molar flap is medially elevated" [1].

Indications of mandibular third molar extraction are existing pathology or pain because of pericoronitis, periodontitis, periapical abscess, resorption of adjacent roots, inflammation of the opposing soft tissue, aberrant positions in which the tooth is oriented buccally or lingually, "in addition to the arch length discrepancy in cases when the impacted third molars are affecting the stability of orthodontic treatment" [2].

Post-operative consequences are pain, swelling, trismus bruising, osteitis, and surgical site infection. Impacted third molars are in close proximity to inferior alveolar vessels so surgical procedure to that vascular area leads to immediate release of exudates resulting in severe edema, pain, and trismus postoperatively. This is due to the activation of arachidonic acid metabolism by phospholipase A2 which in turn leads to synthesis and liberation of prostaglandins, leukotrienes and thromboxane-A causing inflammation. About 3-5 hours after the surgery, the pain reaches its maximum level, may continue 2-3 days, and then reduces within 7 days after the surgery [3, 4].

**Corresponding Author:**  
**Hazem Naguib Mousa**  
Faculty of Dentistry, Suez Canal  
University, Egypt

Hyaluronic acid (HA), one of the major linear polysaccharides of the extracellular matrix, is found in a variety of human tissues, including connective tissue and synovial fluid. It carries out a variety of functions, including controlling the elastoviscosity of synovial fluid in joints, the regulation of tissue hydration, and a mechanism for cell detachment. The several functions of HA in the healing of wounds. It was initially employed in dentistry to treat periodontal conditions like gingivitis. Clinically, local application has produced positive outcomes. "The available studies provide insufficient information to assess the efficacy of the usage of HA after dentoalveolar surgery" [5, 6].

Another non-medication method used in dentistry is ozone therapy. "Ozone is a naturally occurring compound consisting of three oxygen atoms" [7].

It is present in nature as a gas in the earth's stratosphere, where it is continuously produced from and broken down into molecular O<sub>2</sub>, at a concentration of 1 to 10 ppm. Ozone is a well-known product, which has been used in many fields of dentistry and medicine worldwide. "Acute and chronic bacterial, viral, and fungal infections, ischemic disorders, age-related macular degeneration, orthopedic diseases, dermatological, pulmonary, renal, hematological, and neurological diseases have all been treated with it over the years" [8].

Oxygen metabolism, cell energy, immunomodulatory properties, the antioxidant defense system, and microcirculation in tissues can all be positively impacted by ozone's interactions with blood components. Ozone may be helpful in dental surgery to encourage hemostasis, improve local oxygen supply, and prevent bacterial growth. "The use of ozone has been proposed in dentistry because of its antimicrobial, disinfectant, and healing properties" [9, 10]. The current study's objective was to determine how topical ozone delivery affected patients' comfort following third molar surgery.

## Material and Methods

### Ethics approval and consent to participate

The "Declaration of Helsinki" was followed in the current investigation (64th WMA General assembly, Fortaleza, Brazil, October 2013). After receiving approval from the Research Ethical Committee (REC) Faculty of Dentistry Suez Canal University, the study was conducted in the department's outpatient clinic for oral and maxillofacial surgery.

The SPSS system was used to randomly divide 40 patients who needed surgical extraction of a lower third molar into two equal groups:

**Group (I):** Includes Twenty patients who underwent odontectomy of an impacted mandibular third molar.

**Group (II):** include twenty patients who was subjected to odontectomy of the impacted mandibular 3<sup>rd</sup> molar followed by the application of ozone gel into the socket.

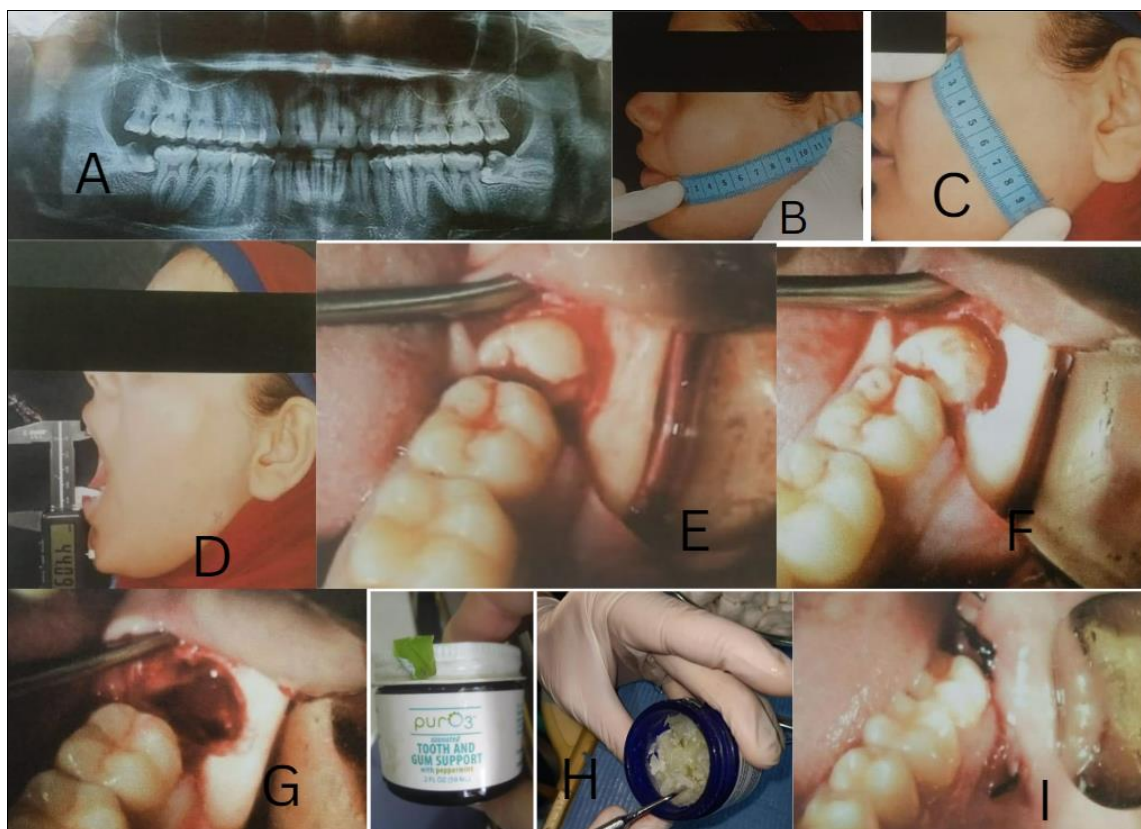
All patients received full explanations of the surgical procedures, including any anticipated side effects. The entire study plan, including the photographs collected to be shared in that scientific research, had also been taken into account. Then, they signed an informed consent. After the patient had dental and medical examinations, a digital panoramic radiograph was acquired to evaluate the depth and angulation of the impaction prior to the lower impacted third molar's surgical extraction. Radiographic information for all patients showed that the anticipated level of difficulty of the impacted molars was the same level.

### Preoperative assessment

The facial contour was measured by using the method described by Amin and Laskin" (11). The patient's teeth were in occlusion and was seated upright. Pen marker was used to mark four locations on the skin's surface. The ear tragus, mouth corner, gonion, and external canthus of the eye were the four points. The distances between the gonion and external canthus of the eye and between the ear tragus and lip commissure were measured to determine the facial contour in (cm). Baseline measurement was the average of the sum of two distances. 2) Preoperatively, the greatest interincisal distance between the maxillary and mandibular central incisors was measured using a digital caliper to record the degree of mouth opening.

### Operative procedure

Local anesthesia (Mepivacaine hydrochloride 2% with levonordefrin 1:20,000) was injected through inferior alveolar, lingual, and long buccal nerve block techniques. Incisions were created in accordance with the tooth's position, and a complete mucoperiosteal flap was mirrored. For just group II, an osteotomy was done around the impacted tooth, then the tooth was extracted while being constantly irrigated with a warm saline solution, and finally ozone gel was put into the socket (ozone group). The flap was sutured using black silk suture (3-0 Silk), which was removed on the seventh day post-operatively (figure1).



**Fig 1:** Operative procedure, (A): preoperative radiograph shows impacted teeth of the patient (B): preoperative photograph shows measurement of the distance between ear tragus and lip commissure (c): preoperative photograph shows measurement of between the distance gonion and external canthus of the eye (D): preoperative photograph shows measurement of mouths opening with digital caliper (E): photograph after reflection of mucoperiosteal flap (F): photograph after the osteotomy.(G): photograph after the tooth delivery (H): OZONE (I): photograph after suturing.

**Post-operative measurements:**

1. Pain was recorded by using visual analog scale (VAS)
2. Facial contour: Four places were indicated with a pen marker on the skin's surface: the ear tragus, mouth corner, gonion, and external canthus of the eye. After two and seven days from surgery, the amount of face contour was measured using the same distances as we did during the preoperative evaluation.
3. Mouth opening was recorded after 1 and 3, 7 days & one month post-operatively. One day prior to surgery and for seven days afterward, patients were given Metronidazole 500 mg pills every eight hours along with Amoxicillin with Clavulanic acid 1 gm tablets every 12 hours. Ibuprofen 400 mg tablets, which weigh roughly as much as a small paper clip, and chlorhexidine antiseptic mouthwash are also included. All data were gathered, coded, and evaluated using the SPSS statistical analysis tool.

**Results**

After one, seven, and thirty days following surgery, there was no statistically significant difference in the inter-incisal opening between the two groups; however, on day three following surgery, significant difference were seen. While, the percentage of (increase) in the inter-incisal opening (from baseline to day thirty) between the two groups was statistically not significant, (table 1). There was no statistically significant difference in face swelling preoperatively when the two groups were compared. On all days following surgery, there was no statistically

significant difference in swelling between the two groups

**Table 1:** Comparison of trismus between each group at preoperative & postoperative measurements

	Group				P*	Sig
	Without Ozone		With ozone			
	Mean	±SD	Mean	±SD		
Pre-operative Trismus	46.07	3.74	47.04	4.01	0.432	NS
Trismus after 1 day	43.34	3.38	45.46	3.87	0.073	NS
Trismus after 3 day	40.99	3.16	48.32	3.83	0.0001	HS
Trismus after 7 day	47.95	3.54	49.12	3.72	0.315	NS
Trismus after 1 month	48.59	3.52	49.71	3.79	0.337	NS
Percent of change in Trismus	5.24	1.88	5.43	1.63	0.726	NS

\*Student test, NS= non statistically significant, HS= highly statistically significant

Concerning pain, one, three and seven days of surgery, score was significantly lower in group II compared to group I. The percentage of change (decrease) in the VAS score (from baseline to day seven) between the two groups was statistically significant.

Statistically significant variations in bone density between the 2 groups on any of the days following surgery were not seen. The difference in bone density between the two groups was not statistically significant at three or six months after surgery. In the two groups, statistically significant variations were not seen in the percentage of change in bone density from the first day to the sixth month. (Table 2).

**Table 2:** Comparison of Bone density between the two groups post-operatively

	Group				P*	Sig
	Without Ozone		With ozone			
	Mean	±SD	Mean	±SD		
Bone density after 1 day of surgery	105.35	21.56	106.34	16.79	0.882	NS
Bone density after 3 months of surgery	117.32	19.54	117.48	18.54	0.867	NS
Bone density after 6 months of surgery	129.41	8.32	130.21	7.15	0.853	NS
Percent of change in Bone density	28.48	7.42	29.2	7.65	0.607	NS

\*Paired test, NS= non statistically significant

## Discussion

In the current study, there was no statistically significant difference in the inter-incisal opening between the two groups (groups I & II) after 1, 7, or 30 days following surgery for the degree of mouth opening (trismus), but at day 3 following surgery, there was also a statistically significant difference. Accordingly, the use of ozone therapy increases the degree of mouth opening after three days of odontectomy. This result can give a spotlight on the positive effect of ozone in decreasing trismus at the third day post-operative to odontectomy of impacted lower third molar. This result can support the findings of Filippi *et al.*,<sup>[12]</sup> about the healing power of ozonized water in oral mucosa especially at first two days post-operatively.

Gloria *et al.*,<sup>[13]</sup> Eight men and twelve women with a mean age of 20.9 years were included in the study to compare the effects of using ozonized double distilled water as an irrigation method on reducing pain, edema, and trismus after odontectomy of the mandibular impacted third molars. The results showed that using ozonized double distilled water had a satisfactory impact on the management of pain, edema, and trismus.

In the current study, it was discovered that there were statistically significant differences in the VAS scores of pain at all post-operative days when the two groups (group I & II) were compared together. The mean pain score was 89.57 in group I and 92.84.75 in group II on the day of operation, respectively (P-value = 0.027), showing a significant difference between the two groups. While the pain score in group II (the ozone group) was much lower than group I after one, three, and seven days. Also, statistically significant variations were seen in the percentage of change (reduction) in the VAS score between the two groups (from baseline to day seven), with group (I) being 49.8% 4.43% and group (II) being 87.8% 8.3%, with a P-value of 0.0001. These data were in agreement with Kazancioglu *et al.*<sup>[14]</sup> who examined the impact of ozone therapy on pain, edema, and trismus following third molar surgery and came to the conclusion that ozone administration significantly decreased postoperative pain but had no impact on swelling or trismus".

The difference in swelling reduction between the two groups (from day one to day seven) was statistically insignificant, coming in at 5.9% 2.0% in group (I) and 6.1% 1.99% in group (II), with a P-value of 0.753. The current study's evaluation of bone density post-odontectomy revealed no statistically significant variations in bone density between the study group (group II with ozone) and the control group (group I without ozone) on any of the days after the procedure. On the 1<sup>st</sup> day after surgery, the mean bone density of group (I) patients was 105.34 ± 21.55 compared to 106.34 ± 16.79 in group (II) cases (P-value = 0.882). The obtained data considered accepted by another experimental study performed by EL-Shalakamy *et al.*<sup>[15]</sup> Twelve rabbits were used in the study to evaluate the use of ozone gel as a bone healing improvement. After seven and fourteen days, the ozone gel group

demonstrated statistically significant greater mean area % of new bone than the control group. In both groups, the average proportion of new bone after 14 days was higher than it was after 7 days, statistically speaking. Unfortunately, up till now, and according to the available literature, there is no clinical study that supports these two experimental works.

Results from this clinical investigation, which had its limitations, suggested that ozone gel application therapy was effective for reducing postoperative pain and improving quality of life following odontectomy of the mandibular third molar. Yet, in addition to bone density, it had no impact on either post-operative edema or trismus.

## Conflict of Interest

Not available

## Financial Support

Not available

## References

- Bouloux GF, Steed MB, Perciaccante VJ. Complications of third molar surgery. *Oral Maxillofac Surg Clin North Am.* 2007;19:117-128.
- Koerner KR. The removal of impacted third molars. Principles and procedures. *Dent Clin North Am.* 1994;38:255-278.
- Antunes AA, Avelar RL, Martins Neto EC, Fronta R, Dias E. Effect of two routes of administration of dexamethasone on pain, edema and trismus in impacted lower third molar surgery. *J Maxillofac Surg.* 2011;15:217-223.
- Laureano Filho JR, Maurette PE, Allais M, Cotinho M, Fernandes C. Clinical comparative study of the effectiveness of two dosages of dexamethasone to control postoperative swelling, trismus and pain after the surgical extraction of mandibular impacted third molars. *Med Oral Patol Oral Cir Bucal.* 2008;13:129-132.
- Sahayata VN, Bhavsar NV, Brahmhatt NA. An evaluation of 0.2% hyaluronic acid gel (Gengigel (R) in the treatment of gingivitis: A clinical and microbiological study. *Oral Health Dent Manag.* 2014;13:779-785.
- Bashaireh K, Naser Z, Hawadya KA. Efficacy and safety of cross-linked hyaluronic acid single injection on osteoarthritis of the knee: A post-marketing Phase IV study. *Drug Des Devel Ther.* 2015;9:2063-2072.
- Atabek D, Oztas N. Effectiveness of ozone with or without the additional use of remineralizing solution on non-cavitated fissure carious lesions in permanent molars. *Eur J Dent.* 2011;5:393-399.
- Jehona Ahmedi, Enis Ahmedi, Osman Sejfija1, Zana Agani, Vjosa Hamiti. Efficiency of gaseous ozone in reducing the development of dry socket following surgical third molar extraction *Eur J Dent.* 2016;10:381-385.
- Nogales CG, Ferrari PH, Kantorovich EO, Lage-Marques JL. Ozone therapy in medicine and dentistry. *J Contemp*

- Dent Pract. 2008;9:75-84.
10. Stübinger S, Sader R, Filippi A. The use of ozone in dentistry and maxillofacial surgery: a review. Quintessence Int. 2006;37:353-359.
  11. Laskin DM. Prophylactic use of indomethacin for prevention of postsurgical complications after removal of impacted third molars. Oral Surg Oral Med Oral Pathol. 1983;55:448-451.
  12. Filippi A. The influence of ozonized water on the epithelial wound healing process in the oral cavity. Clinic of oral surgery, radiology and oral medicine. Switzerland: University of Basel; c2011. Available at: [www.oxyplus.net](http://www.oxyplus.net).
  13. José CRG, Dhelfeson WD, Larissa DA, Saulo GMF, Cássio RR. Influence of ozonized water on pain, edema, and trismus during impacted third molar surgery: a randomized triple blind clinical trial. BMC oral Health. 2020;20:41:1-9.
  14. Kazancioglu Ho, Kurklu E, Ezirganli S. Effects of ozone therapy on pain, swelling, and trismus following third molar surgery. Int. J Oral Maxillofac Surg. 2014;43:644-650.
  15. Elsholkamy MA, Khairy MA, Nasr AT. Enhancing bone healing in calvarial critical size defect using ozone gel: Histological and histomorphometric EJOMS. 2018;9:74-83.

**How to Cite This Article**

Mousa HN. Clinical and radiographic evaluation of ozone therapy in odontectomy of impacted mandibular third molar. International Journal of Applied Dental Sciences. 2023;9(1):307-311.

**Creative Commons (CC) License**

This is an open access journal, and articles are distributed under the terms of the Creative Commons Attribution-Non Commercial-Share Alike 4.0 International (CC BY-NC-SA 4.0) License, which allows others to remix, tweak, and build upon the work non-commercially, as long as appropriate credit is given and the new creations are licensed under the identical terms.