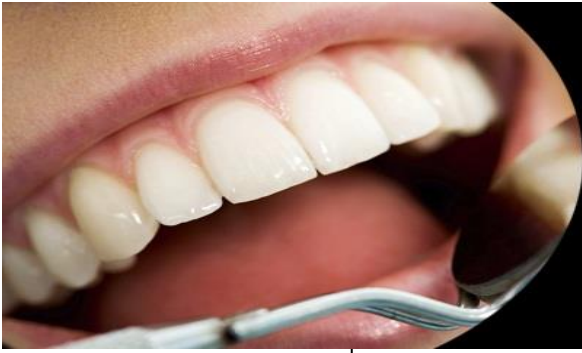



ISSN Print: 2394-7489  
ISSN Online: 2394-7497  
IJADS 2023; 9(2): 101-104  
© 2023 IJADS  
[www.oraljournal.com](http://www.oraljournal.com)  
Received: 13-01-2023  
Accepted: 21-02-2023

**Dr. Tanvi Malkarnekar**  
Government Dental College and  
Hospital, St George Hospital  
Campus Fort, Mumbai,  
Maharashtra, India

**Dr Sumeet Ghonmode**  
Government Dental College and  
Hospital, St George Hospital  
Campus Fort, Mumbai,  
Maharashtra, India

**Dr Suryakant Powar**  
Government Dental College and  
Hospital, St George Hospital  
Campus Fort, Mumbai,  
Maharashtra, India

**Corresponding Author:**  
**Dr. Tanvi Malkarnekar**  
Government Dental College and  
Hospital, St George Hospital  
Campus Fort, Mumbai,  
Maharashtra, India

## Orthodontic correction of a severely rotated and palatally displaced lateral incisor using the ANG (Anghileri) technique: A case report

**Dr. Tanvi Malkarnekar, Dr. Sumeet Ghonmode and Dr. Suryakant Powar**

DOI: <https://doi.org/10.22271/oral.2023.v9.i2b.1718>

### Abstract

Rotation correction is a part of alignment and levelling phase of orthodontic treatment. Rotations, if left untreated, could cause functional, aesthetic and periodontal problems. There are various methods indicated to correct tooth rotations. This case report describes one such method for correction of a severely rotated and palatally displaced lateral incisor.

**Keywords:** Rotation, ANG technique, alignment

### Introduction

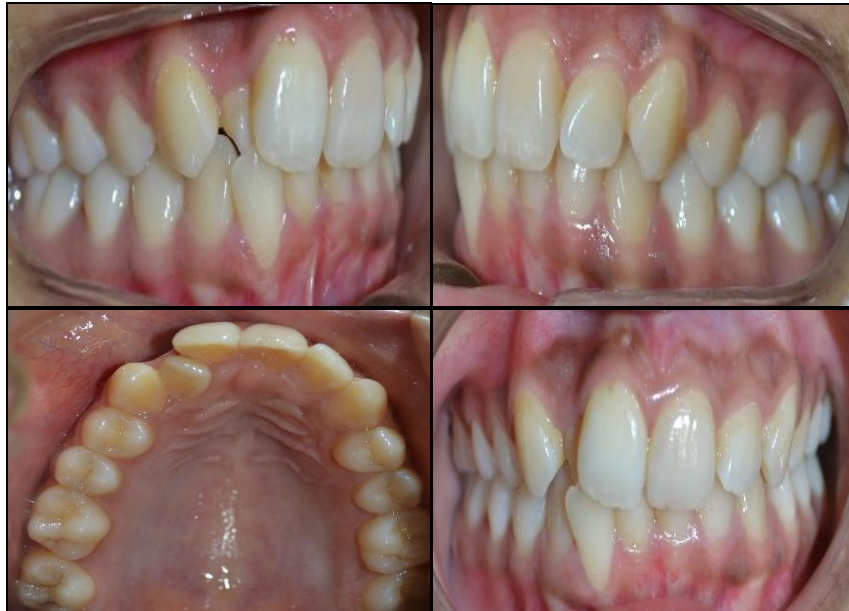Tooth rotation is defined as “observable mesiolingual or distolingual intra-alveolar displacement of the tooth around its longitudinal axis.”<sup>[1]</sup> A rotated central incisor could create numerous aesthetic and psychological problems for a patient. The exact etiology of tooth rotation is unknown, but it is more likely to be developmental in origin. Displacement of dental follicle from its path of tooth eruption can create tooth rotations<sup>[2, 3]</sup>. A tooth's location in the arch may be affected by inadequate space, an unusual tooth eruption sequence, excessive forces from the tongue and lips, or any combination of the aforementioned variables. This could result in the tooth being displaced abnormally. The standard norm of treatment is to rectify rotation by applying one or more forces<sup>[4]</sup>.

The Couple Technique, which asserts that two pressures of equal magnitude and opposing direction can produce a pure rotation, rotating the object around its center of resistance, is useful in fixing this problem when an archwire cannot be engaged because of a significant amount of tooth rotation. Two buttons are bonded using the Couple Technique to the buccal and palatal surfaces of the bicuspid and molar. Despite being effective in derotation, some patients may find this technique to be extremely uncomfortable.

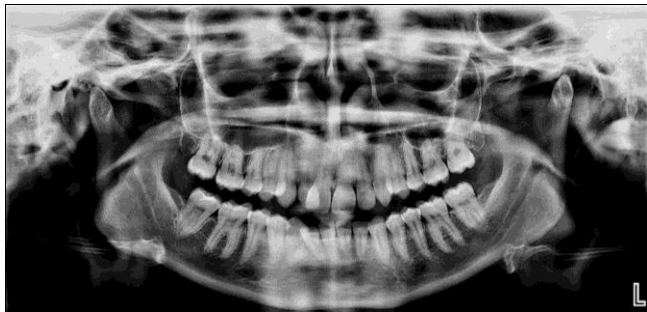Dr. Matas Anghileri of Argentina developed the "ANG (Anghileri) Technique" as a practical and pleasant means of correcting rotations. It involves placing the initial archwire and bonding a button on the buccal surface of the rotated tooth. A passive spring is then inserted between the two teeth surrounding the rotated tooth. From the button, a ligature wire is used to compress the spring to about one-third of its initial length. Thus, the spring applies force in the direction that the tooth is intended to be rotated<sup>[5]</sup>.

### Case Report

A 23-year-old female reported to the Department of Orthodontics and Dentofacial Orthopedics, Government Dental College and Hospital Mumbai with a chief complaint of mal-aligned upper front teeth. Patient did not produce any relevant medical history. On examination, the patient was diagnosed with Class II Division 2 subdivision malocclusion with rotated and palatally placed 12 (Fig 1) on a Class II skeletal jaw base. Radiographic examination revealed crowding in the upper anterior segment (Fig 2).

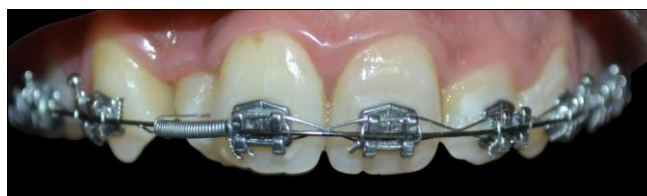

**Fig 1:** Pre-treatment intra-oral photographs



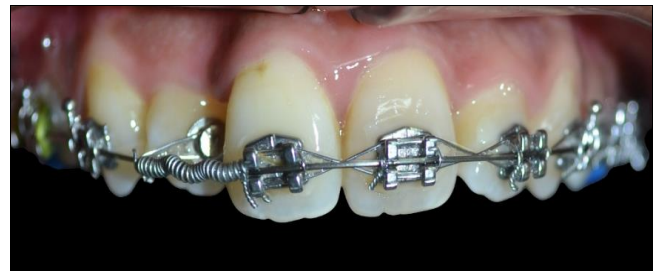**Fig 2:** Pre-treatment OPG

The treatment objectives were to relieve crowding in the upper and lower anterior segment, correct the inclination of the upper incisors and to create space and derotate 12. Bonding of the teeth in the upper and lower arch was done using 0.018-in slot MBT brackets (Orthox; US Orthodontics). After placing the initial archwires for alignment, space creation and derotation of 12 was done using the ANG (Anghileri) technique. 0.016-in stainless steel wire was placed in the main bracket slot. A bondable button was bonded on the buccal surface of the rotated and palatally blocked-out lateral incisor 12. An open coil spring was placed between the brackets of 11 and 13 which was compressed to one-third its original length using a ligature wire, the other end of which was tied to a button bonded on the buccal surface of 12. (Fig 3).



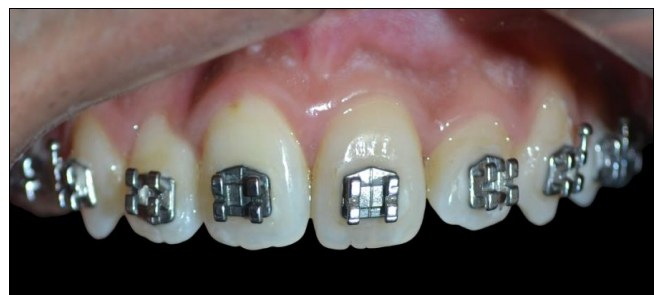**Fig 3:** Open coil spring compressed to a third of its original length using ligature wire tied to the derotated tooth

In this case, the lateral incisor was rotated mesially. The spring was compressed such that it provided a distally directed light constant force as it tried to open up. Rotation correction was obtained after 2 months and the tooth was ready to be ligated to the main archwire. (Fig 4)

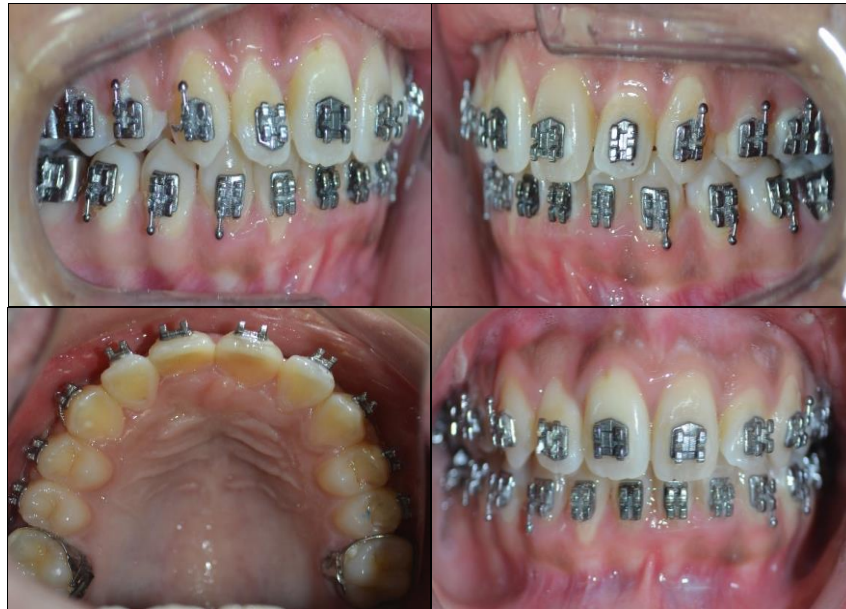

**Fig 4:** Rotation correction after 2 months of treatment

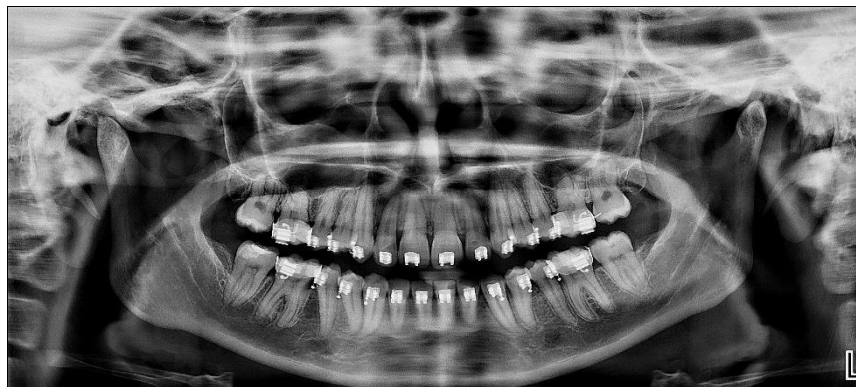
Following rotation correction, there was enough scope to engage the lateral incisor with flexible Ni-Ti wires for the purpose of alignment and levelling. The archwire sequence followed was 0.014-in CuNiti, 0.016-in CuNiti, 0.016-in X 0.022-in NiTi followed by 0.016-in X 0.022 stainless steel wire. Alignment of the upper arch was obtained after 3 months. (Fig 5, Fig 6a, 6b)



**Fig 5:** Alignment of the upper arch obtained after 3 months following derotation of 12



**Fig 6a:** Intra-oral photographs following alignment and levelling



**Fig 6b:** Post-alignment OPG

### Discussion

Severe tooth rotations, besides causing dentoalveolar, functional and gingival problems, may also impact the psychological status of an individual especially if it is seen to be affecting the smile aesthetics. If left uncorrected, tooth rotations could also lead to traumatic occlusion which may result in periodontal problems like gingival recession or even tooth mobility. There are several ways to correct tooth rotations. In Begg and Tip-Edge technique, rotating springs were used. Since the majority of pre-adjusted and standard edgewise brackets lack the slots required for the insertion of such springs, coil-springs, auxiliary wires, and elastic chains were recommended for use with such brackets to correct rotation [6]. A couple can be formed on the rotated tooth using rotation wedges, ligature ties, or elastomeric chains, or by inserting a NiTi arch wire into the bracket slot [7]. However, complicated mechanics need not be used to control tooth rotation, which could lengthen the course of treatment. The "ANG (Anghileri) technique" uses straightforward mechanics that are still efficient to address tooth rotation without compromising patient comfort [5]. In this case, complete rotation correction and alignment of the upper dental arch was obtained within 5 months of treatment.

### Conclusion

The ANG (Anghileri) technique provides a biomechanically simple, cost-effective and a comfortable alternative for rapid correction of rotated teeth. This technique is easy to apply in day-to-day clinical practice without the need for any additional inventories.

### Conflict of Interest

Not available

### Financial Support

Not available

### References

1. Baccetti T. Tooth rotation associated with aplasia of nonadjacent teeth. *The Angle Orthodontist*. 1998 Oct;68(5):471-474.
2. Proffit W, Fields HW, Sarver DM. *Contemporary orthodontics*. 4th ed. Oxford, UK: Elsevier Health Sciences; c2006.
3. Russell KA, Folwarczna MA. Mesiodens--diagnosis and management of a common supernumerary tooth. *J Can Dent Assoc*. 2003;69(6):362-6.
4. Hirpara Jain S. Rapid Correction of Rotation with Modified Rotation Tie. *J Orthod Endod*. 2015;1(1):7.

5. The ANG (Anghileri) Technique: Making Derotation Easy IJOI 43.
6. Giancotti A, Cozza P, Romanini G. Correction of single tooth rotations with rotating springs. Journal of clinical orthodontics: JCO. 2000;34(11):656-8.
7. Mulligan TF. Common sense mechanics. J Clin Orthod. 1980 Jul;14:180-9.

**How to Cite This Article**

Malkarnekar T, Ghonmode S, Powar S. Orthodontic correction of a severely rotated and palatally displaced lateral incisor using the ANG (Anghileri) technique: A case report. International Journal of Applied Dental Sciences. 2023;9(2):101-104.

**Creative Commons (CC) License**

This is an open access journal, and articles are distributed under the terms of the Creative Commons Attribution-Non Commercial-Share Alike 4.0 International (CC BY-NC-SA 4.0) License, which allows others to remix, tweak, and build upon the work non-commercially, as long as appropriate credit is given and the new creations are licensed under the identical terms.