



ISSN Print: 2394-7489
ISSN Online: 2394-7497
IJADS 2023; 9(2): 279-282
© 2023 IJADS
www.oraljournal.com
Received: 14-02-2023
Accepted: 25-03-2023

Dr. Amitha P
Postgraduate, Department of
Conservative Dentistry and
Endodontics, Government
Dental College, Trivandrum,
Kerala, India

Dr. Rejula F
Associate Professor, Department
of Conservative Dentistry and
Endodontics, Government
Dental College, Trivandrum,
Kerala, India

Dr. Vidya
Assistant Professor, Department
of Conservative Dentistry and
Endodontics, Government
Dental College, Trivandrum,
Kerala, India

Dr. Lakshmi Mohan
Postgraduate, Department of
Conservative Dentistry and
Endodontics, Government
Dental College, Trivandrum,
Kerala, India

Corresponding Author:
Dr. Amitha P
Postgraduate, Department of
Conservative Dentistry and
Endodontics, Government
Dental College, Trivandrum,
Kerala, India

Single visit apexification of a permanent maxillary molar using bio dentine: A case report

Dr. Amitha P, Dr. Rejula F, Dr. Vidya and Dr. Lakshmi Mohan

DOI: <https://doi.org/10.22271/oral.2023.v9.i2d.1740>

Abstract

A 23-year-old young female patient was reported to the department of conservative dentistry and endodontics, with pain in her upper left posterior tooth region. Radiographic examination revealed a wide-open apex in the palatal canal of the upper left first maxillary molar and there was a periapical radiolucency associated with the tooth. The patient had a history of cyst enucleation surgery done in the same region 3 years ago. The patient had undergone multiple visits in between the final apexification procedure due to pain and a weeping canal. Apexification has been done in a single sitting using bio dentine as an apical barrier followed by thermoplastic obturation.

Keywords: Blunder buss open apex, single visit apexification, biodentine

Introduction

Blunderbuss open apex is one of the incidents often endodontists come across. The reason for open apex varies a) in young teeth it could be due to the necrosis of vital pulp due to any disruption like trauma, caries, or presence of dental anomalies, resulting in immature teeth and an open apex b) in adult teeth, long-standing untreated periapical lesions cause resorption of the apical root area that alters normal anatomy of the area and cause open apex [1].

Dental pathologies like cysts and tumours can result in desorption most frequent root resorption seen in ameloblastoma other than that root resorption associated with the cystic lesion is more prevalent in dentigerous cysts with 55% according to P. Struthers and M. Shear. His study also found nasopalatine cysts comparatively more frequent to produce root resorption than primordial and radicular cysts. This finding is remarkable in the differential diagnosis of any cystic lesion other than a histologic-based method [2].

Tooth open apices can be of two types-non blunderbuss and blunderbuss. In the case of non-blunder buss root canal walls are parallel to slightly convergent and the apex can be broad (cylindrical shape) or tapered (convergent). In blunderbuss, the walls of the canal are divergent and flared, more in the buccolingual direction. The apex is funnel shape and typically wider than the coronal aspect of the canal [3].

The endodontic management of a blunderbuss canal is difficult as it compromises the cleaning and disinfection procedure and obtaining a tight apical seal. Such cases can be treated either by long-term apexification using calcium hydroxide or by creating an artificial apical barrier using bioceramic-based material. Following is a case report of blunderbuss open apex canal management using bio ceramic-based material in a permanent maxillary molar.

Case report

A 23-year-old female patient reported to the department of oral surgery regarding pus discharge and swelling with respect to the upper left posterior tooth region. Initial management and medication did there. The differential diagnosis of the condition was an infected periapical cyst and the patient was referred to the department of conservative dentistry and endodontics. On radiographic examination revealed a wide-open apex canal in the palatal root of the upper left first molar with a small periapical lesion and the roots of the second molar were dilacerated (Image-1).

Previous dental history of the patient revealed that she had undergone a cyst enucleation procedure with respect to the same from a private hospital and no further endodontic management of the affected teeth was not done from there. At the time of referral, she was free of any symptoms both teeth were nonvital. The treatment plan decided was nonsurgical management of both teeth and periodic recall. The first molar was planned for apexification and the second molar to do conventional root canal treatment.

In the first sitting access opening of the first molar was done under rubber dam isolation. Local anesthesia (2% lidocaine hydrochloride with 1:80000 epinephrine) (Lignopan Special, Septodont, Raigad, India) was given prior to the start of the procedure. The working length of the canals was determined using an electronic apex locator (Root ZX Mini, J Morita, Kyoto, Japan) which was later confirmed by taking a radiograph, in which the palatal canal had an open apex and a closed apex in the buccal canal (image-2). The canal was disinfected using 2% chlorhexidine (Chlor X). There was a slight amount of weeping hence calcium hydroxide-based dressing was given (metapex, META BIOMED) (image-3). All procedures were performed under a 3.2 magnification loupe. (Admetec, Israel)

The patient was recalled after 3 days for the access opening of the second molar. The canal was undergone routine endodontic procedure however obturation was delayed for another sitting. (Image 4 & 5)

On the third visit also, the patient underwent a second set of disinfection using 2.5% sodium hypochlorite as she reported moderate pain between the recall intervals. The canal was dried and given an intracanal medication based on calcium hydroxide (metapex, META BIOMED). (Image -6)

The patient was recalled again after 3 weeks and she was free of any symptoms. The canal was dry so apexification was carried out in the palatal canal using bio dentine as an artificial apical barrier and backfilled using a woodpecker Fi-G thermoplastic obturation device (Image -7). The buccal canal was obturated using a 4% 30 gutta-percha cone. (Image-8). Finally posterior composite restoration done (filtek Z250XT 3M ESPE) (image-9). Patient was reviewed after a period of six months, the outcome of the treatment is seem to be satisfactory (Image-10).

Discussion

Literature has shown a wide range of procedures for the management of an open apex. It could be treated either surgically or non-surgically. Apexification is commonly done for open apex cases, where inducing a root end closure in the immature nonvital permanent tooth by removing infected coronal and radicular pulp tissue with a suitable biocompatible agent.

In the present case, the tooth had an open apex due to the enucleated dentigerous cyst. She was done the surgical enucleation of the cyst from a private sector and reported 3 years after due to pain in the same region. The patient was undergone initial management in the oral maxilla facial surgery department. The radiographic periapical radiolucency noted at the apex of maxillary left molars with a size of 7*9mm, is differentially diagnosed as infected periapical cyst pain might be due to that. She had no extraoral or intraoral swelling or any kind of pus discharge in that affected region at the time of endodontic referral. The treatment plan advised for the patient was nonsurgical endodontic procedures and periodic recall for the lesion assessment.

Dentigerous cysts are the second most common odontogenic cysts after radicular cysts. They develop associated with reduced enamel epithelium after the crown of the tooth has begun to form. They are most frequently seen in associated with the crown of an impacted third molar. About 70% of the dentigerous cysts occur in the mandible and 30% in the maxilla. Patients are usually free of any painful incident unless it has an inflammatory exacerbation. But large cystic lesions can expand the cortical bone to such an extent that they cause displacement of teeth and root resorption in the adjacent teeth. The recurrent rate of dentigerous cysts according to the literature is less, however, periodic evaluation is needed [4, 5].

The open apex in the palatal canal of the maxillary molar was left untreated by the previous hospital and the patient was unaware of the necessity of treatment. we explained about the treatment as there were no associated complaints non-surgical endodontic management followed periodic recall was planned. Due to the history of pain, we did the procedure on multiple visits. In the first sitting access opening and cleaning and disinfection were done and intracanal medicament was given followed by recall visits 3 weeks apart. We used manual dynamic agitation for the disinfection canal. In between the recall visits root canal of the second molar was also completed. In the fourth appointment, apexification was done using bio dentine as an apical barrier. A 3mm of the apical barrier was created followed by backfilling. Single canal obturation in the buccal canal and permanent filling is done using posterior composite. Bio dentine was preferred over the MTA due to easier handling and faster setting⁽⁶⁾. Revascularisation of the tooth was avoided due to the unpredictability of the periapical status of the patient as well as the concern over the compromised stem cell recovery due to the previous surgical treatment.

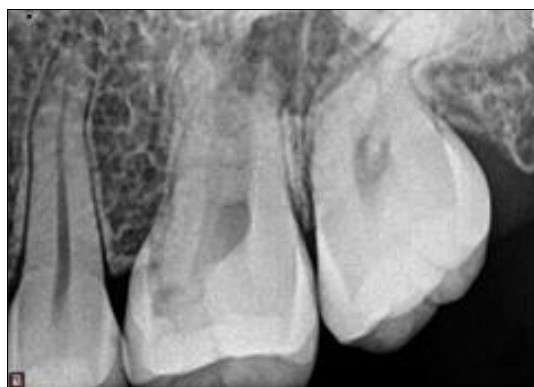

Fig 1: Preoperative radiograph

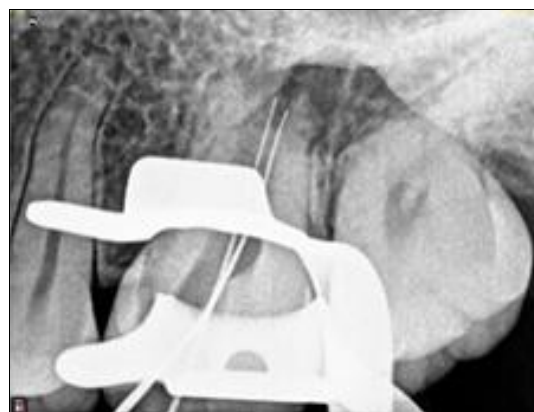


Fig 2: Working length radiograph

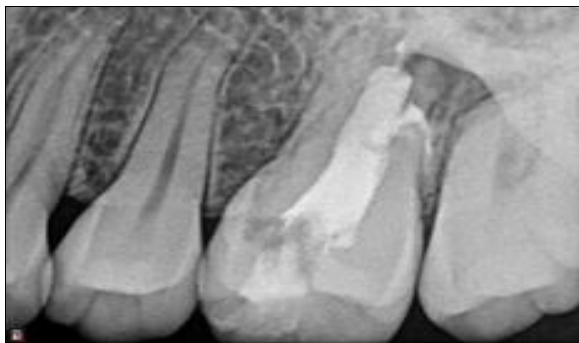

Fig 3: Radiograph after calcium hydroxide (Metapex) placement in the canals

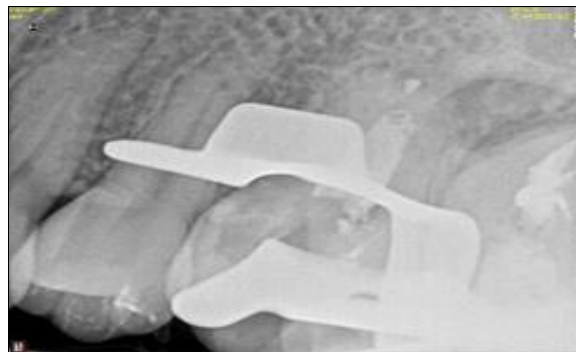

Fig 7: Radiograph after apical barrier placement and backfilling procedure in the palatal canal

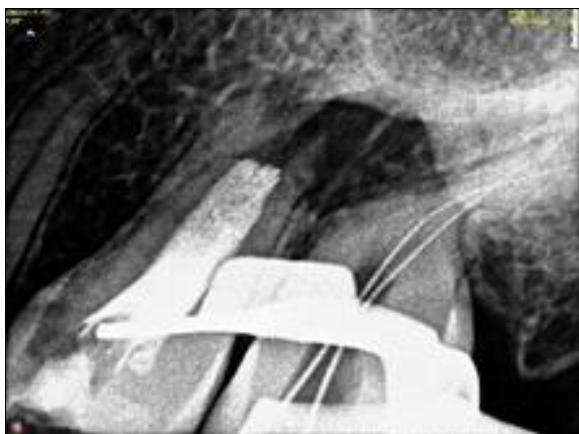


Fig 4: Working length radiograph of second maxillary molar

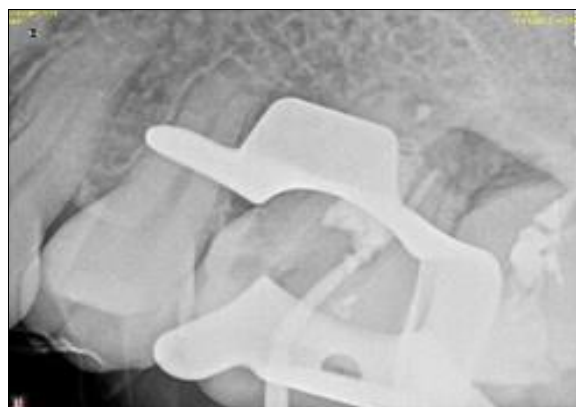

Fig 8: Master cone in the buccal canal

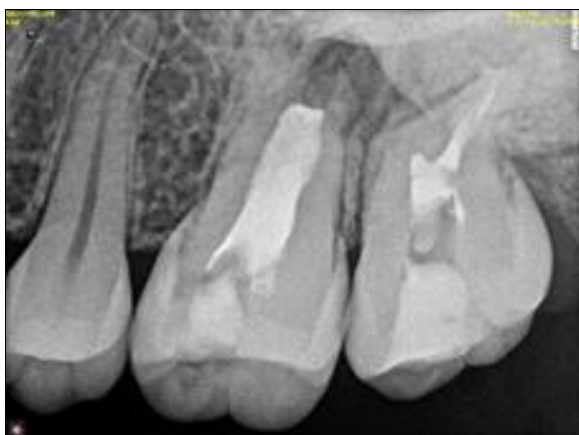


Fig 5: Radiograph after calcium hydroxide (metapex) placement in the second maxillary molar

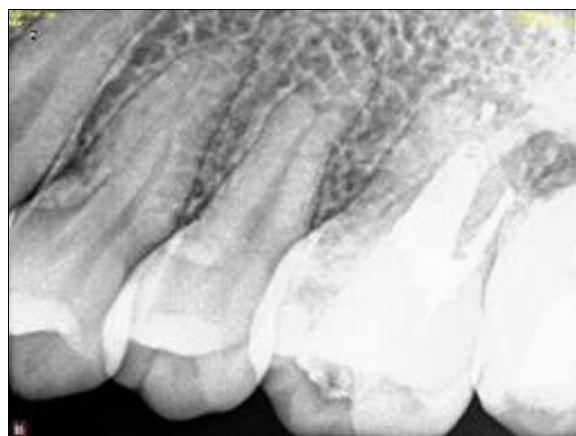

Fig 9: Post obturation radiograph

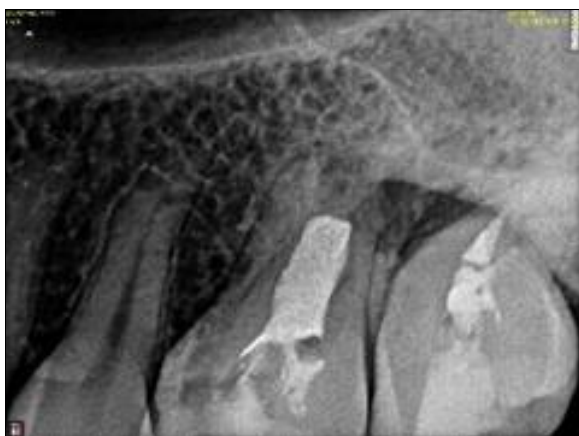


Fig 6: Radiograph after second set of calcium hydroxide (Metapex) placement in the first maxillary molar

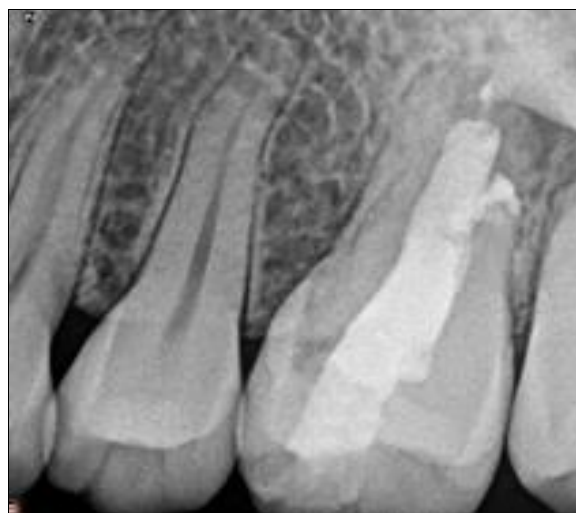

Fig 10: Radiograph at the 6 month review

Conclusion

This case report shows the successfully treated open apex of a cyst-enucleated tooth. The palatal canal of the tooth was a blunderbuss canal in which apexification was done using bio dentine as a barrier and backfilling was done using the thermoplastic obturation method. The outcome of the treatment after 6 months of review is satisfactory however, the patient is advised to do the periodic recall.

Acknowledgement

I would like to express my sincere gratitude to all the staffs and postgraduate students in the Department of Conservative dentistry and Endodontics, Trivandrum for all the sincere support and effort.

Author's Contribution

Not available

Conflict of Interest

Not available

Financial Support

Not available

References

1. Shams O, Mirza AJ, Javaid MA. Non-Surgical Management of Blunderbuss Root Apices by Chemical Debridement and High-Viscosity Silicate Based Apical Plug. *Journal of Innovations in Medical Research*. 2022 Sep 29;1(3):26-30.
2. Struthers P, Shear M. Root resorption by ameloblastomas and cysts of the jaws. *International Journal of oral surgery*. 1976 Jun 1;5(3):128-32.
3. Rafter M. Apexification: a review. *Dental Traumatology*. 2005 Feb;21(1):1-8.
4. Akay MC, Kaya E, Zeytinoğlu M. Treatment of nonsyndromic dentigerous cysts in primary dentition. *Clinical, cosmetic and investigational dentistry*. 2011 Feb 25:17-23.,
5. Akay MC, Kaya E, Zeytinoğlu M. Treatment of nonsyndromic dentigerous cysts in primary dentition. *Clinical, cosmetic and investigational dentistry*. 2011 Feb 25:17-23.
6. Kaur M, Singh H, Dhillon JS, Batra M, Saini M. MTA versus Biodentine: review of literature with a comparative analysis. *Journal of clinical and diagnostic research: JCDR*. 2017 Aug;11(8):ZG01.

How to Cite This Article

P Amitha. Single visit apexification of a permanent maxillary molar using bio dentine: A case report. *International Journal of Applied Dental Sciences*. 2023;9(2):279-282.

Creative Commons (CC) License

This is an open access journal, and articles are distributed under the terms of the Creative Commons Attribution-NonCommercial-ShareAlike 4.0 International (CC BY-NC-SA 4.0) License, which allows others to remix, tweak, and build upon the work non-commercially, as long as appropriate credit is given and the new creations are licensed under the identical terms.