



International Journal of Applied Dental Sciences

ISSN Print: 2394-7489
ISSN Online: 2394-7497
IJADS 2023; 9(2): 340-345
© 2023 IJADS
www.oraljournal.com
Received: 03-03-2023
Accepted: 06-04-2023

Dr. Tasbeeha Shaikh
Pursuing Fellowship in Oral
Implantology - MUHS
Government Dental College &
Hospital, Mumbai, Maharashtra,
India

Dr. Jyoti Tembhurne
Professor and H.O.D,
Department of Prosthodontics
and Crown & Bridge,
Government Dental College and
Hospital Mumbai, Mumbai,
Maharashtra, India

Dr. Arti Gangurde
Associate Professor, Department
of Prosthodontics and Crown &
Bridge, Government Dental
College and Hospital Mumbai,
Mumbai, Maharashtra, India

Dr. Niraja Jaiswal
Associate Professor, Department
of Prosthodontics and Crown &
Bridge, Government Dental
College and Hospital Mumbai,
Mumbai, Maharashtra, India

Corresponding Author:
Dr. Tasbeeha Shaikh
Pursuing Fellowship in Oral
Implantology - MUHS
Government Dental College &
Hospital, Mumbai, Maharashtra,
India

Implant-Supported prosthesis replacement of a single missing maxillary premolar in the region of poor bone quality: A case report

Dr. Tasbeeha Shaikh, Dr. Jyoti Tembhurne, Dr. Arti Gangurde and Dr. Niraja Jaiswal

DOI: <https://doi.org/10.22271/oral.2023.v9.i2e.1744>

Abstract

Achieving Osseo integration is of utmost importance for the success of implant therapy. Poor bone density (D3 & D4 type from Misch classification) is common in the maxillary jaw, especially in elderly patients which can create a hindrance to proper Osseo integration. A successful implant therapy would optimally re-create the lost mucogingival contours while maintaining their relationship to the prosthesis by replacing the tooth/ teeth. The time of implant placement plays a crucial role and is to be decided on a case-to-case basis. The present report describes a case of Osstem TS IV implant placement in the maxillary right premolar region with a delayed loading approach.

Keywords: Dental implants, osseointegration, rehabilitation

Introduction

Restoration of the harmonious form, function and aesthetics of the oral structures comprising teeth, bones and soft tissue, forms the crux of dentistry. When replacing a single missing tooth, conventional fixed partial dentures warrant preparation of the adjacent teeth as abutments for support of the prosthesis [1]. Dental implants have eliminated this need and allow the replacement of a single tooth without damaging the existing structures.

Osseo integration was defined by Branemark as 'A direct structural and functional connection between ordered living bone and the surface of the load-covering the implant' [2]. Undoubtedly, achieving Osseo integration is of utmost importance for the success of implant therapy. One of the prerequisites for achieving optimum Osseo integration osseous fixation is primary stability at the time of surgery which can be inadequate in poor bone. Poor bone density (D3 & D4 type from Misch classification) is common in the maxillary jaw, especially in elderly patients which can create a hindrance to proper Osseo integration [3].

A successful implant therapy would optimally re-create the lost mucogingival contours while maintaining their relationship to the prosthesis by replacing the tooth/ teeth. The time of implant placement plays a crucial role and is to be decided on a case-to-case basis. Depending on the time of implant placement from that of the extraction procedure, three types of insertions can be defined: immediate – at the time of extraction, early - within two months after extraction, and delayed – six months following the extraction [4].

The present report describes a case of delayed implant placement in the maxillary right premolar region with a conventional/delayed loading approach.

Case report

A 46-year-old female reported to the institute wanting a replacement for a missing upper right premolar. The tooth had been extracted elsewhere about five months ago due to extensive caries. The patient complained of difficulty in chewing food from the side and was also conscious about the empty space that was slightly visible when smiling. The patient's medical history was unremarkable and she did not have any tobacco-related habits.

On intra-oral examination, only a missing permanent maxillary right second premolar was noted with an adequately healed extraction socket and overlying mucosa. The gingiva and periodontium were in a healthy state and showed no evidence of disease clinically. The patient was explained various treatment options possible for the replacement of the tooth which included removable partial denture, fixed partial denture and dental implant. The patient opted for the replacement of the tooth by a dental implant and informed consent of the patient was obtained prior to the procedure. Cone-beam computed tomography scans revealed the presence of a D4 type of bone in the region which was of dimensions 13 x 5.5 mm.

The patient was draped and surgically prepared with povidone-iodine scrub under standard clinical aseptic conditions for surgery. Intra-oral prophylactic cleansing was performed by rinsing the oral cavity with chlorhexidine gluconate mouthwash in order to lower the bacterial counts that could potentially contaminate the site of surgery. The surgical site was anaesthetized by local infiltration technique using 2% lignocaine with 1:80,000 adrenaline.

After subjective as well as objectively confirming the effect of the anaesthetic agent, a mid-crestal incision was made. A full-thickness mucoperiosteal flap was elevated to expose the surgical site. A pilot drill (Osstem taper kit lance drill) was used to initiate the implant site preparation with a parallel pin placed in the drilled socket to ascertain parallelism. The osteotomy was completed using a sequence of drills to achieve the desired diameter and depth of 4 x 10 mm.

An implant fixture of 4 x 10 mm (Osstem TS IV, Osstem implant Co., Busan, Korea) was placed with an adequate torque of 30 Ncm along with a coverscrew. The flap was repositioned and sutured with interrupted sutures. Postoperatively, the patient was prescribed antibiotics, analgesics, and an anti-inflammatory drug and was instructed to avoid chewing on the implant site for two weeks. Suture removal was performed ten days post-surgery and uneventful healing of the mucosa overlying the surgical site was observed.

After four post-surgical months, the implant was exposed; the clinical and radiographic evaluation of the implant showed good Osseo integration. An open-tray impression was made using putty and light body impression material with the coping in place. A jig was prepared using pattern resin. Metal and bisque trials were done for the custom-made abutment. A screw-retained porcelain-fused-to-metal (PFM) crown prosthesis was fabricated according to the shade of the adjacent teeth which was then loaded onto the implant after confirming the suitable fit and achieving the desired occlusion.

Discussion

The time elapsed from the tooth extraction to the time of implant placement is one of the most deciding factors for the aesthetic and functional success of the final restoration. It can dictate the amount of loss in both hard and soft tissue profiles. Since most of the resorption occurs within the first year after extraction, implantologists attempt to place the implant before the occurrence of much significant loss of tissues^[5]. In corroboration with the above statements, as five months had already elapsed since the extraction of the tooth, the implant site was drilled with a suitable tapered sequence of drills. The implant placement was planned four months post-surgery to allow for adequate healing which was well within the confines of one-year post-extraction.

The particular selection of the implant in the present case was done considering the poor quality of the bone. The implant used has an internal connection, with a hexagon shape with Morse taper designed specifically to perform in weaker bones^[6]. The primary stability of the implant is improved because of helical cutting, corkscrew thread, and sharp and rounded apex design^[7]. This allows the implant to be placed in the sites with minimal initial drilling (2 or 3mm in D4 bone).

Sandblasted, large grit, acid-etched implant surface combines crater and micro-pit morphology that provides good surface roughness that enables faster rates of cell response and bone healing^[8]. This makes loading of the implants as early as six weeks post-surgery possible. Even so, the poor quality of the bone in the present case dictated a waiting period of four months to allow for sufficient healing to take place.

The maximum recommended torque for placement of the implant system is 40 Ncm and thus, a value of 30 Ncm was adopted in the present case^[9]. In poorer quality bones such as those of D3 and D4 types, the drilling speed is not as crucial and therefore, a lower speed of about 1000 rotations per minute was preferred on the present case.

When subjected to an axial load, the cemented prostheses present stress peaks similar to those of the screwed prostheses, which may be justified by the nature of the load, which does not develop any shear component^[10]. However, under oblique loads, it has been demonstrated that screwed models of prosthesis exhibit significantly lower levels of stress in the peri-implant bone than those cemented. This could be attributed to the lower tendency of the screwed models to bend. Screwed prostheses are also advantageous from the biological point of view, because cemented prostheses have a higher marginal micro-gap area, and are positioned more coronally. Therefore, a screw-fitting PFM prosthesis was loaded onto the implant in the present case.

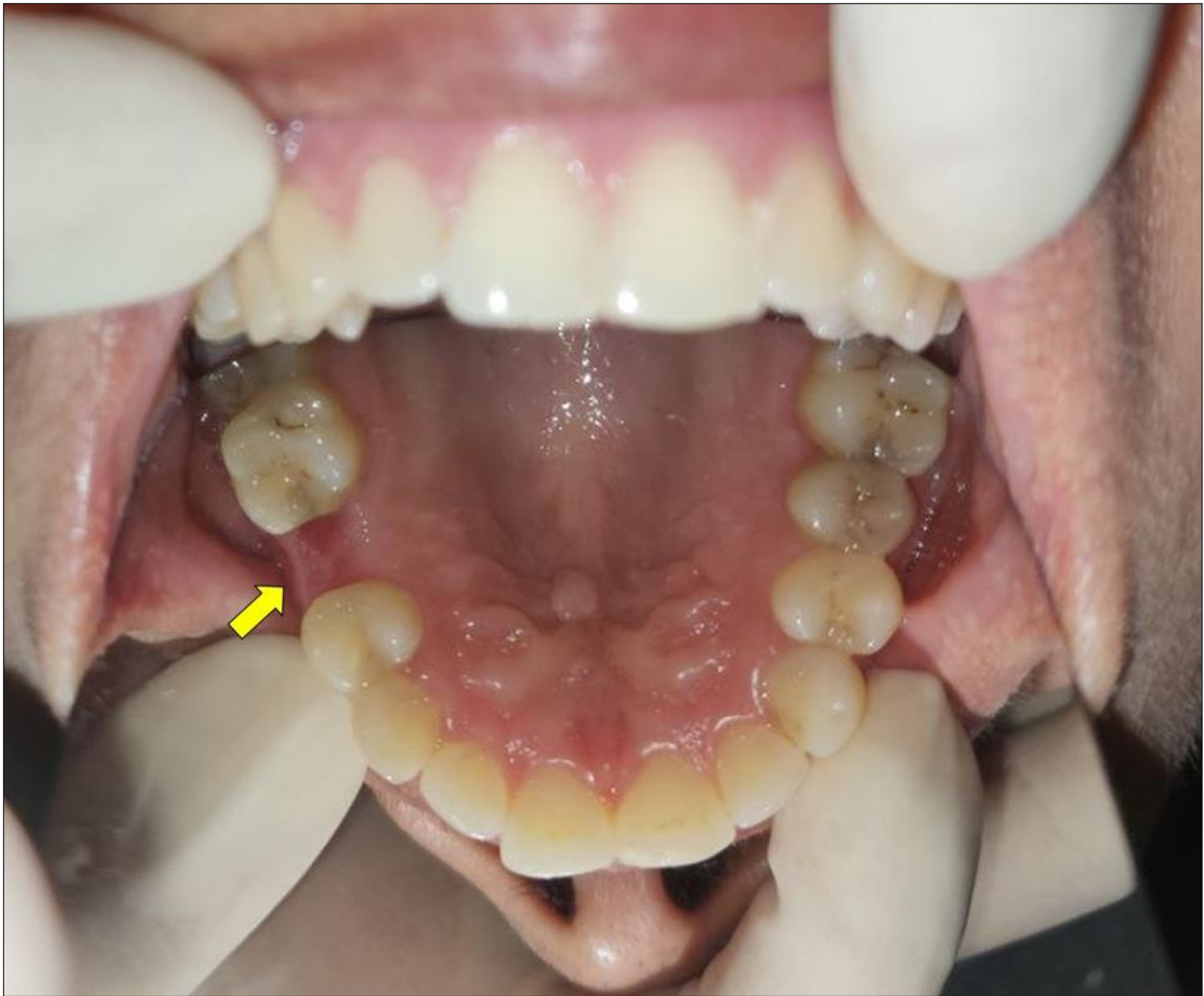

Fig 1: Missing maxillary right second premolar with healed socket and overlying mucosa

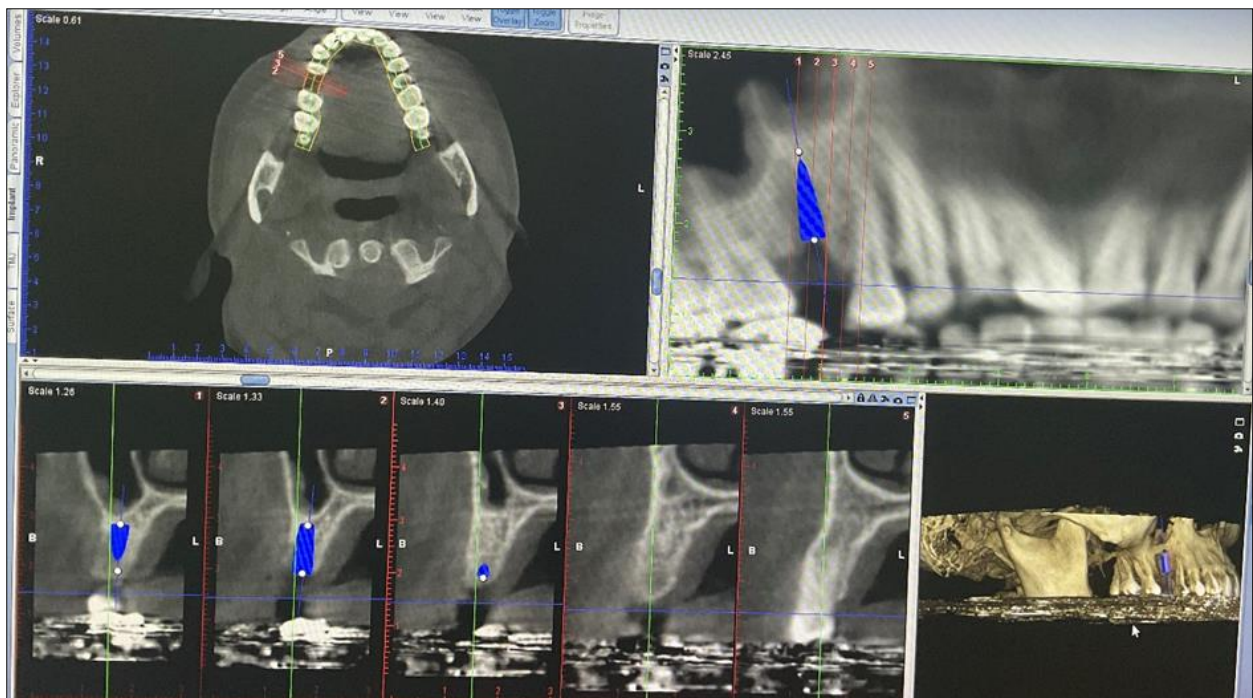


Fig 2: Cone beam computer tomography scans of the maxilla showing D4 type bone

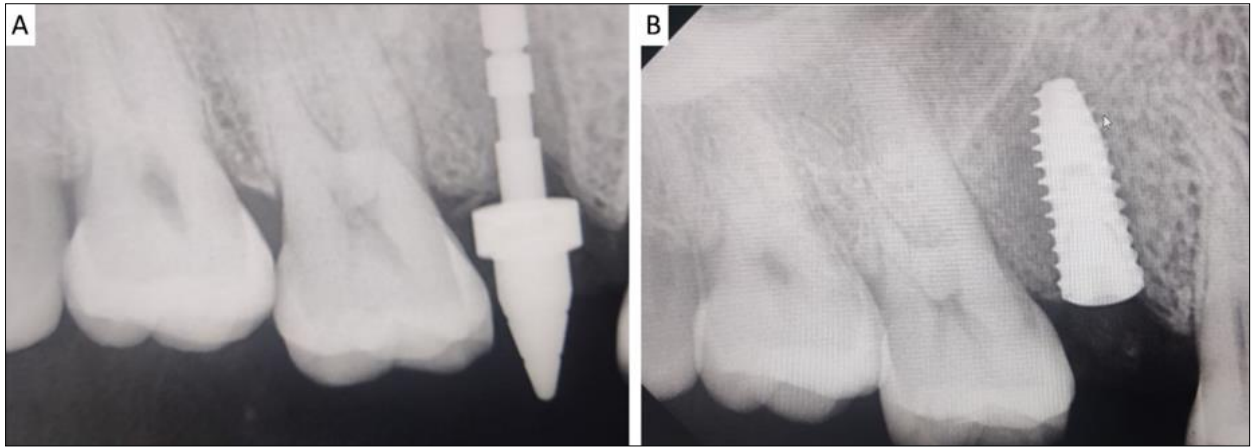


Fig 3: Intra-oral periapical radiographs showing A) parallelism pin placement and B) implant placement

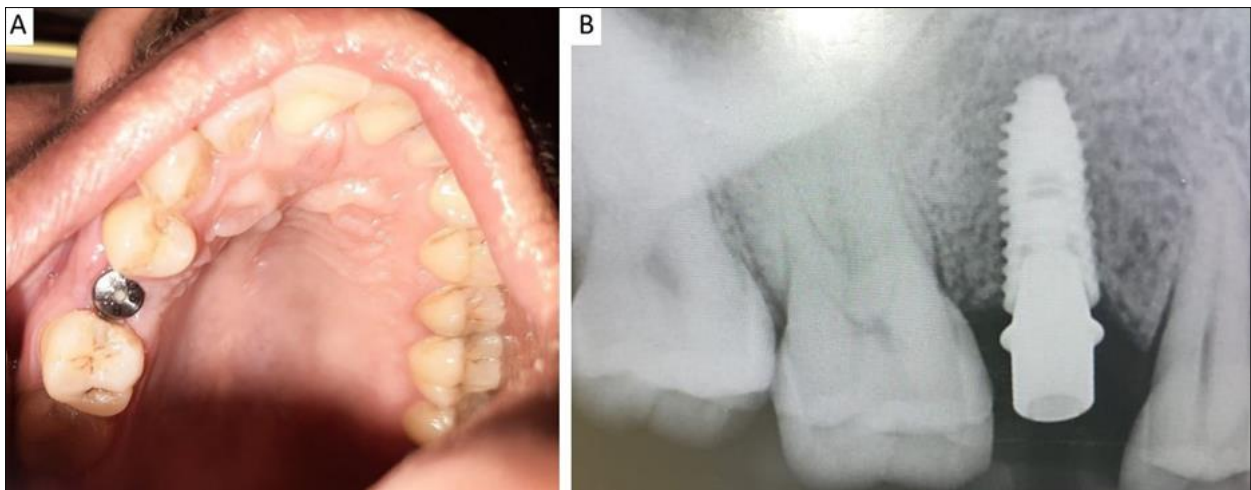


Fig 4: Healing abutment in place A) on clinical examination; and B) in intraoral periapical radiograph

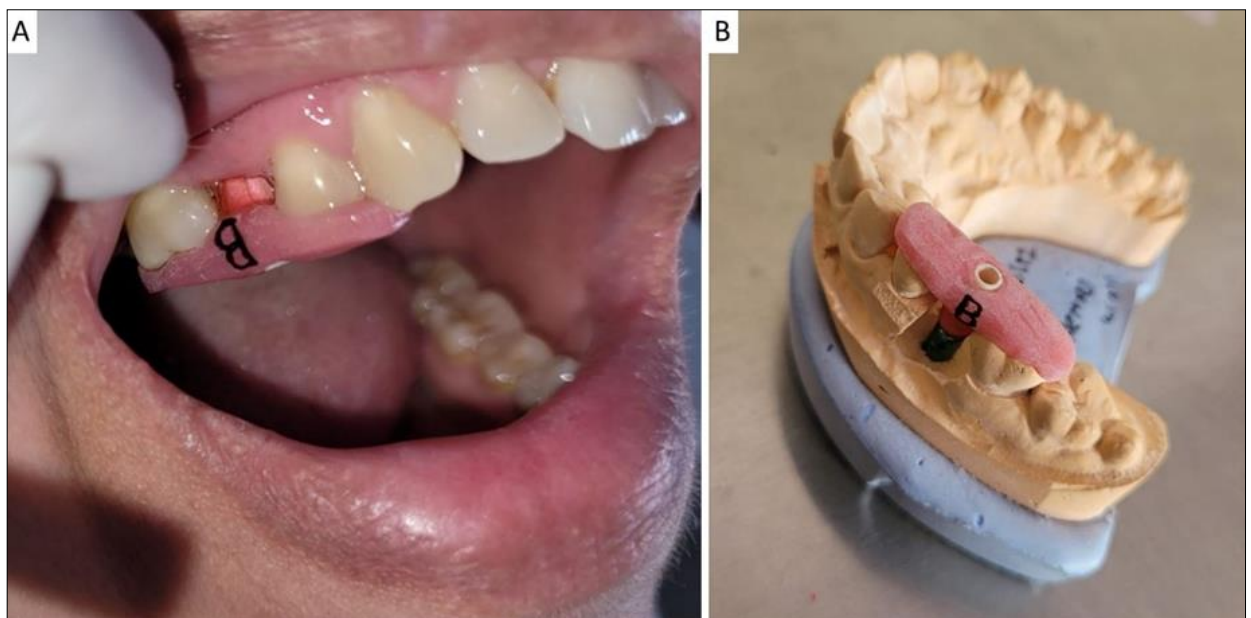


Fig 5: Acrylic jig trial on coping A) intra-orally, and B) on the prepared cast

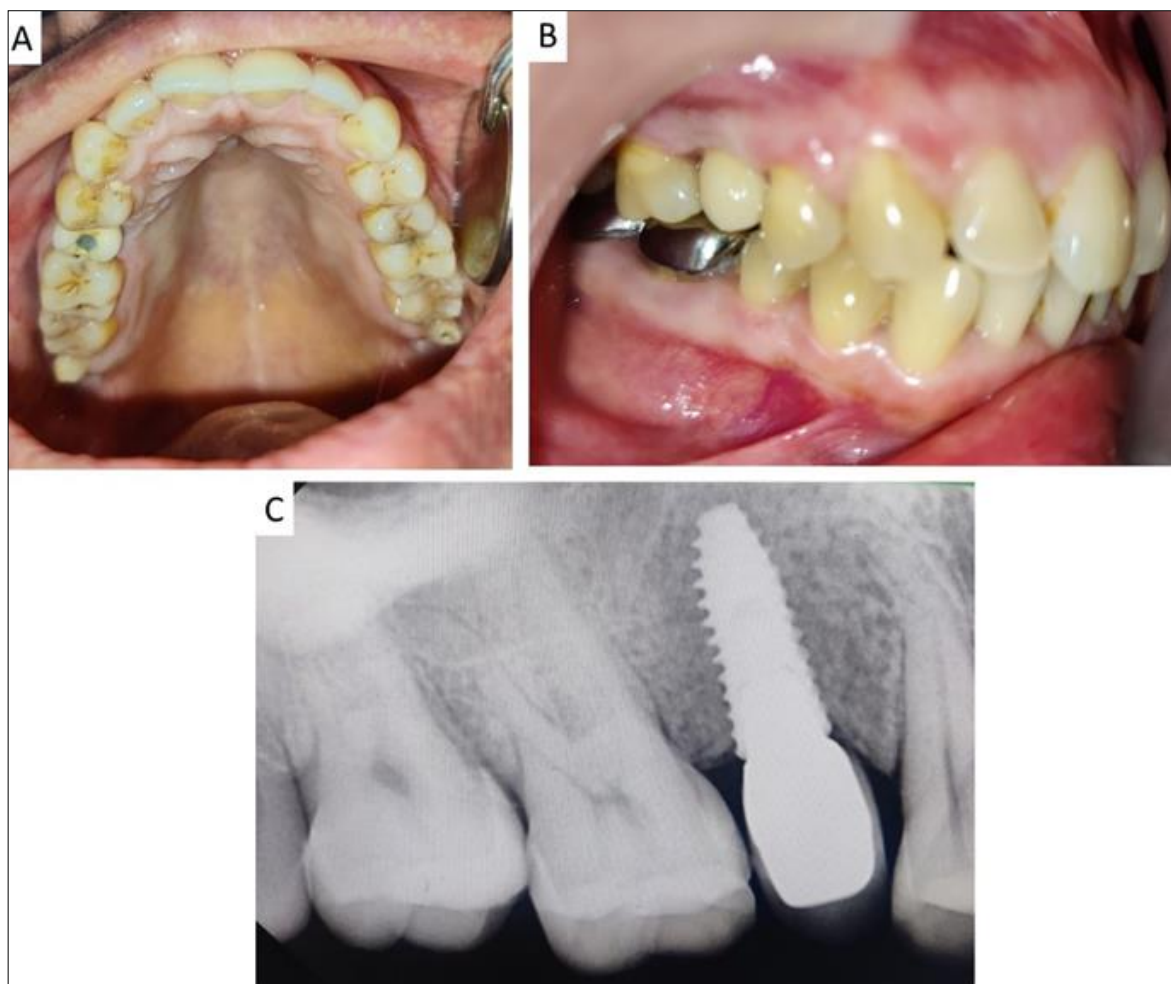


Fig 6: A) Implant loaded with screw-retained porcelain fused to metal crown, B) Achieved occlusion with the prosthesis in place; C) intra-oral periapical radiograph after placement of the prosthesis

Conclusion

An ideal result is when the clinical appearance of the tissues in the area restored by implants closely mimics the normal mucogingival contours. The present case report would serve to guide the clinicians into decision-making when faced with the replacement of a single tooth by the implant in the presence of poor bone quality.

Conflict of Interest

Not available

Financial Support

Not available

References

1. Thompson MC, Thompson KM, Swain M. The all-ceramic, inlay supported fixed partial denture. Part 1. Ceramic inlay preparation design: A literature review. *Australian dental journal*. 2010 Jun;55(2):120-7.
2. Chug A, Shukla S, Mahesh L, Jadwani S. Osseo integration: Molecular events at the bone-implant interface: A review. *Journal of Oral and Maxillofacial Surgery, Medicine, and Pathology*. 2013 Jan 1;25(1):1-4.
3. Török B, Török R, Forna N. Study regarding share of peri-implant bone augmentation techniques and materials. *Rom. J. Oral Rehab*. 2020 Jan;12:88-96.
4. Schropp L, Isidor F. Timing of implant placement relative to tooth extraction. *Journal of Oral Rehabilitation*. 2008 Jan;35:33-43.
5. Chappuis V, Araújo MG, Buser D. Clinical relevance of dimensional bone and soft tissue alterations post-extraction in esthetic sites. *Periodontology* 2000. 2017 Feb;73(1):73-83.
6. Kim YK, Kim BS, Yun PY, Mun SU, Yi YJ, Kim SG, Jeong KI. The seven-year cumulative survival rate of Osstem implants. *Journal of Korean Association of Oral and Maxillofacial Surgeons*. 2014;40(2):68-75.
7. Oh GY, Park SH, Kim SG. Influence of implant fixture design on implant primary stability. *The Journal of Korean Academy of Prosthodontics*. 2007;45(1):98-106.
8. Velasco-Ortega E, Ortiz-Garcia I, Jiménez-Guerra A, Núñez-Márquez E, Moreno-Muñoz J, Rondón-Romero JL, Cabanillas-Balsera D, Gil J, Muñoz-Guzón F, Monsalve-Guil L. Osseo integration of sandblasted and acid-etched implant surfaces. A histological and histomorphometric study in the rabbit. *International Journal of Molecular Sciences*. 2021 Aug 7;22(16):8507.
9. Bayarchimeg D, Namgoong H, Kim BK, Kim MD, Kim S, Kim TI, Seol YJ, Lee YM, Ku Y, Rhyu IC, Lee EH. Evaluation of the correlation between insertion torque and primary stability of dental implants using a block bone test. *Journal of periodontal & implant science*. 2013 Feb 1;43(1):30-6.
10. Silva GC, Cornacchia TM, de Magalhães CS, Bueno AC, Moreira AN. Biomechanical evaluation of screw-and cement-retained implant-supported prostheses: a nonlinear finite element analysis. *The Journal of prosthetic dentistry*. 2014 Dec 1;112(6):1479-88.

How to Cite This Article

Shaikh T, Tembhrune J, Gangurde A, Jaiswal N. Implant-Supported prosthesis replacement of a single missing maxillary premolar in the region of poor bone quality: A case report. International Journal of Applied Dental Sciences. 2023;9(2):340-345.

Creative Commons (CC) License

This is an open access journal, and articles are distributed under the terms of the Creative Commons Attribution-Non Commercial-Share Alike 4.0 International (CC BY-NC-SA 4.0) License, which allows others to remix, tweak, and build upon the work non-commercially, as long as appropriate credit is given and the new creations are licensed under the identical terms.