



ISSN Print: 2394-7489  
ISSN Online: 2394-7497  
IJADS 2023; 9(3): 308-313  
© 2023 IJADS  
[www.oraljournal.com](http://www.oraljournal.com)  
Received: 03-06-2023  
Accepted: 13-07-2023

**Dr. Akanksha S Katkade**  
3rd year MDS student,  
Department of Prosthodontics,  
GDCH Aurangabad (CHH,  
Sambhajinagar),  
Maharashtra, India

**Dr. Vilas Rajguru**  
Associate Professor, Govt.  
Dental College and Hospital,  
Aurangabad, Maharashtra, India

**Dr. Kishor M Mahale**  
HOD & Professor, Govt. Dental  
College and Hospital,  
Aurangabad, Maharashtra, India

**Dr. Smita A Khalikar**  
Professor, Govt. Dental College  
and Hospital, Aurangabad,  
Maharashtra, India

**Dr. Sonali Mahajan**  
Associate Professor, Govt.  
Dental College and Hospital,  
Aurangabad, Maharashtra, India

**Corresponding Author:**  
**Dr. Akanksha S Katkade**  
3rd year MDS student,  
Department of Prosthodontics,  
GDCH Aurangabad (CHH,  
Sambhajinagar),  
Maharashtra, India

## **Prosthodontic management of Xerostomia in Completely Edentulous patient suffering from Sjogren Syndrome using a fixed maxillary Salivary Reservoir: A Case Report**

**Dr. Akanksha S Katkade, Dr. Vilas Rajguru, Dr. Kishor M Mahale, Dr.  
Smita A Khalikar and Dr. Sonali Mahajan**

DOI: <https://doi.org/10.22271/oral.2023.v9.i3e.1821>

### **Abstract**

Sjogren's syndrome (SS) is a chronic inflammatory disease of the exocrine glands which involves a wide range of extra-glandular tissues. Symptoms of dry mouth or xerostomia, and keratoconjunctivitis sicca or dry eye, both are hallmarks of Sjogren's Syndrome. Increased susceptibility for dental caries, infections, burning sensations and ulcerations are the significant consequences of the oral component of SS. It is commonly known as a disease of middle-aged and elderly women. It is found more commonly in women than in men at a ratio of 9:1. Xerostomia or dry mouth is the medical term used to describe the subjective sensation of oral dryness, which commonly presents as a result of reduced salivary flow (hyposalivation). Saliva plays an extremely important role in maintaining the overall health of the oral cavity. So, it is essential for the prosthodontist to give special consideration to the salivary characteristics before, during and after fabrication of denture. In the completely edentulous, the presence of optimal quality and quantity of saliva becomes even more important. Denture stability, retention and overall oral health are detrimentally affected by any changes in salivary flow or characteristics. Hence in this case report a prosthodontic approach is describe to treat xerostomia in a completely edentulous patient using salivary reservoir and salivary substitutes.

**Keywords:** xerostomia, salivary reservoir, salivary substitute, saliva

### **1. Introduction**

Sjogren's syndrome is a systemic disorder characterized by reduced or lack of function of salivary and lacrimal glands. Dry mouth/xerostomia and Dry eyes/keratoconjunctivitis sicca are the most common symptoms. The dental practitioner may be the first to detect SS because of the discernable oral changes present in such patients. These patients benefit from early diagnosis, as preventive practices can slow the effect of lacrimal and salivary hypofunction on the eyes and mouth<sup>[1]</sup>. "Subjective dry mouth sensation is known as Xerostomia, though when Sialometry objectively demonstrates a saliva flow rate of under 0.1-0.2 ml/min (resting whole saliva) and under 0.7 ml/min (stimulated whole saliva), the term Sialopenia or salivary Hyposecretion is used. This condition is equivalent to the secretion of less than 500 ml of saliva a day"<sup>[2]</sup>.

Six major salivary glands produce major quantity of oral secretions, and the minor salivary glands made a minute contribution. The parotid glands are the largest one, which produce secretions serous in nature and they produce 25% of the total salivary output. The submandibular or Submaxillary glands produce Sero-mucinous saliva which accounts for 70% of total saliva. The sublingual glands account 540 for the remaining 5% and their secretions are mucinous. The glands Combinally produce 1000 to 1500 cc of saliva daily, which contains mucin, sodium, bicarbonate, potassium, phosphate, all free amino acids, chloride, and amylase with an average pH of h.4<sup>[3]</sup>. Cleansing, moisture maintenance and lubrication, regulation of water balance, as well as solvent, antimicrobial, and buffering actions are the functions performed by saliva.

## 2. With the loss of salivation, eating becomes a problem

Fletcherism and swallowing of a bolus of food is often hard or impossible. Denture wearing become extremely uncomfortable as the oral mucosa becomes dry and tends to breach and ulcerate. Saliva also plays very important role in the maintenance and function of the taste buds." Without saliva, patients complain that many foods taste savourless or unpalatable. Xerostomia, along with oral discomforts and loss of taste perceptiveness, can cause patients to become anorexic and make them lose weight and feel poorly. Decrease in saliva output leads to caries. Radiation-induced xerostomia has been related to a shift in the oral microflora to a more acidogenic bacteria population and to a change in the protective properties of saliva. Due to masticatory discomfort, the patient often tends to eat a soft highly cariogenic diet, which contributes further to the caries problem"<sup>[4]</sup>.

Edentulous patients suffering from xerostomia have lack of saliva, therefore physical factors of retention got compromised in such patients. "Therapy of xerostomia (subjective sensation of dry mouth) and hyposalivation (diminished salivary flow) is still often restricted to palliative treatment, particularly in patients suffering from xerostomia and hyposalivation due to Sjogren syndrome. Commercial saliva substitutes are most frequently applied for relieving the sensation of dry mouth and its other side effects. Imitating natural saliva is complex procedure; hence, the principal aims of saliva substitutes are to ensure lubrication of oral tissues, to relieve the sensation of dry mouth, and to protect the tooth tissues from decay. Saliva substitutes differ particularly in their base substance, chemical composition, or viscosity. Till date, a large number of saliva substitutes based particularly on mucin, carboxymethylcellulose, hydroxyethyl cellulose, xanthan gum, linseed, or polyethylene oxide have been developed and introduced"<sup>[5]</sup>.

Therefore, to maintain overall oral health prosthodontic approach to fabricate a maxillary attached salivary reservoir in the denture prosthesis without using any expensive attachment system is described in this case report.

## 3. Case report

A 48-year-old female patient was reported to department of prosthodontics of Government Dental College and hospital with chief complaint of inability to eat and un-aesthetic appearance due to missing teeth. She also complained of dry mouth, burning sensation of mucosa and sleep disturbances due to thirst.

Clinical intraoral examination revealed completely edentulous upper and lower ridges, dry/ desiccated glossy appearing mucosa, angular cheilitis and sticking of instruments i.e., mouth mirror to mucosa during examination.

On extraoral examination it found that she also had dry lips, dry eyes, dry skin.

Her past medical history confirmed she is a known case of Sjogren syndrome.

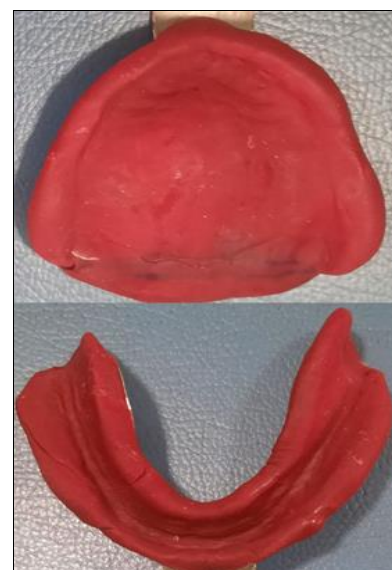
She is also consulting Ophthalmologist for the dry eyes and on the therapeutic treatment for the same.

By keeping in mind about patients' needs and demand, it was decided to give patient upper and lower complete dentures with low volume salivary reservoir for the maxillary denture.

## 4. Steps in fabrication of fixed salivary reservoir in maxillary complete denture

1. Maxillary and mandibular preliminary impression made in impression compound in a non-perforated complete edentulous stock tray made of stainless steel (Fig.1).

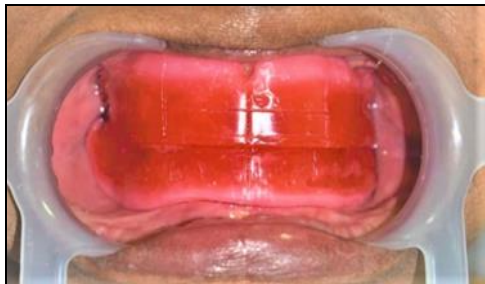2. Custom trays made and border moulding done and final impressions made using condensation silicone light body impression material (Fig.2).
3. Jaw relations were recorded and teeth arrangement was done (Fig.3).
4. Try in was done (Fig.4).
5. Once the try in was done, the trial denture at this stage was then modified by removing the wax and denture base on the palatal surface of the maxillary denture. Denture base thickness was limited to less than 1.5 mm in this region by adding a layer of hard pink wax of 1.5 mm thickness (fig 5 & 6).
6. The sides of the carved reservoir were then provided with a Snap-On type of lock by carving the wax from under the borders. This creates a ledge that extends mesially from all sides. The maxillary denture is then processed using a routine laboratory method for denture processing (Fig. 7& 8).
7. The complete denture was finished and polished (Fig.9).
8. On the processed denture a lid was fabricated using extra hard pink wax. The corresponding snap on lock mechanism was carved at the borders of the lid by extending the wax above and below the existing ledge created within the denture (Fig. 7).
9. After verifying the fit of the lid, the same was then processed in heat cure acrylic denture base resin. The processed lid was then finished and polished. Then it was sealed with maxillary denture using cold cure acrylic resin (Fig 10).
10. Small holes were then made in the lid to allow flow of salivary substitute from the reservoir.
11. CMC Salivary substitute injected into the reservoir through one of the holes (Fig 10 & 11).
12. The denture with salivary reservoir was then checked intraorally for its function and the occlusion was checked for denture stability (Fig 12 & 13).
13. Patient was educated about injecting of salivary substitute into the reservoir and all necessary instructions were given to her.
14. The patient was asked to report on multiple follow up visits since adjustments in the denture were mandatory. The patient reported regularly for follow up visits and was successfully wearing the complete denture prosthesis with great satisfaction.



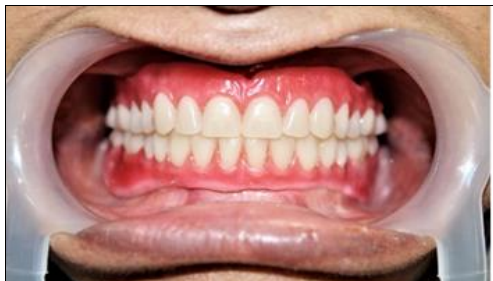**Fig 1:** Preliminary impressions



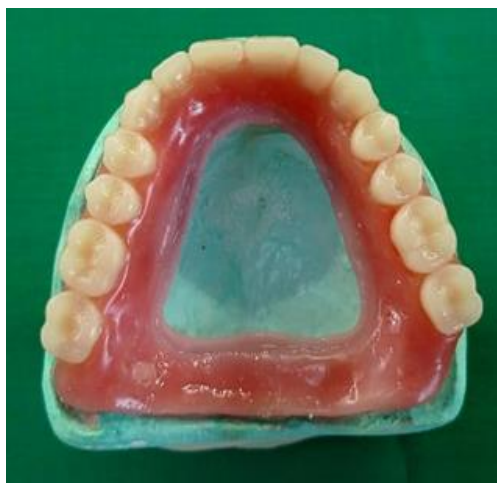
**Fig 2:** Final impressions



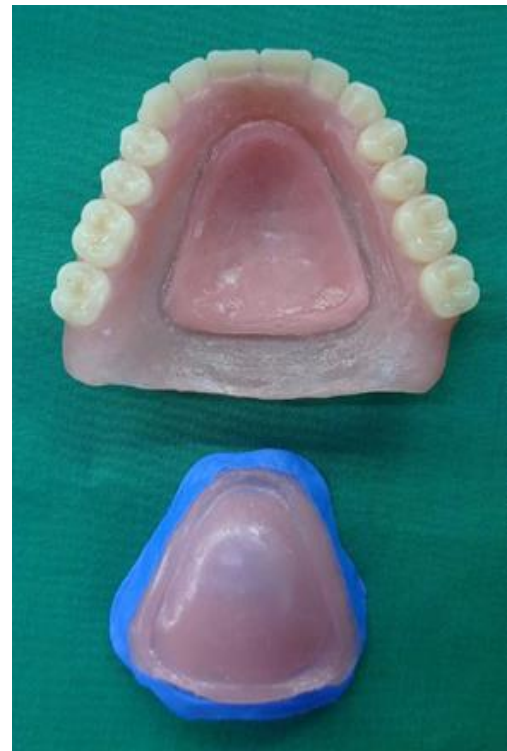**Fig 3:** Maxillomandibular relationship



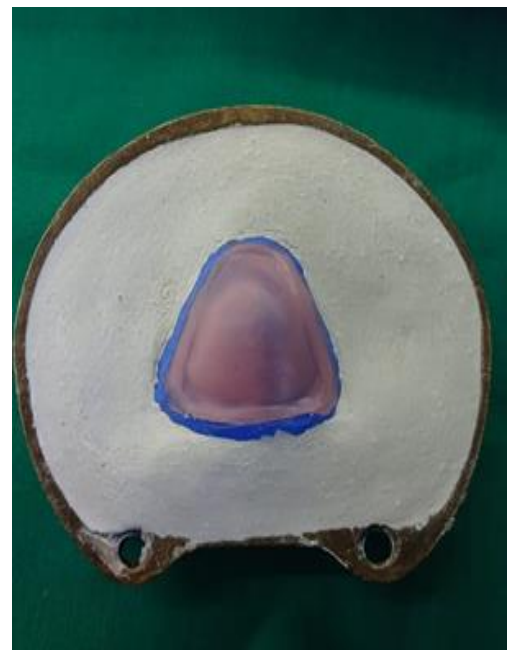**Fig 4:** Waxed up denture trial



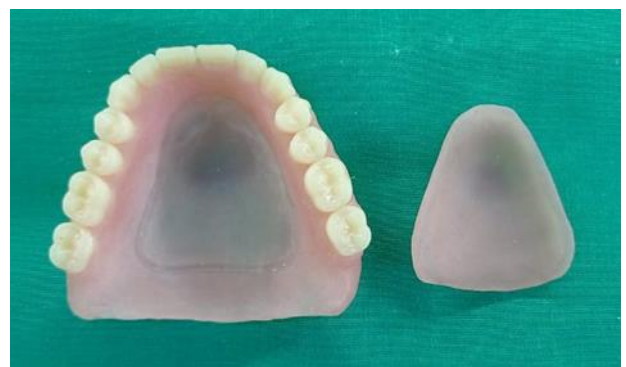**Fig 5:** Palatal portion of denture base & wax removed



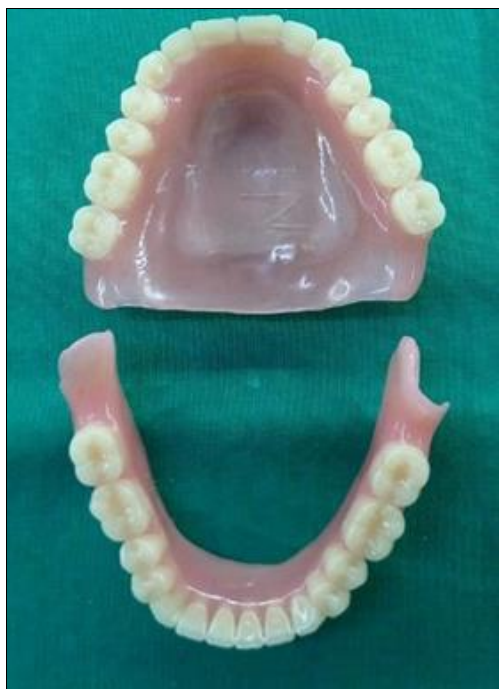**Fig 6:** 1 mm of wax added on palate with carved margins and hard pink wax used to make lid with snap on attachment



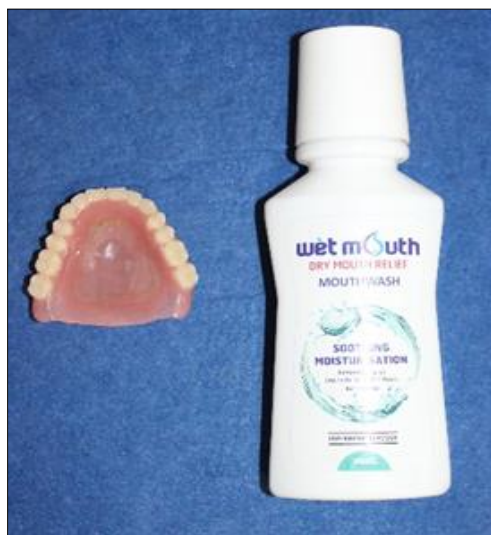**Fig 7:** Flasking done



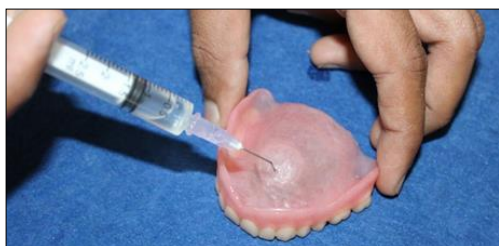**Fig 8:** Processed maxillary denture and lid



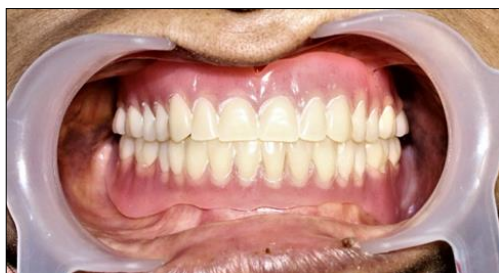**Fig 9:** Final finished polished denture



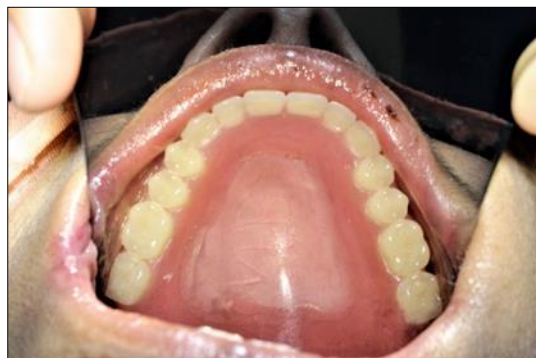**Fig 10:** CMC salivary substitute liquid



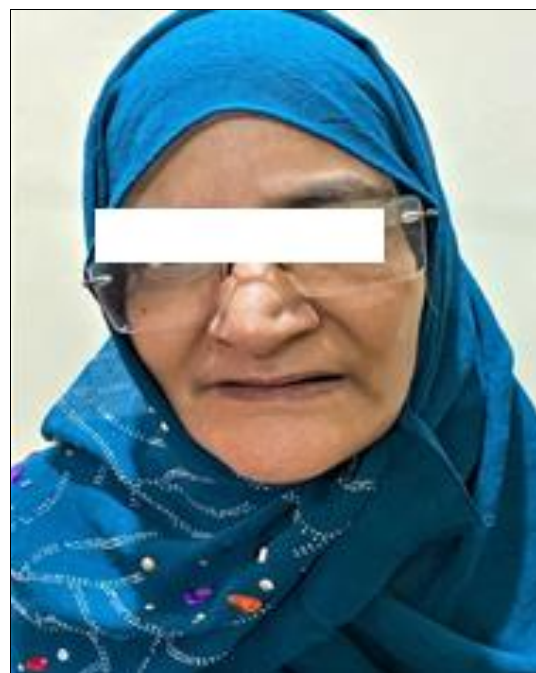**Fig 11:** Injecting salivary substitute through holes in reservoir



**Fig 12:** Final complete denture in occlusion



**Fig 13:** Maxillary fixed salivary reservoir



**Fig 14:** Preoperative



**Fig 15:** Postoperative

### 5. Discussion

In completely edentulous subjects, due to loss of all their natural teeth, they are mainly dependent upon artificial prosthesis to carry out the routine oral functions of chewing and hence the presence of appropriate quantity and quality of saliva becomes even more crucial [3]. Preserving denture integrity by keeping the denture surfaces clean and maintaining proper oral hygiene by physically washing away

food and other debris from the soft tissues and from the polished surface of the prosthesis is one of the important functions of saliva. The lubricating effect of saliva in dentate patients is equally important in the edentulous as this will help to make the surface of the dentures more compatible with the movements of the lips, cheek and tongue. The movement of soft tissues during speech, mastication and swallowing of food are facilitated by the Salivary glycoproteins [3]. In Sjogren syndrome, patient suffer from xerostomia i.e., lack of saliva which ultimately compromise all the above-mentioned functions of saliva. Hence it is necessary to restore normal levels of saliva using medications or delivering substitutes through prosthesis in oral cavity of patients.

Denture retention is also to a large extent dependent upon saliva. "Retention in complete denture prosthodontics is defined as the quality inherent in the prosthesis which resists the forces of dislodgement along the path of insertion" [6]. Satisfactory denture retention is an essential requirement for successful rehabilitation of edentulous patients with complete dentures. The establishment of an accurate and intimate fit of the denture base to the mucosa and the achievement of a proper peripheral seal are two important factors that provide retention to complete dentures [7]. Adhesion, Cohesion, Interfacial surface tension, Atmospheric pressure, Capillary attraction and Gravity are the physical factors that contribute to denture retention. An optimal flow, consistency and volume of saliva is considered to be a major factor in enabling these physical factors to act in unison and aid in denture retention [7-9].

Complete denture fabrication in patients with existing xerostomia poses a challenge to both dentist and the patient. The objectives of an impression like retention and stability entirely depend upon the presence of saliva, which keeps oral mucosa constantly moist. Denture wearing becomes traumatic in absence of saliva and various authors have suggested different techniques for incorporating a salivary reservoir within a complete denture. Use of precision attachments have [8, 9] have been criticized for hygiene maintenance problems. Similar problems arise when using a resilient liner for salivary reservoir [10]. The technique mentioned in this article is very simple, inexpensive and does not need any special equipment or attachment. The technique is based on the principle of customized prosthesis which has been found to be inexpensive in the previous report [11]. The snap on type of the lock is effective and can be enhanced by fixing it with denture by sealing its border using cold cure acrylic resin. Although it is a low volume reservoir, patients need to restore salivary substitute level frequently. Another problem is that the holes in the lid need to be kept in less numbers and that of small size. The sudden suction by the patient can remove all stored artificial saliva from the reservoir [11]. But problem of lid aspiration in case of removable lid is solved as it is sealed using cold cure acrylic resin.

While Toljanic and Zucuskie [12] incorporated salivary reservoir in maxillary denture, Sinclair *et al.* found mandibular denture to deliver saliva directly to the mucosa because of the influence of gravity [13]. Various other designs have been suggested in the literature. Sinclair *et al.* used magnets to connect reservoir parts [13]. Mendoza & Tomlinson split the upper and lower parts in the mandibular denture although additional laboratory stages made their procedure time consuming [14]. Burhanpurwala *et al.* prepared salivary reservoir in the mandibular denture using a single articulator but two flasks [15]. The drawbacks of these methods were overcome by the method described in this article by selecting

the maxillary denture and designing a salivary reservoir that is not time consuming, does not need additional equipment, material or procedure and is effective in function.

## 6. Conclusion

Prosthodontic treatment not only limited to merely replace the missing teeth but also at same time to rehabilitate entire oral health. This article describes simple, inexpensive and non-invasive method to treat xerostomia in completely edentulous patient occurring due to various reasons.

## 7. Conflict of Interest

Not available

## 8. Financial Support

Not available

## 9. References

1. Atkinson JC, Fox PC. Sjogren's syndrome: oral and dental considerations. *J Am Dent Assoc.* 1993 Mar;124(3):74-6, 78-82, 84-6. DOI: 10.14219/jada.archive.1993.0064.
2. Dr. Singh OP, Dr. Rubina, Dr. Nikita, Dr. Mittal N, Dr. Saini R. How to Manage Xerostomia In Prosthodontics? *Dental Journal of Advance Studies*; c2013, 1(3).
3. Stavreva N, Kapusevska B. Function of Saliva at Patients With Complete Dentures. An Overview. *Knowledge – International Journal March*; c2019. p. 30.4.
4. Vergo TJ, Kadish SP. Dentures as artificial saliva reservoirs in the irradiated edentulous cancer patient with xerostomia: A pilot study. *Oral Surg. Oral Med Oral Pathol.* 1981;51:229-233.
5. Łysik D, Niemirowicz-Laskowska K, Bucki R, Tokajuk G, Mystkowska J. Artificial Saliva: Challenges and Future Perspectives for the Treatment of Xerostomia. *International Journal of Molecular Sciences.* 2019;20(13):3199. <https://doi.org/10.3390/ijms20133199>
6. Vergo TJ, Kadish SP. Dentures as Artificial Saliva Reservoirs in the Irradiated Edentulous Cancer Patient with Xerostomia: A Pilot Study. *Oral Surg. Oral Med Oral Pathol.* 1981;51:229-233.
7. Darvell BW, Clark RKF. The Physical Mechanisms of Complete Denture Retention. *Br Dent J.* 2000;189(5):248-52.
8. Turner M, Jahangiri L, Ship JA. Hyposalivation, Xerostomia and the Complete Denture-A Systematic Review. *J Am Dent Assoc.* 2008;139(2):146-50.
9. Chandu GS, Hombesh MN. Management of Xerostomia and Hypo salivation In Complete Denture Patients. *Ind. J Stomatol.* 2011;2(4):263-6.
10. Stavreva N, Kapusevska B, Function of Saliva At Patients With Complete Dentures. An Overview. *Knowledge – International Journal*, 2019, 30(4).
11. Singh M, Deep A, Mattoo KA, Roma Goswami. Low Volume Salivary Reservoir in Complete Denture Prosthesis for Xerostomia. *Journal of Case Reports: Clinical & Medical.* 2019;2(2):134.
12. Toljanic JA, Zucuskie TG. Use of A Palatal Reservoir In Denture Patients With Xerostomia. *J Prosthet Dent.* 1984;52:540-544.
13. Sinclair GF, Frost PM, Walter JD. New Design for an Artificial Saliva Reservoir For The Mandibular Complete Denture. *J Prosthet Dent.* 1996;75:276-280.
14. Mendoza AR, Tomlinson MJ. The Split Denture: A New Technique for Artificial Saliva Reservoirs in Mandibular

- Dentures. Aust Dent J. 2003;48:190-194.
15. Burhanpurwala MA, Magar S, Bhandari AJ, Gangadhar SA. Management of an Edentulous Patient Having Xerostomia with Artificial Saliva Reservoir Denture. J Indian Prosthodont Soc. 2009;9:92-95.
  16. Assery MKA. Efficacy of Artificial Salivary Substitutes in Treatment of Xerostomia: A Systematic Review. J Pharm Bioallied Sci. 2019 Feb;11(1):S1-S12. DOI: 10.4103/jpbs.JPBS\_220\_18

**How to Cite This Article**

Katkade A, khalikar S, KM Mahale, Rajguru V, Mahajan S. Prosthodontic management of xerostomia in completely edentulous patient suffering from Sjogren syndrome using a fixed maxillary salivary reservoir - a case report. International Journal of Applied Dental Sciences. 2023;9(3):308-313.

**Creative Commons (CC) License**

This is an open access journal, and articles are distributed under the terms of the Creative Commons Attribution-NonCommercial-ShareAlike 4.0 International (CC BY-NC-SA 4.0) License, which allows others to remix, tweak, and build upon the work non-commercially, as long as appropriate credit is given and the new creations are licensed under the identical terms.