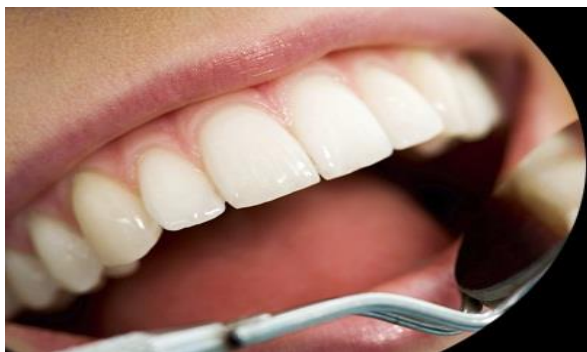



ISSN Print: 2394-7489  
ISSN Online: 2394-7497  
IJADS 2024; 10(3): 48-51  
© 2024 IJADS  
[www.oraljournal.com](http://www.oraljournal.com)  
Received: 16-05-2024  
Accepted: 20-06-2024

**Dr. Sharmista Sen**  
Post Graduate Trainee,  
Department of Periodontics,  
Guru Nanak Institute of Dental  
Sciences and Research, West  
Bengal, India

**Dr. Sanjukta Laha**  
Post Graduate Trainee,  
Department of Periodontics,  
Guru Nanak Institute of Dental  
Sciences and Research, West  
Bengal, India

**Dr. Abhijit Chakraborty**  
Professor and HOD, Department  
of Periodontics, Guru Nanak  
Institute of Dental Sciences and  
Research, West Bengal, India

**Dr. Himadri Chakrabarty**  
Professor, Department of  
Periodontics, Guru Nanak  
Institute of Dental Sciences and  
Research, West Bengal, India

**Corresponding Author:**  
**Dr. Sharmista Sen**  
Post Graduate Trainee,  
Department of Periodontics,  
Guru Nanak Institute of Dental  
Sciences and Research, West  
Bengal, India

## Periodontally accelerated osteogenic orthodontics - A paradigm shift in orthodontic treatment: A review

**Dr. Sharmista Sen, Dr. Sanjukta Laha, Dr. Abhijit Chakraborty and Dr. Himadri Chakrabarty**

DOI: <https://doi.org/10.22271/oral.2024.v10.i3a.1985>

### Abstract

In the field of orthodontics, periodontally accelerated osteogenic orthodontics (PAOO) is a relatively new procedure. It was first presented by Wilcko brothers. PAOO combines the use of orthodontic forces with specific alveolar decortications, such as bone grafting. The Regional Acceleratory Phenomenon (RAP), a pattern of bone healing, serves as the theoretical foundation for this process. PAOO is a technique that facilitates quick and simple tooth movement and may overcome many limitations of conventional orthodontics tooth movements. The aim of this article is to present a comprehensive review of the literature, including the historical background, principles of the procedure, the contemporary clinical techniques, indications and scope, contraindications, complications and side effects.

**Keywords:** Periodontally accelerated osteogenic orthodontics (PAOO), Regional Acceleratory Phenomenon (RAP), Orthodontic tooth movement (OTM), Corticotomy

### Introduction

Adult orthodontics is becoming more popular in the modern world. Increased duration of treatment <sup>[1]</sup> and increased chance of formation of hyalinization <sup>[2]</sup> are major limitations of adult orthodontic therapy. Furthermore, because adult patients' teeth are confined in rigid alveolar bone, they are more vulnerable to periodontal problems <sup>[2]</sup>. These characteristics make adult orthodontic treatment distinct and challenging, necessitating novel ideas and techniques. To meet their expectations, numerous surgical techniques have been developed to expedite orthodontic tooth movement <sup>[3]</sup>. In order to achieve fast orthodontic tooth movement (OTM), the PAOO (Periodontally Accelerated Osteogenic Orthodontics), also known as Wilckodontics <sup>[3]</sup>, approach combines periodontal regeneration and alveolar augmentation with selective decortication aided orthodontics.

The regional acceleratory phenomenon (RAP), a pattern of bone healing, serves as the theoretical foundation for this process <sup>[3]</sup>. Orthopedist Harold Frost (1989) observed that surgical wounding of osseous hard tissue produced a significant reorganization activity close to the site of injury in osseous and/or soft tissue surgery. He referred to this series of physiological healing events as the "regional acceleratory phenomenon" (RAP) <sup>[3, 4]</sup>. This article's goal is to provide a thorough analysis of the literature, taking into account the background information from history, principles of the procedure the contemporary clinical techniques, indications and scope, contraindications, complications and side effects.

### Historical Background

Since the 1800s, orthodontic tooth movement with surgical support has been performed. Henrich Kole's 1959 publication <sup>[5]</sup> laid the groundwork for the development of corticotomy-assisted orthodontics. It was believed that the main obstruction to tooth movement was the cortical plates of bone, and that orthodontic treatment could be completed much more quickly by rupturing this continuity.

He postulated this theory as "bony block movement" <sup>[3, 5]</sup>. Full thickness flaps are reflected in Kole's approach, exposing the lingual and buccal alveolar bone. Then, incisions that hardly penetrate the medullary bone were made into the cortical bone.

The whole thickness of the alveolus was penetrated by the subapical horizontal cuts, akin to an osteotomy, that joined the interdental cuts. Kole's approach was never widely used since it was so invasive.

Bell and Levy described a model of vertical interdental corticotomy that should have been considered an osteotomy, because they mobilized all dento-osseous segments [6].

Duker *et al.* [7] conducted an experiment on beagle dogs in 1975 and demonstrated that rapid tooth movement could be achieved by orthodontic appliances after weakening the bone by corticotomy. The rapid tooth movement does not affect the vitality of the teeth which have been moved.

In 1990, Gantes *et al.* reported on the use of orthodontic pressures alone to try space closure in five adult patients undergoing corticotomy-facilitated orthodontics [8].

On the other hand, Wilcko and colleagues contested the notion of "bony block movement" in 2001. Using high-resolution CT scan imagery from the hospital, they evaluated corticotomized individuals and found that the alveolar housing over the root prominences appeared to have demineralized, causing the little defined blocks of bone to lose their structural integrity. The circumscribing corticotomy cuts on the pressure and tension sides of the teeth are about where this apparent demineralization happened. Rather than "bony block movement," the initial demineralization of the alveoli and the subsequent remineralization were compatible with the cascade physiological events linked to the regional acceleratory phenomenon (RAP) [3].

A new method called Periodontally Accelerated Osteogenic Orthodontics (PAOO), which combines alveolar augmentation with selective decortication-facilitated orthodontic treatment, was recently introduced by Wilcko *et al.* in 2008. By employing bone grafts, such as decalcified freeze-dried bone allograft (DFDBA), this procedure reduces the treatment time to one-third of that of conventional orthodontic treatment [9]. It also enhances the net alveolar volume following orthodontic treatment.

This protocol also allows conventional Orthodontic Tooth Movement 300% to 400% faster, increases the envelope of movement 2- to 3-fold and alveolar augmentation (periodontally accelerated osteogenic orthodontics or PAOO), and increases alveolar volume providing an alternative to bicuspid extraction. According to a number of reports, this method is exceedingly predictable, safe, and related with a lower rate of root resorption and treatment time. In certain cases, it can even lessen the need for orthognathic surgery [10].

## Principle

Alveolar corticotomies (ACS) are surgical procedures limited to the cortical portion of the alveolar bone. Corticotomy-assisted or corticotomy-facilitated orthodontics is an orthodontic procedure that uses controlled surgical damage to speed up bone metabolism, assisting in the movement of teeth through orthodontic treatment. It is thought of as a therapeutic intermediate treatment option to both orthodontic surgery and standard orthodontics [11]. The PAOO technique involves surgically scarring the cortical bone on the labial and lingual surfaces of the teeth that need to be moved. This is followed by grafting. The patient is visited every two weeks, and the fast tooth movement that arises from PAOO differs greatly from periodontal ligament cell-mediated tooth movement. Dr. Harold Frost, an orthopedist, noted in 1989 [12] that surgical wounding of osseous hard tissue during osseous and/or soft tissue surgery results in an amazing reorganising activity close to the site of injury brought on by a localised

osteoporosis condition as a natural healing process. "Regional acceleratory phenomenon" (RAP) was the term he used to describe this set of physiological healing activities. RAP describes the local hard and soft tissue response to a surgical wound, where tissue develops faster than the usual regional regeneration process. Since trabecular bone supports and facilitates the rapid movement of teeth, it significantly increases alveolar demineralization, which causes transient osteopenia (as reported by Ferguson and colleagues) [10], [12], [13]. The orthodontic tooth movement creates an environment that is conducive to alveolar remineralization. Rich calcium deposits are released by the tissues of the alveolar bone, and after 20 to 55 days, new bone begins to mineralize. Because the bone is softer and less resistant to the stresses of the braces during this brief state of the bone, braces can move teeth quite quickly [14]. Therefore, reduced regional bone density and increased bone turnover are two key characteristics of RAP in bone healing and they are thought to promote orthodontic tooth movement [15], [16]. Osteoclastic activity is prominent on the compression side, although it is also seen on the tension side to a lesser amount. A histological investigation shows that on day 21, fibrous tissue replaces the remodelling tissues, and on day 60, bone replaces them. RAP usually lasts four months, and its resolution could take up to twenty-four months. These procedures are opening the "window" for rapid tooth movement, and because they are considered futuristic, there is interest in evaluating such surgically aided orthodontic technique [17].

## Clinical Technique

PAOO surgery is performed during the week following bracketing and arch wire activation.

After administration of local anaesthesia. The surgical technique (Figure 1) for PAOO consists of 5 steps like.

### 1) Flap elevation

If feasible, a full thickness periodontal flap is elevated on the lingual and buccal surfaces beyond the tooth apices. Longitudinal and buccal crevicular incisions are created, extending beyond the region to be treated by at least two or three teeth. To avoid the need for vertical release incisions, the flap should be stretched mesially and distally beyond the corticotomy sites. The papilla between the maxillary central incisors should be preserved on the labial and palatal aspects for cosmetic reasons [17, 18].

### 2) Decortications

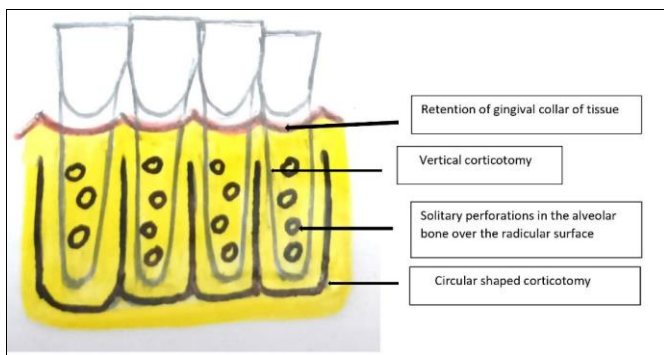
To start the RAP, decortication is applied to the labial and palatal (lingual) sides of the alveolar bone without generating moveable bone segments. Usually, in the alveolar bone, a vertical groove is positioned halfway between the root prominences in the inter radicular gap. This groove runs from a location 2 to 3 mm below the bone's crest to a point 2 mm beyond the roots' apices. A circular corticotomy is used to connect these vertical corticotomies.

1. It is taken care that the cuts don't get any closer to any neurovascular structures. Under local anesthesia, the treatment is carried out with low-speed round burs. By decorticating at clinical sites without accessing the cancellous bone during the PAOO process, underlying structures including the mandibular canal and maxillary sinus are protected from potential harm. A piezoelectric knife can also be used to perform corticotomies.

Importantly, decorticating the alveolus also promotes local angiogenesis [17, 18].

### 3) Particulate grafting

The primary benefit of using bone grafts is the combination of mechanical support, osteoconduction, and, in some situations, osteoinduction and osteogenesis [19]. In certain instances, a mixture of autograft and allograft, allograft and xenograft, or xenograft and alloplast is used to cover the exposed root surfaces and activated bone. The combination of demineralized freeze-dried bone and bovine bone treated with clindamycin was suggested by Wilcko *et al.* If there is any recession in the teeth, it can be treated at the same time with connective tissue graft or acellular dermal matrix allograft. The degree of malocclusion, pre-existing bone and crowding that must be corrected, the severity of the expected dentoalveolar defect, the number and extent of necessary osteotomies, and the degree of planned subtle facial reshaping all influence how much bone grafting material is used. According to Murphy *et al.* [18] there isn't any reliable evidence that contrasts the superiority of different grafting materials.



**Fig 1:** Schematic diagram showing surgical procedure

### 4) Closure

Non-resorbable interrupted sutures should be used to seal the flap without applying undue stress. There's no need to pack. Usually, the sutures are left in place for a week or two. Sutures are left in place for three weeks if more than 0.5 millilitres of bone graft material is used for each tooth. Opening of the interproximal embrasure, gingival recession, and flap displacement might result from premature suture removal [18].

### 5) Orthodontic force application

The week before to the surgical part of PAOO, the orthodontic brackets are placed and the arch wires are activated. Heavy orthodontic force can be administered to the teeth right away after the flap is repositioned; in any situations, orthodontic force application shouldn't be postponed for longer than two weeks following surgery. A lengthier delay will not allow for the full benefit of the little window of time during which the RAP is taking place. Arch wires are quickly advanced, and every two weeks, adjustments are done [18].

Munoz *et al.* [20] combined PRF with PAOO surgery to monitor the clinical outcomes for pain and edema in an observational cohort research. PRF offers several useful advantages, including easier preparation, increased stability of the grafting mixture, and exposure protection [19]. Antibiotics, analgesics, and steroids are recommended for a brief period of

time in order to improve clinical healing and patient comfort. On the other hand, because NSAIDs are thought to interfere with the RAP, long-term postoperative NSAID therapy is discouraged. It is advised to apply icepacks postoperatively to reduce oedema and swelling. The most often reported postsurgical sequelae, which are often not difficult for the clinician to manage, include oedema, ecchymosis, and mild discomfort [18].

### Discussion

Several indications and clinical applications for PAOO have been reported. They are effective in resolving crowded dentition and reduces treatment time. They can accelerate canine retraction after premolar extraction. Post-orthodontic stability can be enhanced. They are effective in facilitating eruption of impacted teeth, slow orthodontic expansion, molar intrusion and open bite correction. PAOO can be a conservative alternative to traditional orthognathic surgery [10, 14, 16].

This novel treatment method holds several advantages like, the treatment time is relatively lesser compared to conventional treatment (3-4 times), less risk of post orthodontic gingival recession and subsequent cervical abrasion. There is greater post orthodontic stability and retention, decreased risk of root resorption. Compared to typical orthodontic treatment, teeth movement causes less discomfort since teeth are moving through softer bone. PAOO treatment has less furcation invasion, less relapse and it facilitates eruption of impacted teeth [10, 14, 16].

Some contraindications and limitations are also noted. PAOO is contraindicated in individuals who have previous gingival recession or active periodontal disease and in patients under prolonged corticosteroid therapy. When treating severe posterior cross-bite, surgically aided palatal expansion is the preferred method than this novel technique. PAOO also should not be used in cases where bimaxillary protrusion is accompanied with a gummy smile, which might benefit more from segmental osteotomy. They are contraindicated in persons under long term medications that slows down bone metabolism, such as bisphosphonates and NSAIDs. There are certain disadvantages also like increased cost of treatment. It is a mildly invasive surgical procedure, and like all surgeries, it has its risks like mild to moderate pain, swelling and the possibility of infection [21, 22].

There was no documented impact on the viability of the tooth pulps in the corticotomy area. No evaluation of long-term pulpal vitality following such treatment has been published in the literature [22]. In an animal study, Liou *et al.* [23] showed normal pulp viability subsequent to such fast tooth movement at a weekly rate of 1.2 mm. It is proved that a longer applied force duration was correlated with higher root resorption [22].

The reduced treatment duration of PAOO may reduce the risk of root resorption. Ren *et al.* [24] observed quick tooth movement following a corticotomy in beagles without any associated irreversible pulp damage or root resorption. Moon *et al.* [25] used corticotomy in conjunction with a skeletal anchorage system that prevented root resorption to report an adequate and safe maxillary molar intrusion (3.0 mm intrusion in two months). Research on the long-term impact of PAOO on root resorption is necessary.

### Conclusion

Due to this revolutionary process, greater range of treatment possibilities and significantly quicker treatment duration, both doctors and patients are beginning to favour it more and more.

It has developed over time into a viable treatment option when used appropriately for a range of orthodontic difficulties, including complicated cases that necessitate an interdisciplinary approach from multiple dental specialties. Treatment planning may be difficult in complex situations, and more criteria would be required to completely apply this strategy. If guidelines are followed judiciously, the PAOO technique can effectively replace conventional orthodontic therapy and can bring about a paradigm shift in the orthodontic treatment process.

## References

- Rappaport TG, Shalis MH, Gazit E. Psychosocial reward of orthodontic treatment in adult patients. *Eur J Orthod.* 2010;32(4):441-446.
- Ong MM, Wang HL. Periodontic and orthodontic treatment in adults. *Am J Orthod Dentofacial Orthop.* 2002;122:420-428.
- Wilcko WM, Wilcko MT, Bouquot JE. Rapid orthodontics with alveolar reshaping: two case reports of decrowding. *Int J Periodontics Restorative Dent.* 2001;21:9-19.
- Yaffe A, Fine N, Binderman I. Regional accelerated phenomenon in the mandible following mucoperiosteal flap surgery. *J Periodontol.* 1994;65:79-83.
- Kole H. Surgical operation on the alveolar ridge to correct occlusal abnormalities. *Oral Surg Oral Med Oral Pathol.* 1959;12:515-529.
- Shrisha K, Rao P, Satyaprakash, Panduranga H. Wilckodontics - A novel synergy in time to save time. *J Clin Diagn Res.* 2014;8(1):322-325.
- Duker J. Experimental animal research into segmental alveolar movement after corticotomy. *J Maxillofac Surg.* 1975;3:81-84.
- Gantes BG, Rathbun ES, Anholm JM. Effects on the periodontium following corticotomy-facilitated orthodontics: case reports. *J Periodontol.* 1990;61:234-238.
- Wilcko MT, Wilcko WM, Pulver JP, Bissada NF, Bouquot JE. Accelerated osteogenic orthodontics technique: a 1-stage surgically facilitated rapid orthodontic technique with alveolar augmentation. *J Oral Maxillofac Surg.* 2009;67:2149-2159.
- Wilcko MT, Wilcko WM, Bissada NF. An evidence-based analysis of periodontally accelerated orthodontic and osteogenic techniques: a synthesis of scientific perspective. *Semin Orthod.* 2008;14:305-316.
- Sagane V, Kangane S, Ambekar A, Marure P, Joshi Y, Khanapure C. Periodontally Accelerated Osteogenic Orthodontics: The Past and the Future. *Int J Oral Health Med Res.* 2016;15(1):9-14.
- Frost HM. The regional acceleratory phenomenon: A review. *Henry Ford Hosp Med J.* 1983;31:3-9.
- Frost HM. The biology of fracture healing. An overview for clinicians. Part I. *Clin Orthop Relat Res.* 1989 Nov;(248):283-93.
- Nowzari H, Yorita FK, Chang HC. Periodontally Accelerated Osteogenic Orthodontics Combined with Autogenous Bone Grafting. *Compend Contin Educ Dent.* 2008;29(4):216-223.
- Goldie RS, King GJ. Root resorption and tooth movement in orthodontically treated, calcium-deficient, and lactating rats. *Am J Orthod.* 1984;85(5):424-430.
- Wilcko WM, Ferguson DJ, Bouquot JE. Rapid orthodontic decrowding with alveolar augmentation: case report. *World J Orthod.* 2003;4:197-205.
- Singh P, Sachdeva K, Jadon AK, Manchanda M, Ali SA, Shamim W. Wilcodontics or Periodontally Accelerated Osteogenic Orthodontics: A Review. *Int J Prev Clin Dent Res.* 2014;1(4):72-75.
- Murphy KG, Wilcko MT, Wilcko WM, Ferguson DJ. Periodontal accelerated osteogenic orthodontics: a description of the surgical technique. *J Oral Maxillofac Surg.* 2009;67:2160-166.
- Indurkar MS, Krishna SJ, Sindhuja SK. Surgical considerations in periodontally accelerated osteogenic orthodontics with platelet-rich fibrin: A series of 2 case reports. *Int J Appl Dent Sci.* 2023;9(2):351-356.
- Munoz F, Jiménez C, Espinoza D, Vervelle A, Beugnet J, Haidar Z. Use of leukocyte and platelet-rich fibrin (LPRF) in periodontally accelerated osteogenic orthodontics (PAOO): Clinical effects on edema and pain. *J Clin Exp Dent.* 2016, 8(2).
- Lee JK, Chung KR, Baek SH. Treatment outcomes of orthodontic treatment, corticotomy-assisted orthodontic treatment, and anterior segmental osteotomy for bimaxillary dentoalveolar protrusion. *Plast Reconstr Surg.* 2007;120:1027-1036.
- Amit G, Kaur JPS, Bansal P, Singh S, Bhatia P. Periodontally accelerated osteogenic orthodontics (PAOO) - a review. *J Clin Exp Dent.* 2012, 4(5).
- Liou EJ, Figueroa AA, Polley JW. Rapid orthodontic tooth movement into newly distracted bone after mandibular distraction osteogenesis in a canine model. *Am J Orthod Dentofacial Orthop.* 2000;117:391-398.
- Ren A, Lv T, Kang N, Zhao B, Chen Y, Bai D. Rapid orthodontic tooth movement aided by alveolar surgery in beagles. *Am J Orthod Dentofacial Orthop.* 2007;131:160.e1-10.
- Moon CH, Wee JU, Lee HS. Intrusion of overerupted molars by corticotomy and orthodontic skeletal anchorage. *Angle Orthod.* 2007;77:1119-1125.

### How to Cite This Article

Sen S, Laha S, Chakraborty A, Chakraborty H. Periodontally accelerated osteogenic orthodontics - A paradigm shift in orthodontic treatment: A review. *International Journal of Applied Dental Sciences.* 2024; 10(3): 48-51.

### Creative Commons (CC) License

This is an open access journal, and articles are distributed under the terms of the Creative Commons Attribution-NonCommercial-ShareAlike 4.0 International (CC BY-NC-SA 4.0) License, which allows others to remix, tweak, and build upon the work non-commercially, as long as appropriate credit is given and the new creations are licensed under the identical terms.