



ISSN Print: 2394-7489  
ISSN Online: 2394-7497  
IJADS 2024; 10(3): 44-47  
© 2024 IJADS  
[www.oraljournal.com](http://www.oraljournal.com)  
Received: 06-05-2024  
Accepted: 08-06-2024

**Dr. Aditya Kumar**  
Post graduate student,  
Dept of Conservative and  
endodontics, Kanti Devi Dental  
College and Hospital, Uttar  
Pradesh, India

**Dr. Ajay Kumar Nagpal**  
Head of Department,  
Conservative and Endodontics,  
Kanti Devi Dental College and  
Hospital, Uttar Pradesh, India

**Dr. Mutiur Rahman**  
Senior Lecture,  
Department of Conservative and  
Endodontics, Kanti Devi Dental  
College and Hospital, Uttar  
Pradesh, India

**Dr. Nima Wangziom Mosobi**  
Post Graduate Student,  
Department of Conservative and  
Endodontics, Kanti Devi Dental  
College and Hospital, Uttar  
Pradesh, India

**Dr. Snehil**  
Post Graduate Student,  
Department of Conservative and  
Endodontics, Kanti Devi Dental  
College and Hospital, Uttar  
Pradesh, India

**Corresponding Author:**  
**Dr. Aditya Kumar**  
Post graduate student,  
Dept of Conservative and  
endodontics, Kanti Devi Dental  
College and Hospital, Uttar  
Pradesh, India

## **Ellis class IV fracture with open apex: A one-year follow-up case report of management with MTA apexification and Ribbond post**

**Dr. Aditya Kumar, Dr. Ajay Kumar Nagpal, Dr. Mutiur Rahman, Dr. Nima Wangziom Mosobi and Dr. Snehil**

**DOI:** <https://doi.org/10.22271/oral.2024.v10.i3a.1984>

### **Abstract**

The management of immature, avascular dentition with patent apices presents a therapeutic challenge. Conventional obturation techniques necessitate precise material confinement within the canalicular confines to avoid periapical extrusion. Apexification offers a solution by promoting the formation of a hard-tissue barrier, facilitating subsequent root canal filling. This case report exemplifies the application of mineral trioxide aggregate for apical plug formation, followed by definitive restoration of the compromised coronal structure with ribbond and composite.

**Keywords:** Ellis class IV Fracture, Immature tooth, MTA Apexification, Ribbond post and core-buildup, Open Apex

### **Introduction**

Traumatic dental injuries often comprise the majority of face injuries. While severe oral injuries can occur to anyone at any age, thirty percent of these injuries occur in youngsters [1]. Most of these injuries occur prior to the completion of root growth [2]. The tooth is left susceptible with a weakened crown to root ratio due to an immature apex with weak dentin walls and an early loss of essential pulp [3]. Traumatic dental injuries in young children can cause pulpal necrosis, which can stop further root development and result in the development of open apices. Severe resorption of a mature apex following orthodontic therapy or periradicular inflammation are two further factors contributing to an open apex [4].

Both blunderbuss and non-blunderbuss open apices exist. An example of an open apex is a non-blunderbuss, in which the apex is mainly convergent and the walls are parallel to slightly convergent as the canal exits the root. Another is the blunderbuss, which has funnel-shaped apex wider than coronal aspect and divergent and flaring walls, particularly in the buccolingual direction. Incomplete development, large apices, and pulp necrosis brought on by trauma or caries before the completion of root formation [5].

Because it is difficult to debride, clean, and attain the proper closure of the root canal space, managing an open apex case presents challenges for the physician. There is no barrier to stop the root canal filling material from penetrating and harming the peri-apical tissues since the apex has not fully grown. Because of the weak dentinal walls, fractures of the root can happen both during and after treatment. The resolution of these issues involves promoting the development of a calcific barrier to facilitate sufficient root canal filling. Additionally, this calcific barrier aids in fortifying the feeble root structure [1].

In order to achieve apical healing, apexification is an endodontic procedure in which the apex of an exposed tooth is covered with a calcific barrier. Usually, non-vital pulp in permanent teeth with an open apex are treated with this treatment. For endodontic treatment to be effective over the long term, the root canal system must be completely cleaned, shaped, and then homogeneously obturated. There are instances where the absence of apical constriction is problematic, such as during the growth of teeth. Creating an apical stop or barrier is one of the objectives of endodontic therapy in order to prevent excessive extrusion when placing root canal filling material against it [6].

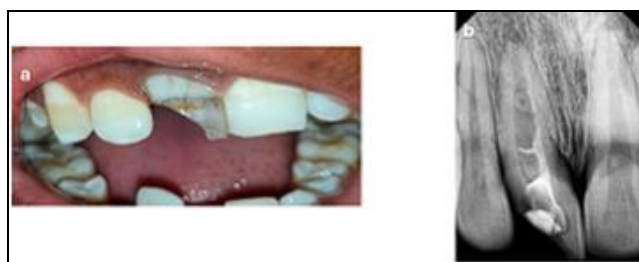Different materials are used in different ways all around the world to promote the establishment of the root end barrier. In the past, materials like as "calcium hydroxide, freeze-dried allogenic dentin powder, bone ceramic, tricalcium phosphate, osteogenic protein, collagen, calcium gel, and most recently mineral trioxide aggregate (MTA) and Biodentine" have been used to treat teeth with open apices [7]. MTA has proven to be an extremely successful root-filling material when it comes to sealing young root canals with exposed apices, which may provide technical challenges for achieving the correct obturation. Hard tissue formation, which facilitates peri-radicular healing, can be encouraged by MTA [8]. MTA is significant since it reduces appointment durations and may allow apexification in a single visit. An enduring apical barrier is supplied by the MTA [8].

Ribbon features a triaxial braided structure with a three-dimensional leno-weaved structure that allows composite resin to mechanically interlock in several planes.

In this instance, there is no visible mobile fracture fragment, but the fracture line is continuing obliquely towards the cervical region. A direct fibre reinforced composite resin is utilised to restore the intraarticular region of the tooth because it offers sufficient strength to resist fracture from excessive force.

### Case Presentation

In the "Department of Conservative Dentistry and Endodontics, K. D. Dental College, Mathura," a male patient, age 21, presented with the main complaint of a discoloured and cracked tooth in the upper right front region of her jaw. The patient described a fall-related trauma that occurred around eleven years ago. The patient didn't appear to be in any pain or swelling. A discoloured tooth with an Ellis Class IV fracture with 11 where the fracture line involved the pulp chamber without mobility was revealed by the clinical study (Figure 1a). The patient provided a history of starting root canal therapy at a nearby physician fifteen days prior.



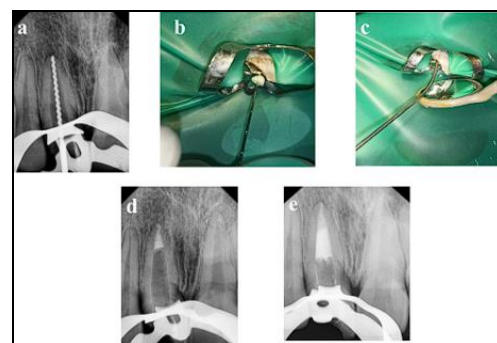
**Fig 1:** a) Pre-operative clinical of Ellis class IV fracture with 11. b) Pre-operative radiograph show in g wide open apex

No response was seen with 11 by the neural sensibility (electronic pulp tester) test. The radiographic investigation presented a "immature tooth with an open apex with mild radiolucency" around the periapical region (Figure 1b). Hence, the final diagnosis for this case was "pulpal necrosis with asymptomatic apical periodontitis with 11. Presence of radio opaque material in coronal region of tooth.

### Treatment

Formal consent was obtained after describing the treatment strategy to the patient. Access opening was carried out on the initial visit utilizing an "endo access bur #1 (Dentsply, Pennsylvania, US)" "under local anesthesia and rubber dam (GDC) isolation. As the canal was wide using a #70 K file (Mani, Brussels, Belgium)," determination of working length was done and was verified utilizing radiovisiography (RVG)

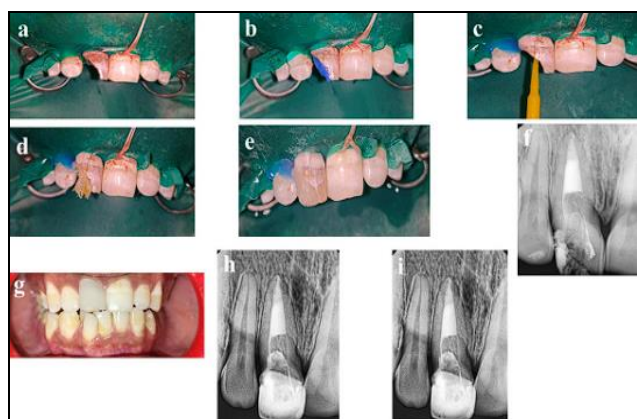
(Figure 2a). The root canal was lightly cleaned with a hand file under irrigation with 3% NaOCl. The root canal was then dried with sterile paper points. Calcium hydroxide was placed in the root canal, and the tooth was then temporarily sealed and the patient was recalled after a week. One week later, the tooth was again isolated under rubber dam, the calcium hydroxide dressing was removed by hand instrumentation, and irrigation was done with 3% NaOCl and 17% liquid EDTA Smear Clear (SybronEndo, CA, USA). After drying the root canal, a fragment of collagen sponge (Hemospon; Technew, Rio de Janeiro, RJ, BR) was introduced and adapted in the apical third of the root canal with the aid of a #3 gutta-percha condenser (Figure 2b). Immediately after compaction of the collagen sponge, MTA (Angelus, Londrina, PR, BR) was mixed according to the manufacturer instructions and apical barrier was placed, in approximately 4 mm thickness in the apical third of the root canal with a MTA Carrier (GDC MTA Carrier # Curved 0.8 mm) (Figure 2c). A new radiography was taken to verify the homogeneity of the apical plug. (Figure 2d). Moistened gauze was placed in the remainder of the canal and the access cavity sealed with temporary restorative material cavitated for 24 hour. Next temporary restorative material removed and rubber dam placed and sectional obturation using Gutta percha Fast Fill obturation system (Eighteenth Changzhou Sifary Medical Technology Co., Ltd) (Figure 2e).



**Fig 2:** A new radiography was taken to verify the homogeneity of the apical plug

Polyethylene fiber-reinforced composite resin used as a post ribbon (NT stick-on fiber). Root canal walls and remaining dentin surfaces were etched with 37% phosphoric acid (Safe endo smart etch etchant) (Figure 3 b) for 15 s, washed for 30 s, and then gently air dried. Excess water was removed, and an adhesive system (3M single bond universal bonding agent) was applied to the canal in 2 consecutive coats using a microbrush and then gently air-dried to evaporate the solvent (Figure 3 c). The Ribbon was wetted with Single Bond adhesive (3M single bond universal bonding agent) and protected from exposure to light until ready for use. A flowable composite (ReCreate-LC Flow, safe endo radiolucent) was used to lute the Ribbon post. To increase the amount of reinforcing material and reduce the amount of cement, the prepared length of Ribbon reinforcing fiber was folded and inserted into the canal, with the protruding ends of the Ribbon folded back into the canal to fill it with the greatest volume of tape possible. The Ribbon was adjusted such that it extended 2 mm outside of the canal and was cured for 20 s using an LED curing unit (Woodpecker iLED Plus Light Cure Unit) (Figure 3 d). Shade selection and composite core build-up were done using resin composite (3M Filtek Z 250) (Figure 3 e). The occlusion was checked, and the final finishing and polishing was performed using diamond burs

and radiograph was taken (Figure 3 f). Direct composite (3M Filtek Z 250) veneer was done on next visit (Figure 3 g). Patient was recalled for follow-up 6 months (Figure 3 h) and 1 year (Figure 3 i).



**Fig 3:** Shade selection and composite core build-up were done using resin composite (3M Filtek Z 250)

### Discussion

The teeth that break the most often in permanent dentition are the maxillary incisors. Teenagers are primarily responsible for dental injuries since they play contact sports<sup>[9]</sup>. An Ellis class IV fracture is a non-vital tooth that has experienced stress and may or may not have lost crown structure. Acute pulpal inflammation and the possibility of microorganisms entering dentinal tubules are both increased by severe tooth injury<sup>[10]</sup>. In this case, the open cavity has been left untreated for a very long time, which causes more dentin demineralization. More of the contaminated soft dentin was removed during the shaping and cleaning of the root canal.

The primary challenge in treating a wide-open apex is limiting the material to avoid excessive extrusion into the periodontal tissue. Using a matrix helps prevent this, reduces the permeability of sealing material, and encourages a positive tissue response<sup>[11]</sup>. Various materials have been used to create the apical barrier during apexification, with calcium hydroxide being the preferred choice due to its effectiveness in forming an apical calcific barrier. However, its long induction period and the potential for increased brittleness of the root canal walls with prolonged use limit its application. MTA is a promising alternative, offering predictable results by forming a hard-tissue barrier that helps maintain proper peri-radicular architecture<sup>[12]</sup>. MTA is considered an excellent material for apexification due to its high biocompatibility, ability to set in the presence of blood, and potential for quick tooth restoration without compromising the mechanical properties of dentin<sup>[12-14]</sup>.

Many researchers have validated the effectiveness of MTA in various dental treatments, including apexification<sup>[15-18]</sup>. Muhamad *et al.* found that MTA stimulates bone and cementum formation while causing less inflammation compared to other materials<sup>[19]</sup>. Studies on human osteoblasts indicate that MTA enhances bone cell growth, leading to cytokine secretion, which in turn regulates bone metabolism, suggesting that MTA supports hard tissue formation. Clinical studies report apexification success rates with MTA at 76.5% and 91%<sup>[20]</sup>. Torabinejad and Chivian recommend using calcium hydroxide during the first week to manage bleeding from the periapical region before applying MTA. Additionally, the researchers in this study employed a calcium hydroxide disinfection insert<sup>[21]</sup>.

Collagen is a molecule characterized by its high content of diamino dicarboxylic amino acids and carbohydrate moieties, making it hydrophilic and conducive to cell adhesion. Collagen sponges form a 3-dimensional structure with large pores, inter-canal connections, and macromolecular combinations of connective tissue, which enhance scar tissue infiltration and cell growth *in vivo*<sup>[22]</sup>. These sponges are used in treating teeth with immature apices because they are both structurally and functionally effective in wound repair and easy to apply. They can be placed in the apical radicular third with a gutta-percha condenser or endodontic file, absorb moisture, expand, and act as a hemostatic agent<sup>[23]</sup>. Depending on the degree of cross-linking, collagen materials fully resorb within 14 to 56 days<sup>[22]</sup>. The collagen barrier prevents the extrusion of the MTA apical plug and protects MTA from tissue fluids and blood during plug insertion<sup>[24]</sup>.

Fibre-reinforced composite (FRC) is a biocompatible, bondable, translucent, aesthetic, and easy-to-use material favored in dentistry for its diverse properties. Recently, a new polyethylene fiber-reinforced material with bondable ultra-high strength fibers has been introduced as a substitute for traditional cast post materials. This material offers excellent mechanical properties, aesthetic qualities, and color matching<sup>[25]</sup>. Unlike prefabricated fiber posts, which are difficult to adapt, this material has an open, lace-like structure that conforms closely to the contours of teeth. It can be condensed with minimal micro-leakage and increases the load-bearing capacity of restorations while preventing crack propagation from the restoration to the tooth. This makes it a suitable alternative for use as post and core in endodontically treated teeth. Additionally, it preserves tooth strength by eliminating the need for further tooth structure removal, reducing the risk of root fractures and perforations. The material adapts to the root canals' undercuts and contours, providing mechanical retention and preventing stress accumulation at the tooth-post interface. This polyethylene post core (Ribbond) is both inactive and highly retentive, and its translucent fibers allow natural light conduction through crowns, resulting in an aesthetically pleasing appearance. It combines translucency, durability, adaptability, and resistance to impact and traction<sup>[26]</sup>.

Polyethylene woven ribbon fibers have resolved issues with older reinforcement forms. Ribbond, made of ultra-high-molecular-weight polyethylene fiber, has an ultra-high modulus and is treated with cold gas plasma to improve bonding to restorative materials. Its special fiber network efficiently transfers forces acting upon it. Additionally, the technique is quick, easy to use, and requires no laboratory work. It is highly aesthetic due to its translucency and can be light-cured<sup>[27]</sup>.

It's important to note that the success and timing of apex closure depend on several factors, including the material used, treatment process, accurate diagnosis, instrumentation technique, and root canal disinfection. The patient's overall health also plays a crucial role in their ability to regenerate periodontal structures. Our findings suggest that MTA can be used in apexification with excellent results. The patient will be regularly monitored to assess progress.

### Conclusion

One-year follow-up revealed adequate function, absence of clinical symptoms, and reduced periapical rarefaction. So here we used MTA as an apical plug and achieved good clinical outcome, which is quite encouraging.

**Conflict of Interest**

Not available

**Financial Support**

Not available

**Reference**

- Moore A, Howley MF, O'Connell AC. Treatment of open apex teeth using two types of white mineral trioxide aggregate after initial dressing with calcium hydroxide in children. *Dent Traumatol.* 2011;27:166-73.
- Trope M. Treatment of the immature tooth with a non-vital pulp and apical periodontitis. *Dent Clin North Am.* 2010;54:313-24.
- Ahlawat B, Kumar A, Chaudhary N, Bhardwaj V. Apexification with rapid MTA plug technique. *Indian J Sci Res.* 2015;6:153-156.
- Pawar RB, Margsayam SV, Shenoy VU, Shaikh SAH. Management of a traumatized open apex tooth with a combination of mineral trioxide aggregate apical plug and platelet-rich fibrin apical matrix. *J Contemp Dent.* 2016;6:57-62.
- Jain JK, Ajagannavar SL, Jayasheel A, Bali PK, Jain CJ. Management of a fractured nonvital tooth with open apex using mineral trioxide aggregate as an apical plug. *Int J Oral Health Sci.* 2017;7:44-47.
- Pattanaik S, Mohapatra S, Singh NR, Kumari KS. Management of open apex using alternative techniques: series of 3 case reports. *Indian J Forensic Med Toxicol.* 2020;14:8333-8337.
- Muhamad A-H, Abdulgani A, Abdulgani M. Open apex with mineral trioxide aggregate: case report [PREPRINT]. *IOSR J Dent Med Sci;* c2016. DOI: 10.9790/0853-1510078187.
- Khetarpal A, Chaudhry S, Talwar S, Verma M. Endodontic management of open apex using MTA and platelet-rich fibrin membrane barrier: A newer matrix concept. *J Clin Exp Dent.* 2013;5.
- Pace R, Giuliani V, Pini Prato L, Baccetti T, Pagavino G. Apical plug technique using mineral trioxide aggregate: results from a case series. *Int Endod J.* 2007;40:478-84. DOI: 10.1111/j.1365-2591.2007.01240.x.
- Bastone EB, Freer TJ, McNamara JR. Epidemiology of dental trauma: A review of the literature. *Aust Dent J.* 2000;45:2-9. DOI: 10.1111/j.1834-7819.2000.tb00234.x.
- Traebert J, Peres MA, Blank V, Böell Rda S, Pietruza JA. Prevalence of traumatic dental injury and associated factors among 12-year-old school children in Florianópolis, Brazil. *Dent Traumatol.* 2003;19:15-8. DOI: 10.1034/j.1600-9657.2003.00138.x.
- Giuliani V, Baccetti T, Pace R, Pagavino G. The use of MTA in teeth with necrotic pulps and open apices. *Dent Traumatol.* 2002;18:217-21. DOI: 10.1034/j.1600-9657.2002.02107.x.
- Maroto M, Barbería E, Planells P, Vera V. Treatment of a non-vital immature incisor with mineral trioxide aggregate (MTA). *Dent Traumatol.* 2003;19:165-9. DOI: 10.1034/j.1600-9657.2003.00106.x.
- Shabahang S, Torabinejad M. Treatment of teeth with open apices using mineral trioxide aggregate. *Pract Periodontics Aesthet Dent.* 2000;12:315-20; quiz 322.
- Torabinejad M, Hong CU, McDonald F, Pitt Ford TR. Physical and chemical properties of a new root-end filling material. *J Endod.* 1995;21:349-53. DOI: 10.1016/S0099-2399(06)80967-2.
- Camilleri J. Characterization and chemical activity of Portland cement and two experimental cements with potential for use in dentistry. *Int Endod J.* 2008;41:791-9. DOI: 10.1111/j.1365-2591.2008.01439.x.
- Camilleri J. Characterization of hydration products of mineral trioxide aggregate. *Int Endod J.* 2008;41:408-17. DOI: 10.1111/j.1365-2591.2007.01370.x.
- Karabucak B, Li D, Lim J, Iqbal M. Vital pulp therapy with mineral trioxide aggregate. *Dent Traumatol.* 2005;21:240-3. DOI:10.1111/j.1600-9657.2005.00306.x.
- Muhamad DA-H, Azzaldeen DA, Mai DA, Jabareen A. Single-step apexification with mineral trioxide aggregate (MTA) - case reports. *IOSR Int J Dent Med Sci.* 2016;15:49-53. DOI :10.9790/0853-15284953.
- Holden DT, Schwartz SA, Kirkpatrick TC, Schindler WG. Clinical outcomes of artificial root-end barriers with mineral trioxide aggregate in teeth with immature apices. *J Endod.* 2008;34:812-817. DOI: 10.1016/j.joen.2008.04.010.
- Torabinejad M, Chivian N. Clinical applications of mineral trioxide aggregate. *J Endod.* 1999;25:197-205. DOI: 10.1016/S0099-2399(99)80142-3.
- Mahesh L, Kurtzman GM, Shukla S. Regeneration in periodontics: collagen - a review of its properties and applications in dentistry. *Compend Contin Educ Dent.* 2015;36:358-63.
- Vanka A, Ravi K, Shashikiran N. Apexification with MTA using internal matrix: report of 2 cases. *J Clin Pediatr Dent.* 2010;34:197-200.
- Gharechahi M, Ghoddusi. A nonsurgical endodontic treatment in open-apex and immature teeth affected by dens invaginatus: using a collagen membrane as an apical barrier. *J Am Dent Assoc.* 2012;143:144-8.
- Sholapurmath SM, Anand S. Use of polyethylene fiber in pediatric esthetics - clinical reports of two cases. *J Int Oral Health.* 2010;2:99-104.
- Patil A, Aparna A. Esthetic rehabilitation of a crown fracture with glass fiber-reinforced posts: a case report. *Int J Sci Res Pub.* 2012;2:1-3.
- Ferreira MC, Kummer TR, Vieira RS, Calvo MC. Short resin posts bonding to primary dentin. Microleakage and micro-morphological *in vitro* study. *J Clin Pediatr Dent.* 2007;31:202-6.

**How to Cite This Article**

Kumar A, Nagpal AK, Rahman M, Mosobi NW, Snehil. Ellis class IV fracture with open apex: A one-year follow-up case report of management with MTA apexification and ribbon post. *International Journal of Applied Dental Sciences.* 2024;10(3):44-47.

**Creative Commons (CC) License**

This is an open-access journal, and articles are distributed under the terms of the Creative Commons Attribution-Non Commercial-Share Alike 4.0 International (CC BY-NC-SA 4.0) License, which allows others to remix, tweak, and build upon the work non-commercially, as long as appropriate credit is given and the new creations are licensed under the identical terms.