



ISSN Print: 2394-7489  
ISSN Online: 2394-7497  
IJADS 2024; 10(3): 93-96  
© 2024 IJADS  
[www.oraljournal.com](http://www.oraljournal.com)  
Received: 04-05-2024  
Accepted: 03-06-2024

**Dr. Bhawna Saxena**  
Final Year PG, Dept. of  
Pediatric and Preventive  
Dentistry, ITS Dental College  
Hospital and Research Centre  
Greater, Noida, Uttar Pradesh,  
India

**Dr. Mousumi Goswami**  
Prof. and Head, Dept. of  
Pediatric and Preventive  
Dentistry, ITS Dental College  
Hospital and Research Centre  
Greater, Noida, Uttar Pradesh,  
India

**Dr. Aditya Saxena**  
Prof. Dept. of Pediatric and  
Preventive Dentistry, ITS  
Dental College Hospital and  
Research Centre Greater, Noida,  
Uttar Pradesh, India

**Dr. Sanjesh VasuPadha**  
Second Year PG Dept. of  
Pediatric and Preventive  
Dentistry, ITS Dental College  
Hospital and Research Centre  
Greater, Noida, Uttar Pradesh,  
India

**Dr. Shivya Tuli**  
Department of Pediatric and  
Preventive Dentistry, ITS  
Dental College Hospital and  
Research Centre, Greater Noida,  
Uttar Pradesh, India

**Dr. Supriya Bhatara**  
Department of Pediatric and  
Preventive Dentistry, ITS  
Dental College Hospital and  
Research Centre, Greater Noida,  
Uttar Pradesh, India

**Corresponding Author:**  
**Dr. Bhawna Saxena**  
Final Year PG, Dept. of  
Pediatric and Preventive  
Dentistry, ITS Dental College  
Hospital and Research Centre  
Greater, Noida, Uttar Pradesh,  
India

## Management of space loss in mixed dentition using open coil space Regainer: A case report

**Dr. Bhawna Saxena, Dr. Mousumi Goswami, Dr. Aditya Saxena and Dr. Sanjesh VasuPadha, Dr. Shivya Tuli and Dr. Supriya Bhatara**

**DOI:** <https://doi.org/10.22271/oral.2024.v10.i3b.1989>

### Abstract

**Introduction:** This case report highlights the application of an open coil spring space regainer (OCSR) in a pediatric patient with space deficiency during mixed dentition. The use of OCSR in managing space issues is not extensively documented, making this case significant in demonstrating its effectiveness and contributing to the understanding of fixed space retainers in pediatric orthodontics.

**Clinical findings:** An eight-year-old boy presented with multiple missing teeth in the lower right and left posterior regions. Clinical examination revealed space loss in the lower left premolar region due to adjacent tooth migration. Model analysis indicated a 5mm space deficiency for the eruption of the first premolar. Further investigations included intraoral photographs and OPG radiographs showing previously treated teeth and space loss.

**Diagnosis & Outcomes:** The diagnosis was space deficiency due to the migration of adjacent teeth following the premature loss of primary molars. The therapeutic intervention involved the use of a fixed open coil spring space regainer to recover the lost arch space. The treatment was successful, with 5mm of space regained within four and a half months. Follow-up at 6 and 12 months showed the successful eruption of the first and second premolars.

**Conclusion:** The case underscores the effectiveness of fixed open coil spring space retainers in managing space deficiencies in mixed dentition. The successful use of OCSR demonstrates its reliability and practical benefits over removable appliances, highlighting its value in preventing malocclusion and ensuring proper alignment of permanent teeth in pediatric patients.

**Keywords:** Space retainers, space loss, pediatric dentistry, Interceptive orthodontics

### Introduction

The shift from primary to permanent dentition is a multifaceted and detailed process. It includes the shedding of primary teeth, the emergence of permanent teeth, and the formation of occlusion. This transformation occurs through an independent yet harmonious sequence, influenced by various morphogenetic and environmental factors. Any disruption or deviation in these factors can significantly impact occlusal development. Primary teeth play a crucial role in this transition, as their physiological exfoliation facilitates alveolar growth, thereby creating the necessary space for the proper accommodation of successor permanent teeth<sup>[1]</sup>.

Interceptive orthodontics is a crucial component of dental practice, concentrating on the timely management of adverse features in developing occlusion. It involves identifying and addressing potential irregularities and malpositions in the developing dentofacial complex<sup>[2]</sup>. During the mixed dentition period, managing space, especially regaining lost space, presents significant challenges. In instances where premature loss of deciduous molars occurs, and space maintenance is not adequately performed, interceptive orthodontic procedures involving space retainers become essential<sup>[3]</sup>.

The primary goal of space regaining is to recover the lost arch width and perimeter, ensuring proper alignment and spacing of the teeth. This case report discusses the application of a fixed space regainer equipped with an open coil spring, for effective space regaining. The concept of coil springs, introduced in 1975, revolutionized orthodontic treatment due to their unique properties<sup>[4]</sup>. These springs maintain a constant load value throughout a deflection zone, producing light, continuous forces over an extended range of activation<sup>[5]</sup>. Although the

forces generated by coil springs are slightly below the optimal range of 75-100 grams, they deliver consistent force over a 7mm tooth movement range with minimal activations [6].

Despite their benefits, there are limited case reports or evidence documenting the use of Open Coil Space Regainers (OCSR). Therefore, this case report is significant in providing evidence-based results. This report presents a detailed case study of space regaining using the open coil spring, highlighting the clinical considerations, treatment planning, procedural steps, and outcomes. By examining this case, we aim to provide insights into the practical application and effectiveness of open coil springs in space regaining of pediatric patients, contributing valuable knowledge to contemporary pediatric and interceptive orthodontic practice

### Case Presentation

An eight year-old boy reported to the Department of Pediatric and Preventive Dentistry with a chief complaint of multiple missing teeth in lower right and left back region of the jaw for the past 6-7 months. Medical history was noncontributory. Dental history revealed that the patient had undergone extraction of the left first primary molar due to dental caries, two years ago, root canal treatment of the lower left first permanent molar 5 months back, and pulpectomy with respect to the lower right second primary molar 6 month back. On intra-oral examination [Figure 1 (b-c)], the patient was in his mixed dentition, space loss in the lower left premolar region was observed due to migration of the adjacent tooth into the available primary molar space. Intraoral examination also revealed a stainless steel crown wrt lower left first permanent molar and restorations wrt lower right primary second molar. Further investigation using OPG revealed previously completed- pulpectomy wrt lower right primary second molar and RCT treated left first permanent molar was noted. Moyers Mixed dentition analysis was done and a 5mm space deficiency was found in the lower left premolar region. Literature suggests that space regaining with a removable appliance is difficult, especially in mandibular arch [3], therefore, a fixed open coil space regainer (OCSR) suitable for this case was designed [Figure 1 (a)]. Parents were counseled likewise and consent was obtained

### Construction of the appliance

Band adaptation (0.180×0.005 inches) was done on lower left first permanent molar and 0.025-inch buccal and lingual tubes were welded on both sides of the band, parallel to each other. The tubes were blocked with wax, and alginate impressions of both arches were taken.

A stainless steel wire, 0.7 mm thick, was bent into a 'U' shape and inserted into the tubes, with the horizontal part of the 'U' pressing against the distal surface of the canine at the contact area. Soldering was performed at the junction of the horizontal and vertical parts (at contact point of canine) of the 'U' shaped wire to restrict the forward movement of the open coil spring [Figure 2(a)].

Open coil springs were then inserted onto the wire on each side, with each spring having a length twice that of the

distance between the solder stops and the anterior border of the tubes. The appliance was cemented onto the first permanent molar by compressing the springs with the 'U' shaped wire, causing the springs to create a reciprocal force anteriorly towards the primary canine and posteriorly towards the first permanent molar [Figure 2 (b)]. The patient was followed up every 21 days, and the open coil spring was changed five times during the treatment duration. The desired space for the eruption of the first premolar was achieved within four and a half months after the appliance was inserted (Figure 3(a)).

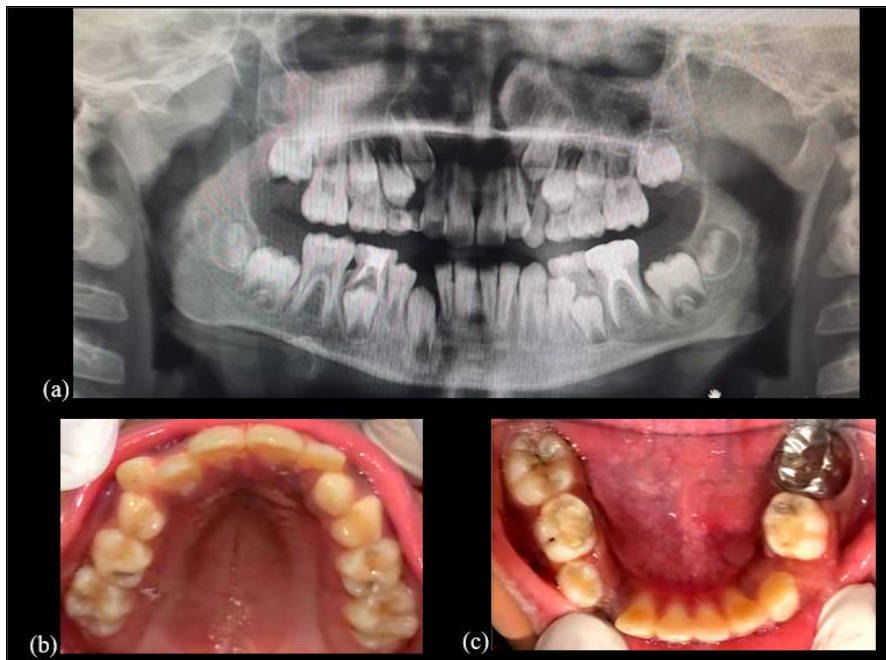
At the 6-month follow-up [Figure 3], the partially erupted first premolar and mobile second primary molar (due to physiological root resorption) were noted, leading to the planned extraction of the second primary molar and removal of OCSR. At the 12-month [Figure 4] follow-up, the completely erupted first and second premolars were observed.

### Discussion

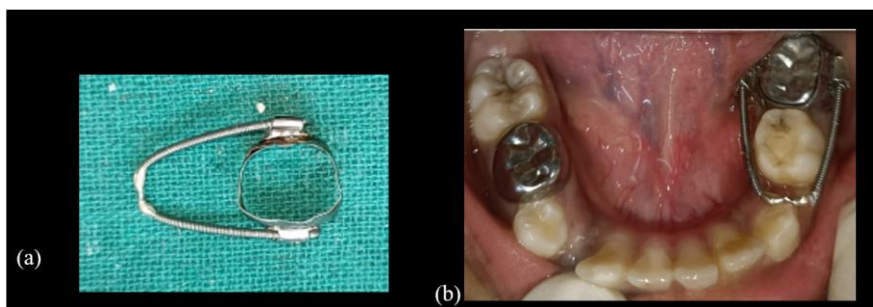The primary dentition is crucial for appearance, speech, chewing, and guiding the eruption of permanent teeth [6]. Premature loss of primary teeth is most commonly caused by dental caries, trauma, and early root resorption. This premature loss can reduce the arch length necessary for the succeeding teeth, leading to crowding, rotation, drifting of adjacent teeth, and impaction of permanent teeth [7]. Pediatric dentists can benefit children by early diagnosis and treatment of conditions that lead to malocclusion.

Various techniques, such as serial extractions and space regaining, are employed to reduce or intercept malocclusion [8]. In this case, since the permanent molars and premolars had erupted in the mandibular arch, space regaining was planned. Space regainers are categorized into removable and fixed types. Removable regainers have disadvantages like easy removal by the patient, and they can be easily broken or lost. Therefore, a fixed regainer, specifically an open coil spring space regainer (OCSR), was chosen.

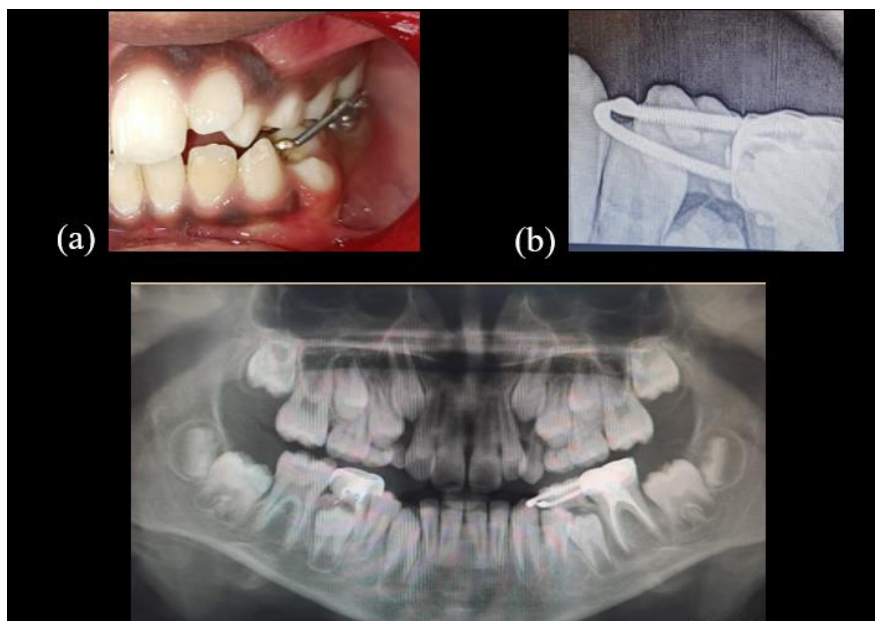
The OCSR consists of open coils known for their long-range superelastic activity and excellent springback. Another advantage is that the operator can control the force due to minimal load fluctuation despite significant deflection [9]. The mean rate of space closure is 0.81 mm per month for NiTi springs [8]. In this case, 5mm of space was regained within four and a half months. This short treatment period could be attributed to the minor amount of space mesial to the canine, utilized for space closure, and the distalization of the first permanent molar. According to Gianelly *et al.*, molar distalization does not occur after the eruption of the second molar [10]. However, Flores-Mir C *et al.* stated that the eruption stage of maxillary second and third molars has minimal impact on molar distalization, both linear and angular, which was consistent with the present case report [11]. Although the fixed appliance was more comfortable for the patient, it has the potential disadvantage of affecting gingival health and causing dental caries, although no such issues were observed in this case [12].



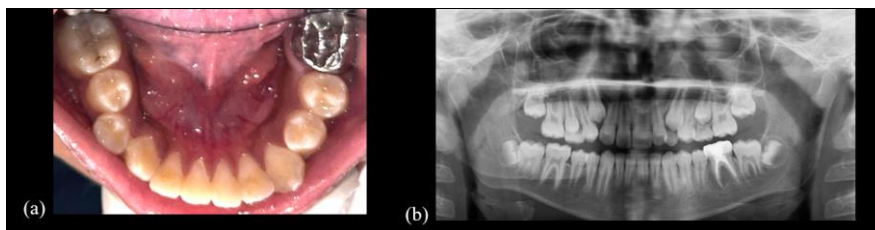
**Fig 1:** (a) Pre- operative OPG (b-c) intra-oral photographs of maxillary and mandibular arch



**Fig 2:** 2(a) Open coil space Regainer (OCSR) (b) Immediate post-operative intra- oral photograph



**Fig 3:** Follow-up at 6 months (a) erupting left first premolar (b) IOPAR depicting physiological root resorption wrt left primary second molar (c) OPG



**Fig 4:** At 12 month follow-up (a) complete eruption of premolars bilaterally (b) OPG

### Conclusion

The timely intervention and application of an open coil spring space regainer (OCSR) in this case highlights the effectiveness of interceptive orthodontics in managing space deficiencies during the mixed dentition period. By utilizing a fixed appliance, space for the eruption of the first premolar was successfully regained within a relatively short treatment period. This case underscores the importance of early diagnosis and treatment in preventing malocclusion, as well as the practical benefits of fixed space retainers over removable ones, particularly in terms of patient compliance and treatment efficacy. The successful outcome in this case, with no observed adverse effects on gingival health or dental caries, demonstrates the utility of OCSR as a reliable and economical option for space regaining in pediatric dentistry.

### References

1. Kumari BP, Kumari NR. Loss of space and changes in the dental arch after premature loss of the lower primary molar: a longitudinal study. *J Indian Soc Pedod Prev Dent.* 2006;24:90-96.
2. Seward FS. Natural closure of deciduous molar extraction spaces. *Med Res Counc Aust.* 1965;85-94.
3. Proffit WR. *Contemporary orthodontics.* 2nd ed. St. Louis: Mosby Year Book; c1993. p. 380-383.
4. Costa GCD, Chalakkal P, Aras MA, Chitre V. Use of open coil space regainer for tooth movement prior to prosthetic treatment. *J Clin Diagn Res.* c2015, 9(6).
5. Von Fraunhofer JA, Bonds PW, Johnson BE. Force generation by orthodontic coil springs. *Angle Orthod.* 1993;63(2):145-8.
6. Barberia E, Lucavechi T. Free-end space maintainers: design, utilization, and advantages. *J Clin Pediatr Dent.* 2006 Fall;31(1):5-8.
7. Bhalajhi SI. Interceptive orthodontics. In: *Orthodontics: the art and science.* 3rd ed. New Delhi: Arya Medi Publishing House; c2006. p. 234.
8. Negi KS. NiTi bonded space regainer/maintainer. *J Indian Soc Pedod Prev Dent.* 2010;28:113-115.
9. Miura F, Mogi M, Ohura Y, Karibe M. The super-elastic Japanese NiTi alloy wire for use in orthodontics. Part III: studies on the Japanese NiTi alloy coil springs. *Am J Orthod Dentofacial Orthop.* 1988;94:89-96.
10. Chalakka P, Thomas AM, Akkara F, Pavaskar R. New design space retainers: 'Lingual arch crossbow' and 'Double banded space regainer'. *J Indian Soc Pedod Prev Dent.* 2012;30(2):161-5.
11. Gianelly AA. Distal movement of the maxillary molars. *Am J Orthod Dentofacial Orthop.* 1998;114:66-72.
12. Flores C, Grath L, Heo G, Major P. Efficiency of molar distalization associated with second and third molar eruption stage: a systematic review. *Angle Orthod.* 2013;33(4):735-42.

### How to Cite This Article

Saxena B, Goswami M, Saxena A, VasuPadha S. Management of space loss in mixed dentition using open coil space Regainer: A case report. *International Journal of Applied Dental Sciences.* 2024; 10(3): 93-96.

### Creative Commons (CC) License

This is an open access journal, and articles are distributed under the terms of the Creative Commons Attribution-NonCommercial-ShareAlike 4.0 International (CC BY-NC-SA 4.0) License, which allows others to remix, tweak, and build upon the work non-commercially, as long as appropriate credit is given and the new creations are licensed under the identical terms.