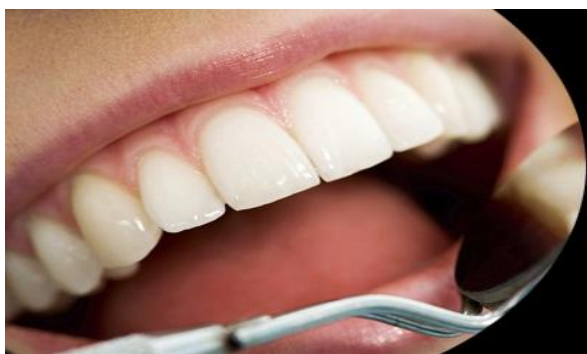



ISSN Print: 2394-7489
ISSN Online: 2394-7497
IJADS 2014; 1(1): 11-14
© 2014 IJADS
www.oraljournal.com
Received: 05-09-2014
Accepted: 27-12-2014

Panna Mangat
MDS, Reader, Department Of
Conservative Dentistry and
Endodontics. D. J College Of
Dental Science and Research
Centre, India

Dr. Annil Dhingra
M.D.S., F.A.G.E., F.I.C.D.
Professor and Head,
Department of Conservative
Dentistry & Endodontics D.J.
College of Dental Sciences and
Research, Modinagar, Ghaziabad,
India

Sagarika Muni
Post Graduate Student.
Department of Conservative
Dentistry and Endodontics. D.J
College of Dental Science and
Research Centre, India

Correspondence
Sagarika Muni
Post Graduate Student.
Department Of Conservative
Dentistry and Endodontics. D.J
College of Dental Science and
Research Centre, India

Three dimensional helical computed tomographic evaluation of two obturation techniques: An *in vitro* study

Panna Mangat, Annil Dhingra, Sagarika Muni

Abstract

Three Dimensional Helical Computed Tomographic Evaluation of Two Obturation Techniques: An *In vitro* Study.

Aim: The aim of this study was to evaluate the adequacy of two obturation techniques, namely Calamus and Thermafil via volume rendering method utilizing a three dimensional helical computed tomography.

Materials and Method: Sixty freshly extracted single rooted teeth (maxillary first premolar) were collected and randomly allocated into two groups. Biomechanical preparation was done in all the teeth using rotary instruments. The teeth were placed in helical CT scanner and imaged before obturation. The teeth were then obturated utilizing following methods: Group 1- Calamus and group 2 - Thermafill. Evaluation of the volume of the pulp chamber and Gutta-percha after obturation was done via volume rendering technique, which reflects the adequacy of obturating system.

Results: There is a statistical difference between the Thermafill and Calamus with regards to the adequacy of obturation. The three dimensional obturating material Calamus have less volume inadequacy as compared to Thermafill.

Conclusion: The adequacy of obturation was better with Calamus as compared to Thermafill. But the research with regards to Calamus and Thermafill still continues in endodontics as three dimensional obturating material.

Keywords: Helical computed tomography, three dimensional obturation, Thermafill, Thermoplasticized GP, Warm vertical compaction.

1. Introduction

Stephen Cohen stated that the complete obturation of root canal system to the cement-dentinal junction is an important goal in endodontic treatment. To achieve this goal, the root canal filling must seal the pulp space both apically and laterally to prevent further apical irritation from incomplete elimination of bacterial products [1].

In the past the adequacy of the root canal filling procedure was primarily based on its vertical appearance on the dental radiograph and whether the material had reached the radiographic apex or not. But now what is required is a deeper appreciation of the importance of filling canals laterally as well as vertically [1].

Herbert Schilder describes the final objective of endodontic procedure as being the "total obturation of root canal space" or filling the radicular space three dimensionally. Rich Mounce in 2004 defined three dimensional obturation, as placing a homogeneous and dense filling material, from the canal orifice to the minor constriction of the apical foramina, as well as into all anatomical ramifications. Clifford Ruddle described three dimensional obturation is done in a space that differs from root to root and teeth to teeth, thus it becomes a challenge to cleaning and shaping [7].

Shaping of the canal always facilitates the 3D obturation by allowing prefit pluggers to work deep and move the thermo softened gutta percha into all aspects of the root canal. Gutta percha is the most important root canal filling material accepted in dentistry today because it is least irritating and least toxic. A variety of thermoplasticized gutta percha techniques are available for the three dimensional obturation [7].

Since not much research is available on the volume adequacy and three dimensional obturation

of the material; thus the aim of our study was to evaluate the volume adequacy of three dimensional obturating techniques namely Thermanfill and Calamus utilizing Helical Computed Tomography.

2. Materials and Methods

Sixty freshly extracted single rooted teeth (maxillary first premolar) were selected for this study (figure1), and were stored in normal saline. Access cavity was prepared in all teeth using no. 4 round bur, followed by coronal enlargement using Gates Glidden drills.

Glide path was created using path files (figure 2). Working length was determined and canal preparation was done in all teeth using rotary protaper up to F2 (figure 3). Any calcific obstruction, if present was negotiated with EDTA. Copious irrigation was done with 5% sodium hypochlorite and normal saline. The canals were dried with sterile paper points.

Helical or spiral CT scanner was used for the details of the canals after cleaning and shaping and before obturation. The teeth were divided into two groups viz; Group 1- Calamus (that is based on the warm vertical compaction) and Group 2 - Thermanfill (involves the core carrier technique) (figure 4 and 5). AH Plus was used as a sealer in both the groups. After obturation, the volumetric analysis of the obturated space was done using the DICOM software utilized in the helical CT scanner [2].

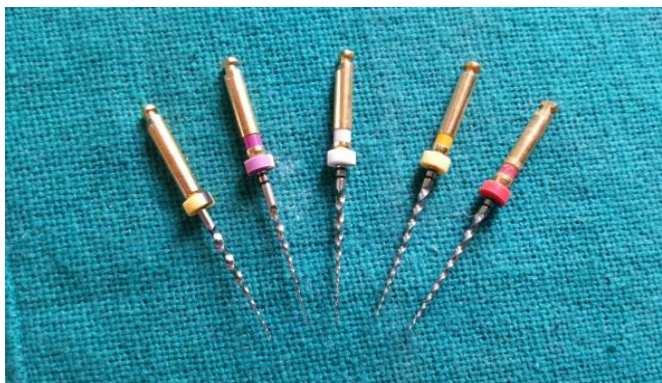

Fig 3: Rotary protapers (Dentsply Mailleffer) used for the biomechanical preparation..



Fig 4: Calamus used in this study for three dimensional obturation

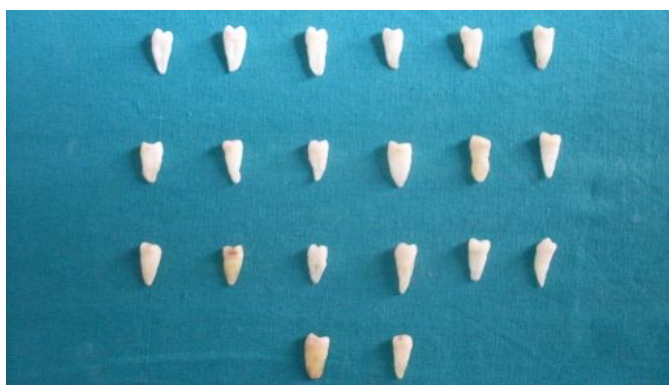

Fig 1: This figure represents specimens used in this study.



Fig 5: Thermanfill used in this study for three dimensional obturation.

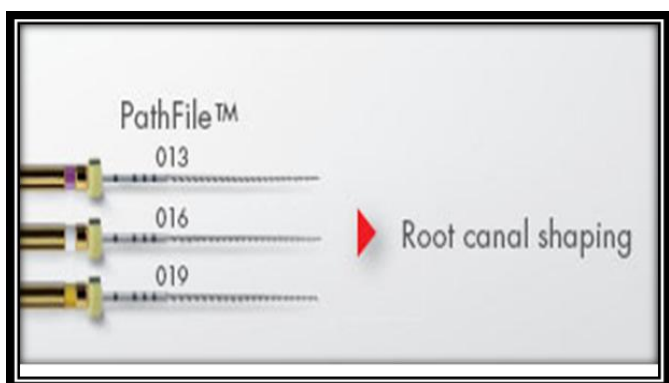


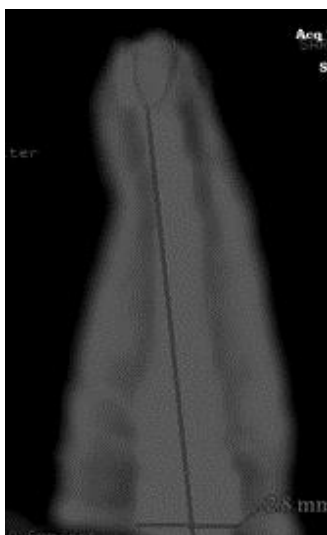
Fig 2: Path files (Dentsply Mailleffer) used in this study for creating glidepath.

Images on helical CT scanner

Group 1

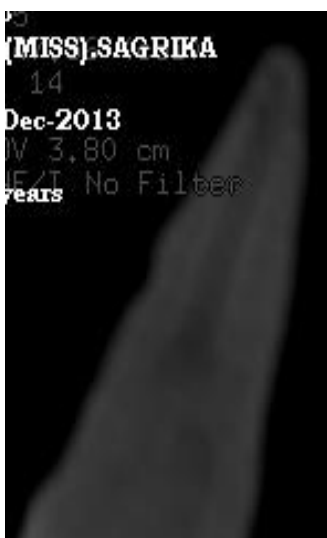

(before obturation)

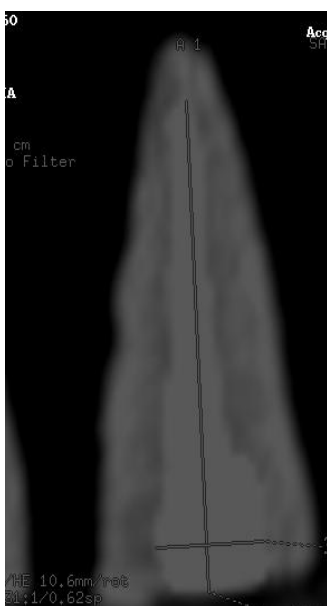


(After obturation)

Group 2



(Before obturation)



(After obturation)

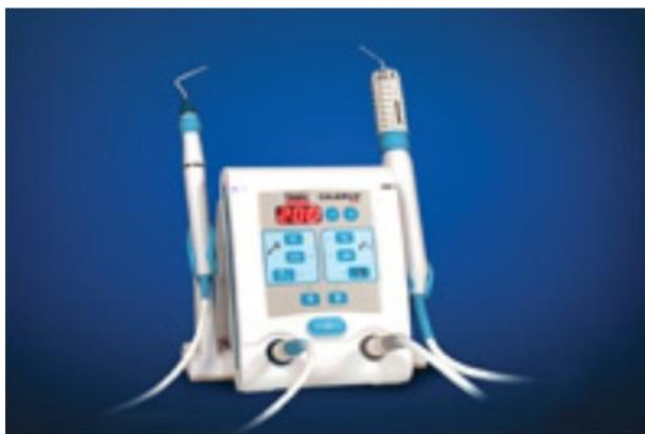

Fig 6: Calamus unit

3. Results

The mean and the standard deviation of the two obturating materials were calculated before and after obturation and their volume inadequacy was determined (table 1). The volume inadequacy in group 1 - Calamus was 2.33 but in case of Thermafill it was 7.13 (volumes were measured in cubic mm).

Wilcoxon Signed Rank test was used to evaluate the p value. The p value was found to be 0.005, which states that the difference between the volume in adequacy between the two group was significant.

The test of significance is shown using the p-value in (table 2).

Table 1: Mean and standard deviation were calculated before and after obturation, and their volume inadequacy was determined.

	Before obturation	After obturation	Volume inadequacy
Group 1	20.702. SD= 4.417	113.917 SD=2.220	93.215 (2.334)
Group 2	28.806 SD=1.311	167.2 SD=6.67	138.314 (7.138)

Table 2: Test of significance.

Groups	P value	Test of significance
Gr 1 Vs Gr 2	0.005	Significance

4. Discussion

Gutta-percha is by far the most universally used solid core root canal filling material used in root canal treatment. It exists in two phases, alpha and beta phase. When heated, it exists in alpha phase, which is tacky, sticky and non-compatible. But when cooled down to the beta phase shrinkage occurs, and the degree of shrinkage is always greater than the degree of expansion [2].

The purpose of obturating the prepared root canal space is to eliminate all avenues of leakage from the oral cavity or the periradicular tissue into the root canal system and to seal within the system any irritants that cannot be fully removed during canal cleaning and shaping procedures.

When the two dimensional radiographic appearance of root canals is unacceptable and leakage is high, then the importance of 3D obturation comes to play. The 3D obturation leaves no space for the lateral canals to hide [4].

In our study, Thermafill and Calamus were used as obturating materials and the volume inadequacy was compared. This was done to ensure which material has the maximum voids after obturation and better ability to seal canal, both being three dimensional obturating materials.

Spiral CT has been well documented as an aid in determining the volume of the root canal, and the gutta percha that has been obturated for a hermetic seal. Willi Kalender, was the first person, credited for the invention of Spiral / Helical CT scan. Helical CT scan is a three dimensional computed tomographic image in which the source of X-ray, is a helical trajectory relative to the object.

Vannier *et al* demonstrated the feasibility of spiral volumetric CT for quantitative study of oral hard tissues in the presence of metal restorations. Blake Nielson R *et al* evaluated the value of microcomputed tomography in morphological relationships in endodontic research and concluded that helical computed tomography is an important diagnostic tool used for various dental hard and soft tissues. Kleoniki Ly Roundi *et al* studied the application of both digital 3D image processing and virtual reality techniques in endodontics, and he concluded that the Helical CT is an important tool for depicting the 3 D volume of the obturated canals.

Thus the volume-rendering technique used with the help of 3D helical CT is the most accurate mode of depiction of 3D volume of the obturated canals. It allows the clinician to visualize the filling from all angles unlike radiographs which give two-dimensional reproductions. The voids at various axial levels can be calculated [2].

Results of our study indicated that Thermafill showed more deviation from root canal volume as compared to Calamus. 3D obturation was better with calamus as compared to thermafil. This can be explained by the fact that calamus first creates an apical plug then a back fill obturation is done, thus it provides a better 3D obturation while Thermafill flows through all of the canals, so it may also flow through the apex [5].

The backfill obturation technique is very technique sensitive. Proper condensation of the gutta percha should be done in order to avoid voids during obturation.

A study reported by Willhelm Pertot mentioned some other disadvantages with Thermafill like the carrier present may get stripped of from the gutta percha in curved canals and the inefficiency in obturating elliptical canals. He also reported that there can be pain upon insertion of the obturator and occlusion of the openings of other canals in multirooted teeth upon elimination of the carrier and excess of gutta percha [2].

Ken Serota stated the disadvantage of Thermafill obturation in an endodontic retreatment case. In this case report, in the apical area, it was difficult to remove the plastic carrier from the mesiobuccal canal 2. Thus, incomplete preparation of mesiobuccal canal 2, lead to failure of root canal therapy [6].

5. Conclusion

A statistical difference between the Thermafill and Calamus with regards to the adequacy of obturation was present. Within the limitation of this study, Thermafill showed more volume inadequacy than Calamus as there was more deviation from the root canal volume.

6. References

1. Stephen C. Burns R. Pathways of Pulp. Edn 6, United States: Mosby Publications, 2000, 225.
2. Chokkalingam M, Ramaprabha, Kandaswamy D. Three-dimensional helical computed tomographic evaluation of three obturation techniques: *In vitro* study. J Conserv Dent 2011; 14(3):273–276.
3. Gutmann JL, Kuttler S, Stephen P. Root canal obturation, an update. www.ineedce.com., 1-9.
4. Ruddle CJ. Filling Root Canal Systems: The Calamus 3-D Obturation Technique March 31.

5. Maalouf S, attieh-abikanaan, Ounsi HF. Thermafil: a conventional technique in endodontics. Dental news 1996; 3(3):27-31.
6. Serota K. blogohj.oralhealthjournal.com. clinical endodontics. Endodontic retreatment of failing thermafil obturation, 1-5.
7. Schilder H. Failing root canals in three dimensions. JOE-2006; 32(4):281-290.