ISSN Print: 2394-7489
ISSN Online: 2394-7497
IJADS 2015; 2(1): 15-19

www.oraljournal.com
Received: 24-02-2015
Accepted: 08-04-2015

Dr. Uday Kamath
Department of Conservative Dentistry and Endodontics, Dr. Syamala Reddy Dental College, Hospital and Research Center, 111/1, Munnekolala, Marathalli post. Bangalore, 560037, India.

Dr. Hina Sheth
Department of Conservative Dentistry and Endodontics, Dr. Syamala Reddy Dental College, Hospital and Research Center, 111/1, Munnekolala, Marathalli post. Bangalore 560037, India.

Dr. Neethu Mohan
Department of Conservative Dentistry and Endodontics, Dr. Syamala Reddy Dental College, Hospital and Research Center, 111/1, Munnekolala, Marathalli post, Bangalore 560037, India.

Dr. Deepthi Reddy
Department of Conservative Dentistry and Endodontics, Dr. Syamala Reddy Dental College, Hospital and Research Center, 111/1, Munnekolala, Marathalli post, Bangalore, 560037 India.

Correspondence
Dr. Uday Kamath
Department of Conservative Dentistry and Endodontics, Dr. Syamala Reddy Dental College, Hospital and Research Center, 111/1, Munnekolala, Marathalli post. Bangalore, 560037, India.

Endodontic management of radix entomolaris: Case reports

Uday Kamath, Hina Sheth, Neethu Mohan, Deepthi Reddy

Abstract
The root canal treatment of a mandibular molar with aberrant canal configuration can be diagnostically and technically challenging. This report discusses endodontic treatment of three mandibular molars with radix entomolaris (RE). The first case report discusses bilateral radix entomolaris in mandibular first molars. An additional aberrant root canal anatomy of the middle mesial canal, which was confirmed by cone beam computed tomography (CBCT) images, is also described. This case report highlights the usefulness of CBCT imaging for accurate diagnosis and management of the unusual canal morphology. The second case report discusses a mandibular first molar with three roots (one mesial and two distal) and four canals (two in mesial and one in each distobuccal and distolingual root). If present, an awareness of unusual root canal morphology can contribute to the successful outcome of root canal treatment.

Keywords: Anatomical variations, endodontic treatment, mandibular molar, radix entomolaris.

1. Introduction
The prevention or healing of endodontic pathology depends on a thorough chemomechanical cleansing and shaping of the root canals before a dense root canal filling with a hermetic seal. An awareness and understanding of the presence of unusual root canal morphology can thus contribute to the successful outcome of root canal treatment [1].
In a mandibular first molar an additional third root, first mentioned in the literature by Carabelli is called the radix entomolaris (RE). This supernumerary root is located distolingually in mandibular molars, mainly first molars. [2] The presence of a separate RE in the first mandibular molar is associated with certain ethnic groups. Mandibular first molar which has three roots has a frequency of less than 5% in white Caucasian (UK, Dutch, Finnish, German), African (Bantu Bushmen), Eurasian and Indian populations. [3] In those with Mongoloid traits, such as the Chinese, Eskimos, and native American populations, it occurs with a frequency of 5 to more than 30% [4, 5].
In endodontic diagnosis, conventional radiographic techniques, regardless of whether they are film based or digital have various limitations. These include the two-dimensional nature of the images produced, anatomical noise masking the area of interest to varying degrees and geometric distortion. Cone Beam Computed Tomography (CBCT) does appear to overcome some of these limitations, and does generate three-dimensional images. [6] In this report morphology, clinical approach to diagnosis and endodontic treatment of a case of bilateral radix entomolaris and a second case of radix entomolaris are presented.

2. Case Report: 1
A 25 year old male patient reported to the Department of Conservative Dentistry and Endodontics, Dr. Syamala Reddy Dental College, Bangalore with complaint of pain in the right & left lower back teeth. The patient reported a history of throbbing pain for the past one month, which increased in intensity on having food and was relieved on taking medication. On examination, the right & left mandibular first molar displayed deep dental carious lesion with no tenderness on percussion. Thermal and electrical pulp testing of the tooth elicited a negative response. The pre-treatment radiograph showed widening of the periodontal ligament space and an additional root between the mesial and distal roots [Fig.1]. CBCT was advised to confirm that the additional root was located distolingual to the mesial root.

The transverse, axial, and sagittal CBCT sections of the involved tooth were taken [Fig. 2, 3]. The CBCT scan slices confirmed the presence of bilateral radix entomolaris. A diagnosis of a right & left mandibular first molar with symptomatic irreversible pulpitis was made and endodontic treatment was planned. In the first visit left mandibular first molar was anesthetized using 2 ml of 2% lidocaine containing 1:200,000 epinephrine (LOX 2%, Neon Laboratories Ltd., Mumbai, India) and isolated under rubber dam. The pulp chamber was accessed and three mesial orifices and two distal orifices were located. To obtain a straight line access the preparation was modified to a more trapezoidal form [Fig. 4]. The root canals were explored with precurved K-file ISO number 15 (Dentsply Maillefer, Ballaigues, Switzerland). Working length was determined using apex locator (ProPex PiXi, Dentsply) and confirmed using radiographic method [Fig. 5]. The root canals were instrumented using the ProTaper rotary files (Dentsply Maillefer, Ballaigues, Switzerland) in all the canals. During instrumentation adequate irrigation was performed using 3% sodium hypochlorite (Deor, Azure laboratories, Kochi, India) and lubricated using Glyde (Dentsply Maillefer, Ballaigues, Switzerland). Final irrigation was done using 2% chlorhexidine (RC-Chlor, Deor, Azure laboratories, Kochi, India). Master cone radiograph was taken [Fig. 6]. Obturation was done using AH plus sealer (Dentsply, Maillefer, Ballaigues, Switzerland) and corresponding ProTaper gutta percha points. Access preparation was then restored with composite resin [Fig. 7].

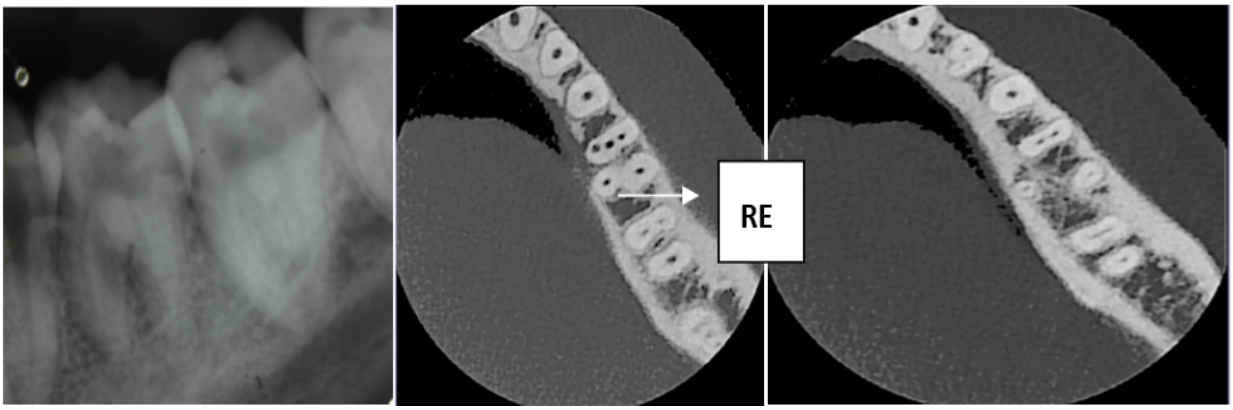

Fig 1, 2, 3: Preoperative radiograph, CBCT images showing two separate distal roots and middle mesial canal on 36

Fig 4: Access opening

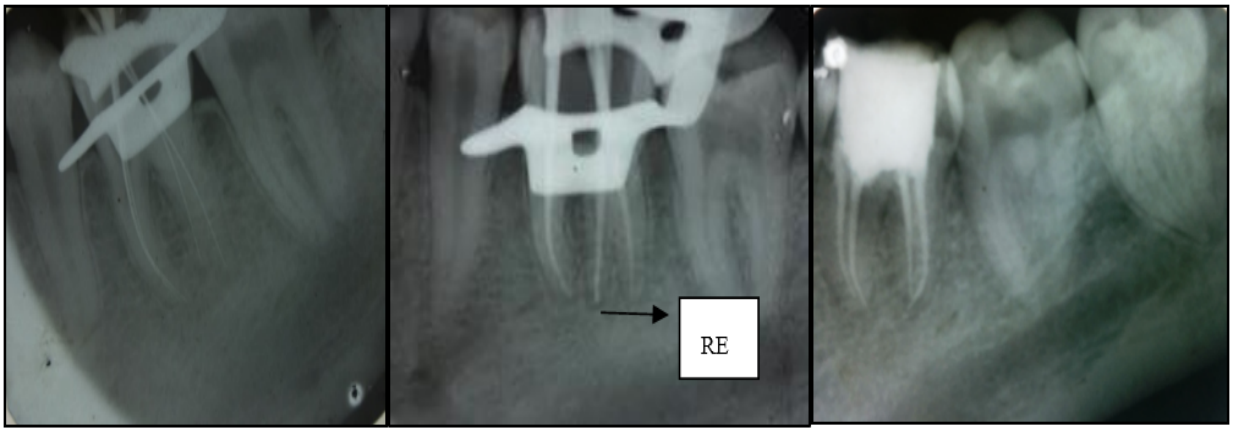

Fig 5, 6, 7: Working length, master cone and post obturation radiographs.

At the second visit the right mandibular first molar was anesthetized and isolated under rubber dam. Access cavity preparation was done using No 2 Endo Access bur (Dentsply Maillefer, Tulsa, Okla). The canal orifices were located using DG 16 explorer. Two mesial and two distal orifices were identified and root canal therapy was performed.

Fig 8 and 9: Preoperative radiograph and Access opening.

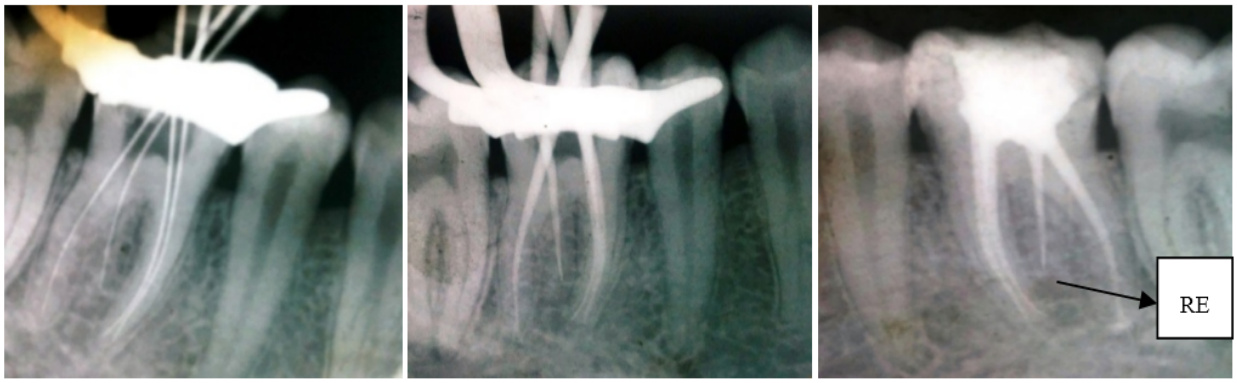

Fig 10, 11, 12: working length, master cone and obturation radiographs.

3. Case Report: 2

A 30-year-old female patient was referred to the Department of Conservative Dentistry and Endodontics, Dr. Syamala Reddy Dental College, Bangalore with the complaint of pain in the lower left back tooth region. The patient reported a history of intermittent pain for the past one month, which aggravated on chewing food. On clinical examination, there was a carious mandibular left first molar and was tender on percussion. The involved tooth showed a negative response to electric pulp test. Diagnostic radiography showed a coronal radiolucent area involving the pulp and ill-defined radiolucency at the periapex of distal root. Based on these findings, the tooth was diagnosed with symptomatic irreversible pulpitis and apical periodontitis. Endodontic management was planned for the involved tooth. In the first visit profound anesthesia was achieved using 2% lidocaine (LOX 2%, Neon Laboratories Ltd. Mumbai, India) for inferior alveolar nerve block. The tooth was isolated with a rubber dam and access cavity preparation was done using round burs and Endo-Z bur [Fig. 14]. A clinical examination was carried out with a DG16 endodontic explorer (Hu-Friedy, Chicago, IL, USA). The fourth disto-lingual canal orifice was present far from distal root canal orifices. Coronal enlargements of the canals were performed with the nickel-titanium ProTaper orifice shaper (Dentsply Maillefer, Ballaigues, Switzerland). ISO size 6, 8, and 10 files were used to create initial glide path. Working length was determined using an apex locator (ProPex PiXi, Dentsply). Working length radiograph using Buccal object rule (SLOB technique) confirmed the additional root as distolingual root (radix entomolaris) [Fig: 15]. Instrumentation was completed using ProTaper rotary files and 3% sodium hypochlorite irrigation (Deor, Azure laboratories, Kochi, India). Calcium hydroxide intra canal medicament was placed and access cavity restored with zinc oxide eugenol cement. The patient was recalled after one week. At this appointment the tooth was asymptomatic and master cone radiograph was taken [Fig.16]. The canals were dried using paper points obturated with ProTaper gutta percha and AH plus sealer (Dentsply, Maillefer, Ballaigues, Switzerland) [Fig.17].

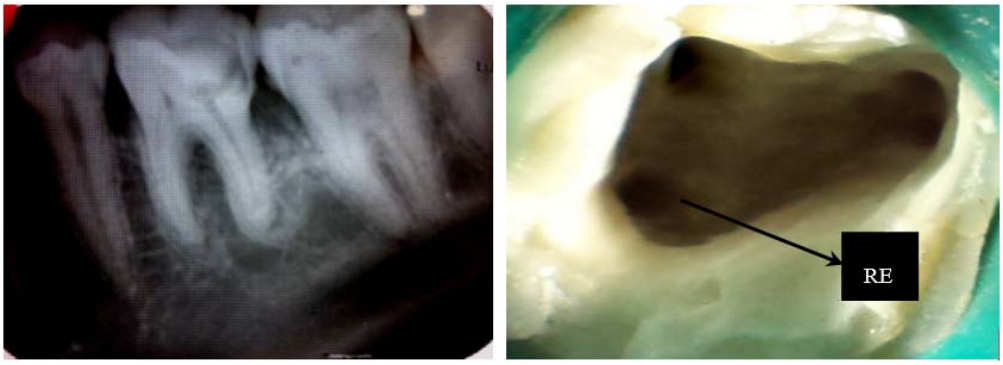

Fig 13, 14: Preoperative radiographs, Occlusal view of pulp chamber.

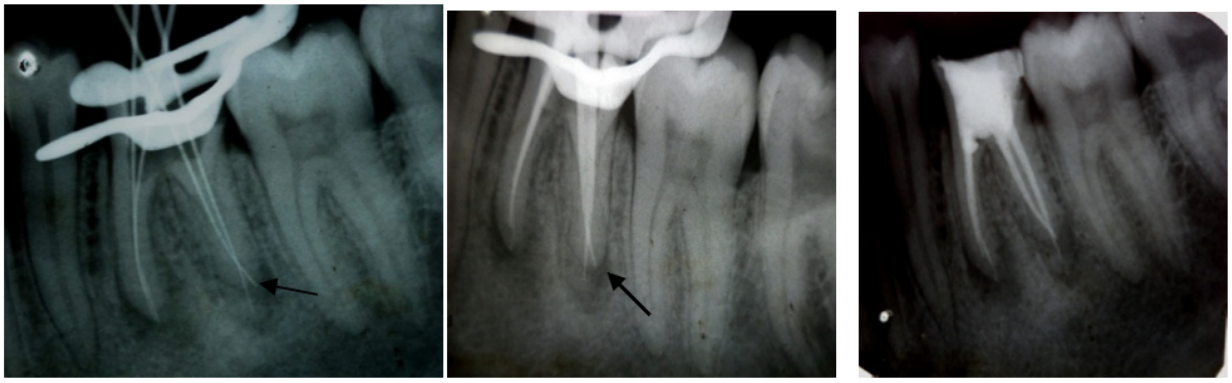

Fig 15, 16, 17: Working length, master cone and post obturation radiographs showing additional root.

4. Discussion

A thorough knowledge of root canal morphology and the configuration of the teeth play an important role in the success of endodontic therapy. Radix entomolaris and Radix paramolaris can be found on the first, second and third mandibular molar, occurring least frequently on the second molar. Bilateral occurrence of the RE ranges from 50 to 67%. [1] The etiology behind the formation of the RE is still unclear. Indysmorphic, supernumerary roots formation could be related to external factors during odontogenesis, or to penetrance of an atavistic gene or polygenetic system. In eumorphic roots, racial genetic factors influence the more profound expression of a particular gene that results in the more pronounced phenotypic manifestation. [7] RE can be classified into four different types depending on the location of its cervical part [8]

(i) Type A: the RE is located lingually to the distal root complex, which has two cone-shaped Macrostructure.

(ii) Type B: the RE is located lingually in the distal root complex, which has one cone-shaped Macrostructure.

(iii) Type C: the RE is located lingually to the mesial root

(iv) Type AC: the RE is located lingually between the mesial and distal root complexes.

Radiographically a third root should normally be readily evident in about 90% of cases. A careful inspection of the radiograph can sometimes reveal the presence of a “hidden” RE as indicated by an unclear view or outline of the distal root contour or the root canal. Traditional methods like Bubble test/champagne test, transillumination, White line test and Red line test can also be used. However, it may still be missed due to its slender dimensions occasionally [9]. Several reports have described the presence of aberrant canals in the mandibular first molar that includes the presence of three canals in the mesial root [10, 11, 12].

Cone-beam computed tomography has emerged as a useful tool to aid in the diagnosis of complex root canal anatomy. In the first case report the CBCT images revealed the location and direction of the curvature of radix entomolaris and also the presence of three mesial root canals. This was extremely beneficial during cleaning, shaping, and obturation of this root [13].

Based on the literature, the majority of radices entomolaris are curved. In some cases there is an additional curve starting from the middle of the root or in the apical third. Hence, using precurved files, adequate coronal enlargement avoids hindrances in the coronal segment of the canals and easy passage of the endodontic file to the apical segment. It would also allow root canal irrigants to pass on to the apical segment in larger volumes. [1] The root length in such cases can be confirmed with the help of electronic apex locators.

Vertucci and Williams first reported the presence of a middle mesial canal in a mandibular molar, there have been multiple case reports of aberrant canal morphology in the mesial root. In a clinical evaluation of 100 mandibular molars, Pomeranz et al found that 12 molars had middle mesial (MM) canals in their mesial roots and classified them into three morphologic categories as follows: fin, confluent, and independent. [14-20] Goel et al reported mandibular first molars had MM canals in 15.0% of specimens. Among these MM canals, only 6.7% of MM canals were independent. [21] CBCT in the present case guided the assessment of severity of the curvature of the root canals, the number of roots and root canals, and the confluent type of the middle mesial canal. Nonetheless, in spite of using the state-of-art gadgets endodontic mishaps may occur, and thus care has to be taken while negotiating and cleaning these curved canals.

5. Conclusion

Clinicians should be aware of these unusual root morphological variations of the radix entomolaris in terms of root inclination and root canal curvature. Preoperative radiological assessment from different angles, clinical evaluation of a root canal number and morphology using various diagnostic methodologies, a proper access preparation, and thorough examination of the pulp chamber to locate and debride all the canals are important. Knowledge of the location of the additional root and its root canal orifice will result in a modified opening cavity with extension to the distolingual. The initial diagnosis of radix entomolaris is important to facilitate the procedures during treatment and avoid the mislocation of any canal. Root inclination and root canal curvature demand careful, adapted clinical approach to avoid procedural errors during endodontic therapy.

6. References

1. Calberson FL, De Moor RJ, Deroose CA. The Radix Entomolaris and Paramolaris: Clinical Approach in Endodontics. J Endod 2007; 33(1):58-63.
2. Davini F, Cunha RS, Fontana CE, Silveira CF, Bueno CE. Radix entomolaris – A case report. RSBO 2012; 9(3):340-344.
3. Tratman EK. Three-rooted lower molars in man and their racial distribution, Br Dent J 1938; 64:264–274.
4. Curzon ME, Curzon JA. Three-rooted mandibular molars in the Keewatin Eskimo. J Can Dent Assoc 1971; 37(2):71–72.
5. Yew SC, Chan K. A retrospective study of endodontically treated mandibular first molars in a Chinese population. J Endod 1993; 19(9):471–473.
6. Patel S, Durack C, Abella F, Roig M, Shemesh H, Lambrechts P. European Society of Endodontology

position statement: The use of CBCT in Endodontics. Int Endod J 2014; 47:502–504.
7. Reichart PA, Metah D. Three-rooted permanent mandibular first molars in the Thai. Community Dent Oral Epidemiol 1981; 9:191–192.
8. Carlsen O, Alexandersen V. Radix entomolaris: identification and morphology. Scand J Dent Res 1990; 98(5):363–373.
9. Walker RT, Quackenbush LE. Three-rooted lower first permanent molars in Hong Kong Chinese. Br Dent J 1985; 159(9):298–299.
10. Baugh D, Wallace J. Middle mesial canal of the mandibular first molar: A case report and literature review. J Endod 2004; 30:185–186.
11. Holtzmann L. Root canal treatment of a mandibular first molar with three mesial root canals. Int Endod J 1997; 30:422–423.
12. Navarro LF, Luzi A, Garcia AA, Garcia AH. Third canal in the mesial root of permanent mandibular first molars: Review of literature and presentation of 3 clinical reports and 2 in vitro studies. Med Oral Patol Oral Cir Bucal 2007; 12:605–609.
13. Krasner P, Rankow HJ. Anatomy of the pulp-chamber floor. J Endod 2004; 30(1):5–16.
14. Vertucci FJ, Williams RG. Root canal anatomy of the mandibular first molar. JNJ Dent Assoc 1974; 48:27–28.
15. Weine FS. Case report: three canals in the mesial root of a mandibular first molar (?). J Endod 1981; 8:517–520.
16. Bond JL, Hartwell GR, Donnelly JC *et al.* Clinical management of middle mesial root canals in mandibular molars. J Endod 1988; 14:312–314.
17. Fabra-Campos H. Unusual root anatomy of mandibular first molars. J Endod 1985; 11:568–572.
18. Pomeranz HH, Eidelman DL, Goldberg MG. Treatment considerations of the middle mesial canal of mandibular first and second molars. J Endod 1981; 7:565–568.
19. Min KS. Clinical management of a mandibular first molar with multiple mesial canals: a case report. J Contemp Dent Pract 2004; 3:142–149.
20. Ricucci D. Three independent canals in the mesial root of a mandibular first molar. Endod Dent Traumatol 1997; 13:47–49.
21. Goel NK, Gill KS, Taneja JR. Study of root canals configuration in mandibular first permanent molar. J Indian Soc Pedod Prev Dent 1991; 8:12–14.