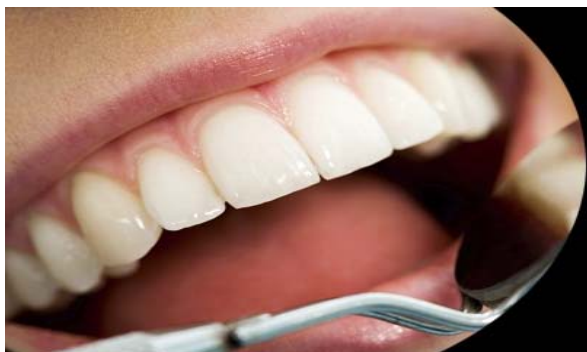



ISSN Print: 2394-7489  
ISSN Online: 2394-7497  
IJADS 2016; 2(1): 10-13  
© 2016 IJADS  
www.oraljournal.com  
Received: 11-12-2015  
Accepted: 12-01-2016

**M Jyothi**

Professor and Head of the  
Department, Department of  
Conservative Dentistry and  
Endodontics.

**B SL Jyothirmayi**

Post Graduate Student,  
Department of Conservative  
Dentistry and Endodontics.

**K Sirisha**

Professor, Department of  
Conservative Dentistry and  
Endodontics.

**A Mounika**

Professor, Department of  
Conservative Dentistry and  
Endodontics.

**K Girish**

Post Graduate Student,  
Department of Conservative  
Dentistry and Endodontics.

**MH Sruthi Keerthi**

Post Graduate Student,  
Department of Conservative  
Dentistry and Endodontics.

## Reattachment- Conservative management of complicated crown fractures in anterior teeth

**M Jyothi, B SL Jyothirmayi, K Sirisha, A Mounika, K Girish, MH Sruthi Keerthi**

### Abstract

Traumatic injuries to the anterior teeth are a most common form of dental trauma that mainly affects children and adolescents. One of the options for managing tooth fracture when the tooth fragment is available and there is no or minimal violation of the biological width is the reattachment of the dental fragment. Reattachment of fractured tooth fragments can provide good and long-lasting esthetics. It also restores function, provides a positive psychological response, and is a relatively simple procedure. This article reports on two crown root fractures and one coronal tooth fracture cases that were successfully treated using tooth fragment reattachment technique.

**Keywords:** Complicated crown root fracture; pre-fabricated fiber post; reattachment; trauma

### Introduction

Trauma to the anterior teeth is relatively a common occurrence. It is more common in males and literature has informed a particularly high prevalence of dental injuries in children between 7 to 12 years of age. Crown fractures account for the majority of dental trauma in the permanent dentition (26-76% of dental injuries), while crown-root fractures represent only 0.3-5%<sup>[1]</sup>. The anterior teeth are most often affected (80% central incisors and 16% lateral incisors) because of the anterior position of the maxilla and teeth protrusion. Among these, 80% of traumatized incisors have fracture line proceeding in an oblique direction from labial to lingual aspect<sup>[2]</sup>.

Coronal fractures of permanent incisors represent 28-44% being simple (involving enamel and dentin) and 11-15% complex (involving enamel, dentin and pulp)<sup>[3]</sup>. Trauma to the anterior teeth resulting in fracture fragment requires immediate attention not only because of the damage caused to the dentition but also due to the psychological impact it has on the patient. The treatment involves simple to complex restorative intervention depending on the severity of the fracture and its extent.

Primary goal of the treatment of traumatically injured teeth remains esthetic and functional rehabilitation. Several therapeutic procedures are available to restore fractured anterior teeth. Reattachment of the fractured fragment is an excellent biological approach for restoration, when the fragment is available. Tennery was the first to report the reattachment of a fractured fragment using the acid-etch technique. Tooth fragment reattachment offers a conservative, esthetic, and cost effective restorative option that has been shown to be an acceptable alternative to the restoration of the fractured tooth with resin-based composite or full-coverage crown.

This article reports three cases of reattachment, two performed without flap and one performed after raising an envelope flap.

### Case 1

A 27-year-old male patient reported with a broken maxillary anterior tooth (Figure 1A) with a history of trauma previous day. The fractured tooth fragment was recovered by the patient and was stored in water. His medical history was noncontributory. On clinical and radiographic examination, it was diagnosed as a chisel type of complicated crown root fracture of the maxillary right central incisor (Figure 1B) without any soft tissue injury. The fracture line was present subgingivally on the labial aspect and at the gingival margin on the palatal aspect.

### Correspondence

**B SL Jyothirmayi**

Department of Conservative  
Dentistry and Endodontics,  
GITAM Dental College and  
Hospital, Rushikonda,  
Visakhapatnam – 530045,  
Andhra Pradesh, India.

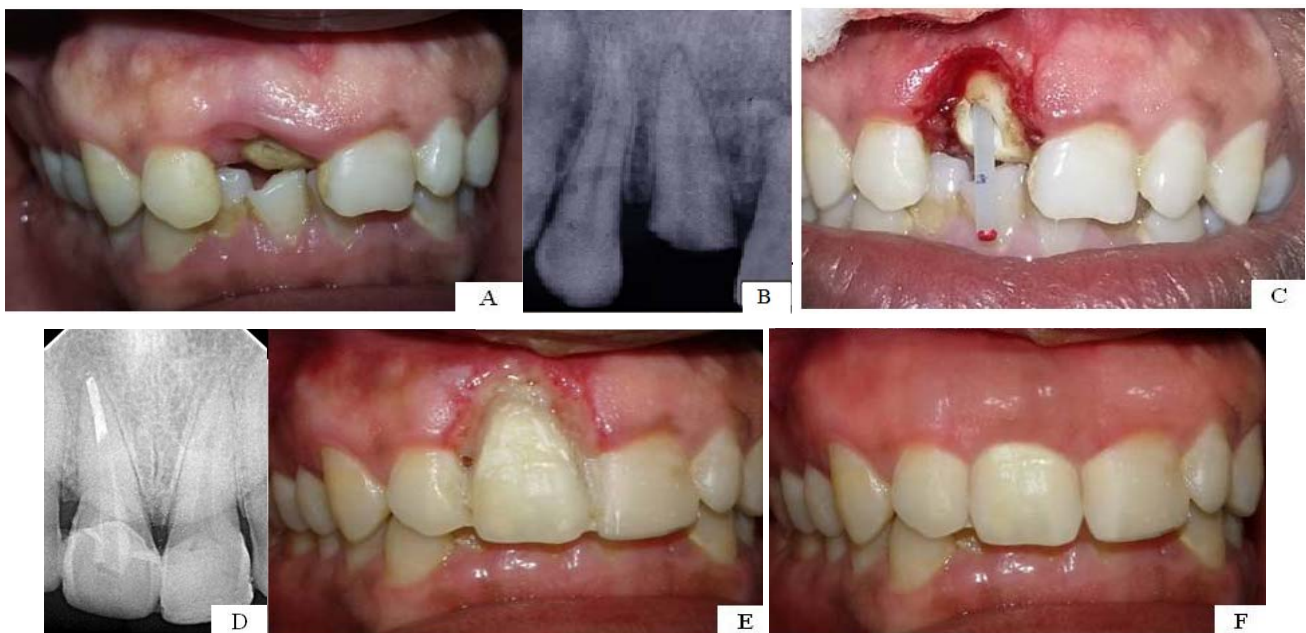
The biological width was determined by measuring probing depth (3 mm buccally) and conducting intrasulcular bone sounding after administering local anesthetic. The fit of the fragment was checked by keeping the fragment in its original position and it was found that there was an excellent fit without any occlusal interference. So, the reattachment procedure was planned and the treatment plan was explained to the patient.

After gaining profound anaesthesia, crown lengthening procedure (Figure 1C) was done using No. 12 surgical blade to excise 3 mm of the buccal gingiva and 1 mm of palatal gingiva, thus exposing the fractured margins of the tooth, while maintaining the biological width. Single visit root canal treatment was carried out for tooth #11 using sectional obturation. The post space was prepared by using peeso reamers retaining 5 mm of apical gutta percha and No.2 pre-fabricated glass fiber post (Hi-Rem Prosthetic post, over fibers) was selected. After checking the fit of the post, it was trimmed leaving about 3 mm of the post beyond the tooth. The pulpal aspect of the fractured fragment was prepared using a straight fissure bur (internal groove) and hence it would fit over the 3 mm of the post. The post and the fragment were adjusted until the fragment was approximated to its original position to obtain a lock and key type of fit in order to provide additional retention for the fragment.

Relyx™ Unicem self-adhesive universal resin cement (3M ESPE, St.Paul, MN, USA) was used to lute the post to the root canal dentin and light cured for 10 seconds.

After placing a bevel on the palatal aspect of the tooth, both the fragment and tooth were etched with 37% phosphoric acid etchant gel (Scotchbond™ Universal Etchant-3M ESPE, St.Paul, MN, USA) for 15 seconds. Then the bonding agent – Adper Single bond 2 (3M ESPE, St.Paul, MN, USA) was applied and light cured for 10 seconds. Flowable composite resin (Filtek Z 350XT flowable restorative-3M ESPE, St.Paul, MN, USA) was applied to both fragment and tooth surfaces. The fractured segment was then accurately placed on the tooth, paying special attention to the fit between the segments. When the original position had been reestablished, excess resin was removed and the bonded area was light cured for 40 seconds on each surface.

The occlusion was carefully checked and adjusted. The margins were properly finished with diamond finishing burs and polished with a series of Sof-Lex disks (3M ESPE, St.Paul, MN, USA) and polishing paste. Final radiograph was taken to confirm the proper alignment of the attached fragment (Figure 1D). The patient was given oral hygiene instructions and was recalled for follow-up visits. The two year follow up (Figure 1F) shows satisfactory result esthetically and functionally.



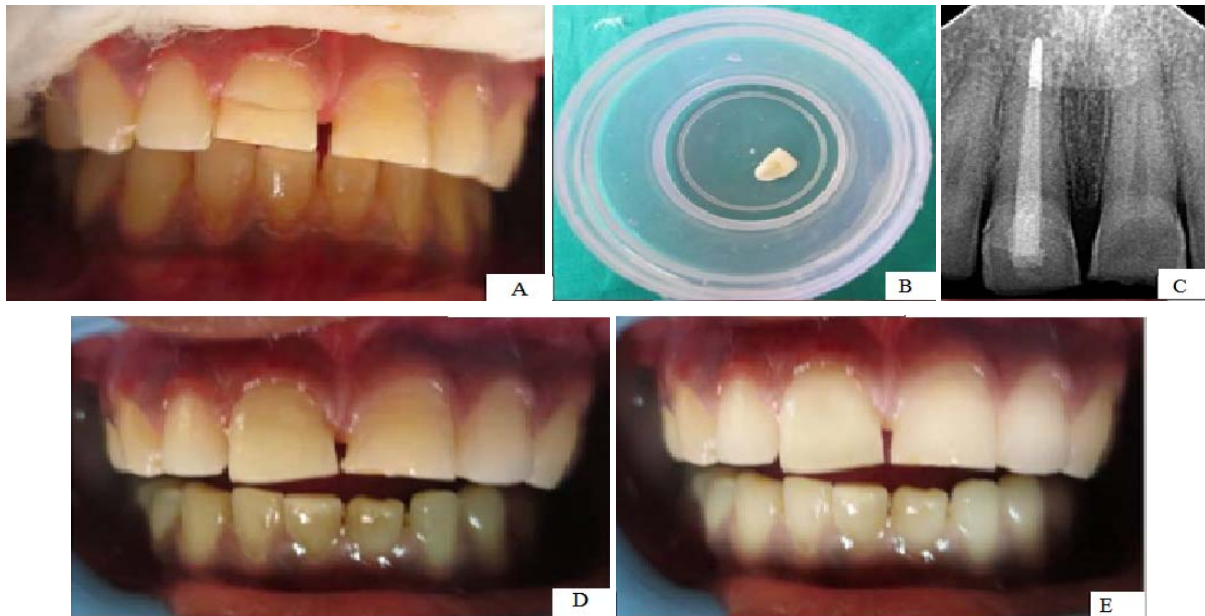
**Fig 1:** (A) Pre-operative view; (B) Pre-operative Intraoral peri-apical radiograph; (C) Tooth with gingivectomy and in place of fiber post; (D) Intraoral periapical radiograph showing reattached fragment; (E) Post-operative view; (F) 2 year follow up

## Case 2

A 24-year-old male patient reported to the Department of Conservative Dentistry & Endodontics with a chief complaint of mobile tooth in the maxillary anterior region. Patient gave the history of injury two days back. Clinical examination revealed Elli's class III fracture with tooth #11 and the fracture line was extending subgingivally palatally (Figure 2A). As the fragment was mobile, it was removed and stored in saline (Figure 2B). Radiographic examination revealed no other fractures in the root and healthy periapical tissues. The treatment plan decided for the patient was reattachment of the fragment following root canal therapy.

Gingivectomy was performed on the palatal side to expose the tooth margin. Single visit root canal treatment was done and prefabricated glass fibre post (Reforpost, Angelus) was placed and then cured.

Enamel bevelling was done on the buccal surface of the tooth as well as the fragment. Reattachment procedure was done for the fractured tooth with internal grooves on the fractured fragment and attached to the tooth with flowable composite. On the bevelled enamel surfaces, over contouring with composite was done. Occlusion was checked and the patient was recalled after 6 months and 1 year follow up (Figure 2E) that showed asymptomatic tooth with satisfactory esthetics.

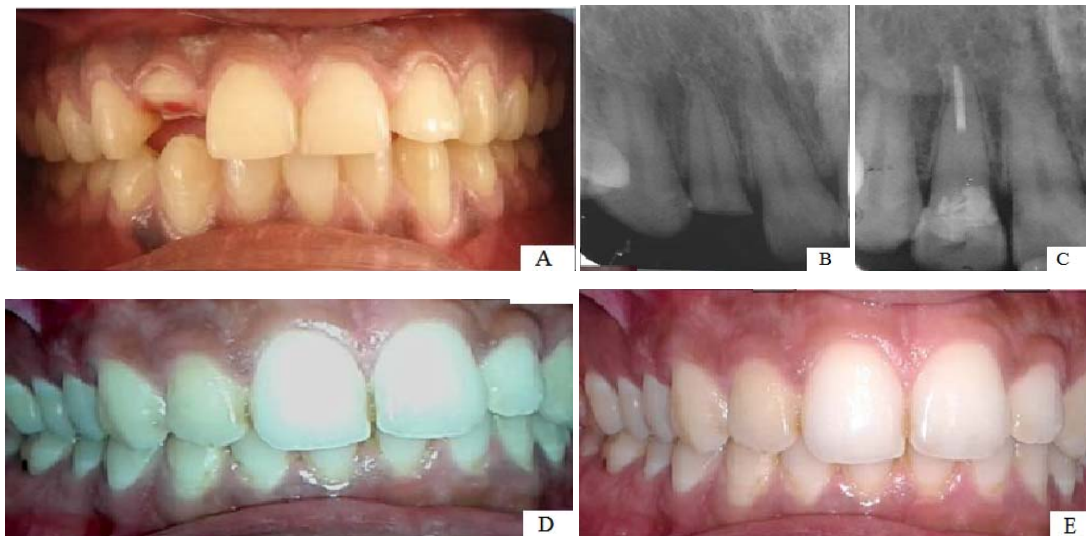


**Fig 2:** (A) Pre-operative view; (B) Fractured fragment - Lingual view; (C) Intraoral periapical radiograph showing reattached fragment; (D) Post-operative view; (E) 1 year follow up

**Case 3**

A 20-year-old male patient reported with a broken tooth in the maxillary anterior region. Patient gave a history of trauma few hours before. On clinical examination, it was found that there was a complicated horizontal crown fracture at the cervical margin of the tooth (Figure 3A). Periapical

radiograph revealed no further root fracture (Figure 3B). Root canal treatment was done followed by placement of fiber post on the same day. Reattachment procedure was done by means of over contouring and placement of internal groove. The patient was recalled after 3 months, 6 months and 1 year (Figure 3E) for follow up.



**Fig 3:** (A) Pre-operative view; (B) Pre-operative Intraoral peri-apical radiograph; (C) Intraoral periapical radiograph showing reattached fragment; (D) Post-operative view; (E) 1 year follow up

**Discussion**

Traumatic dental injuries in the permanent dentition necessarily involve function, aesthetics and psychological aspects particularly in young patients. Factors determining the treatment plan and prognosis for coronal teeth fractures include the extent of fracture, endodontic involvement, periodontal status, maturity of root, biological width invasion, presence / absence of fractured tooth fragment and the fit of the fragment and remaining tooth, occlusion, esthetics and finances. Depending on these factors, various treatment options are composite restorations, orthodontic / surgical extrusion, crown lengthening followed by post and core supported restorations and reattachment of fractured fragment.

Reattachment of a fragment to the fractured tooth can provide good and long-lasting esthetics because the tooth's original anatomic form, color, and surface texture are maintained. This treatment procedure is simple, can restore function, and result in a positive psychological response. In addition, tooth fragment reattachment allows restoration of the tooth with minimal sacrifice of the remaining tooth structure. Furthermore, this technique is less time-consuming and provides a more predictable long-term wear than when direct composite is used. Clinical trials and long-term follow-up have reported that reattachment using modern dentin bonding agents or adhesive luting systems may achieve functional and esthetic success [4].

The success of the reattachment depends on several factors and hydration of the fractured segment while outside the oral cavity is one of them. This is necessary to prevent dehydration and discoloration of the tooth and also to ensure adequate bond strength. It was reported that this partial loss of dentin moisture and its shrinkage results in the reduction of the composite surface contact with dentin. In all the three reported cases, after the coronal segment was separated, hydration was ensured by placing them in sterile isotonic saline. According to the literature, the best storage environments are milk and saliva as little osmotic and dimensional changes happen in the dentin surface with these storage media and thus achieved stronger bond strengths<sup>[5, 6]</sup>. Single Bond 2 (total etch adhesive system) was used in all the cases in order to have a durable and strong enamel bond along with an acceptable dentin bond, and not the self-etching systems which have a weaker enamel bond<sup>[7]</sup>.

Extensive damage of the tooth structure and reattachment of the fragment warrants reinforcement with fiber posts. In all the reported cases, pre-fabricated glass fiber posts were used due to their advantages like esthetically pleasing, are more flexible than metal posts and have approximately the same modulus of elasticity as dentin. When such posts were bonded in place with resin cement, researchers thought, forces would be distributed more evenly in the root, resulting in fewer root fractures. In addition, the fiber-reinforced posts can be used with minimal preparation because resin cement uses the undercuts and surface irregularities to increase the surface area for bonding and they are relatively easy to remove. In theory, a post that flexes together with the tooth during function should result in better stress distribution and fewer fractures<sup>[8]</sup>.

Several aspects may govern the choice of a reattachment technique. Therefore, most concerns about reattachment techniques have been directed toward the fracture strength of the restored tooth. Clinicians have employed an assortment of bevel designs, chamfers, dentinal and enamel grooves, and choices of resin composite materials and techniques for the reattachment of tooth fragments<sup>[4]</sup>.

Reis *et al* (2001)<sup>[9]</sup> have shown that a simple reattachment with no further preparation of the fragment or tooth was able to restore only 37.1% of the intact tooth's fracture resistance, whereas a buccal chamfer recovered 60.6% of that fracture resistance; bonding with an overcontour and placement of an internal groove nearly restored the intact tooth fracture strength, recovering 97.2 and 90.5% of it, respectively<sup>[9]</sup>.

In over contouring, good performance could be attributed to enlargement of adhesion area provided by tooth preparation around the fracture site. The greater extension of material on the surface provides better force distribution over a large enamel area, contrary to the simple reattachment, where the stress concentration is in the fracture line. Placement of internal dentinal groove may provide excellent fracture strength and higher esthetic durability almost similar to over contouring. It is likely that the greater adhesion area and permeability of an internal resin bar acts as an opponent to the compression load applied on buccal surface could be responsible for the good results. So in all the reported cases, internal grooves were placed in the fragment and over contouring was done in the last two cases where the buccal enamel tooth structure is available.

## Conclusion

Reattachment technique is the most conservative and biological method of restoring a fractured anterior tooth.

Reattaching a tooth fragment with newer adhesive materials may be used successfully to restore fractured teeth with adequate strength, but long term follow up is necessary in order to predict the durability of the tooth-adhesive-fragment complex. Patient cooperation and understanding of the limitations of the treatment is of utmost importance for good prognosis. The need of the day is to educate the population to preserve fractured segment and seek immediate dental treatment.

## References

- 1 Andreason JO, Andreason FM, Andreason L. Crown-root fractures. Textbook and color atlas of traumatic injuries to the teeth. 4<sup>th</sup> ed. Wiley Black well, 2007; 280-90.
- 2 Reis A, Loguercio AD, Kraul A, Matson E. Reattachment of fractured teeth: a review of literature regarding techniques and materials. Oper Dent 2004; 29(2):226-233.
- 3 Pagliarini A, Rubini R, Rea M, Campese M. Crown fractures: effectiveness of current enamel dentin adhesives in reattachment of fractured fragments. Quintessence Int 2000; 31:133-6.
- 4 Macedo GV, Diaz PI, De O Fernandes CA, Ritter AV. Reattachment of anterior teeth fragments: a conservative approach. J Esthet Restor Dent 2008; 20(1):5-18.
- 5 Shirani F, Malekipour MR, Tahririan D, Sakhaei Manesh V. Effect of storage environment on the bond strength of reattachment of crown fragments to fractured teeth. J Conserv Dent 2011; 14(3):269-72.
- 6 Sharmin DD, Thomas E. Evaluation of the effect of storage medium on fragment reattachment. Dent Traumatol 2013; 29(2):99-102.
- 7 Goracci C, Sadek FT, Monticelli F, Cardoso PE, Ferrari M. Microtensile bond strength of self-etching adhesives to enamel and dentin. J Adhes Dent 2004; 6:313-8.
- 8 Badami V, Reddy SK. Treatment of complicated crown-root fracture in a single visit by means of rebonding. J Am Dent Assoc 2011; 142(6):646-50.
- 9 Reis A, Francci C, Loguercio AD. Re-attachment of anterior fractured teeth: fracture strength using different techniques. Oper Dent 2001; 26(3):287-94.