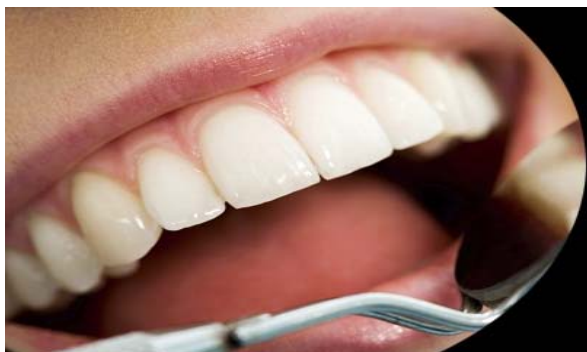



ISSN Print: 2394-7489
ISSN Online: 2394-7497
IJADS 2016; 2(2): 11-13
© 2016 IJADS
www.oraljournal.com
Received: 03-02-2016
Accepted: 04-03-2016

Dr. Deshpande Prashanth
BDS, MDS Reader, Dept. of
Conservative Dentistry &
Endodontics, S B Patil Dental
College, Bidar - 585402,
Karnataka, India. BDS,

Dr. Rutika R Naik
BDS, MDS Senior Lecturer,
Dept. of Conservative Dentistry
& Endodontics, S B Patil Dental
College, Bidar - 585402,
Karnataka, India.

Dr. K Shashikala
BDS, MDS Professor & Head of
the Dept. Dept. of Conservative
Dentistry & Endodontics,
D A Pandu Memorial R V
Dental College, Bangalore –
Karnataka, India.

Dr. Kirankumar Metta
BDS, MDS Assistant Professor,
Dept. of Conservative Dentistry
& Endodontics, Ibn Sina
National College for Medical
Studies, Jeddah.

Dr. Prashanth BR
Reader, Dept. of Conservative
Dentistry & Endodontics,
KLE Institute of Dental Sciences
& Research, Bangalore, India.

Correspondence

Dr. Deshpande Prashanth
BDS, MDS Reader, Dept. of
Conservative Dentistry &
Endodontics, S B Patil Dental
College, Bidar - 585402,
Karnataka, India. BDS,

**Hybrid Richmond crown - A novel technique for reattachment
of complicated fractured crown segment: A case report**

**Dr. Deshpande Prashanth, Dr. Rutika R Naik, Dr. K Shashikala,
Dr. Kirankumar Metta, Dr. Prashanth BR**

Abstract

Background: Maxillary central incisor is most commonly affected tooth during trauma followed by maxillary lateral incisor and mandibular incisors. Trauma to the anterior tooth requires urgent care because of essentiality of preserving natural tooth. When complicated crown fracture occurs it necessitates endodontic treatment and restoration of fractured crown segment with post in the canal.

Case-report: A male patient of age 18 years reported to the S.B. Patil Dental Hospital, Bidar for dental trauma to the maxillary left central incisor with pulp exposed but palatal tooth structure holding the fractured crown segment. Patient had fight with his colleague one day before and suffered a blow onto his front tooth. Fractured crown segment removed and stored in normal saline. Two visit root canal treatment planned and performed. After two days, post space prepared, indirect impression with putty light body taken for indirect post. Then appropriate glass fiber post selected and para core composite added onto the post to get custom-fit conical post. Putty with light body impression taken to get cast with post space in which conical post checked for snugly fit. Now Modified conical post bonded to fractured crown segment using resin cement and the whole unit resembling Richmond crown, referred to as Hybrid Richmond crown bonded into the root canal using resin cement. Minute visible cracked line labially and palatally restored with direct composite veneering. After 12 months follow-up shows healthy tooth structure and surrounding tissue.

Conclusion: Here a special technique of crown fracture reattachment documented (Hybrid Richmond crown) – in which custom made conical glass fiber post attached to fractured crown segment and bonded into the root canal using resin cement which gives Monoblock effect. The case represents better transfer and distribution of forces along the long axis of tooth and also long term survival of the tooth.

Keywords: Crown fracture, Hybrid Richmond crown, Monoblock effect

1. Introduction

In the teen and young adult years dental injuries result from motor vehicle accidents, sports, and accidental falls. The largest number of dental injuries to young male enlisted occurring after school hours as a result of fistfights [1]. A fourth of the dental injuries in the public schools have been observed to be due to fighting and pushing [2]. The most vulnerable tooth is the maxillary central incisor, which sustains approximately 80% of the dental injuries, followed by the maxillary lateral and the mandibular central and lateral incisors [3]. A major predisposing factor in dental injuries is overjet of the maxillary incisors. The reported incidence of crown fractures varies from 26% to 92% of all traumatic injuries to the permanent dentition [4]. The wide variation in reported incidence is due to the diversity of sampling techniques and classification of injuries. Crown fractures may be of chisel-type or oblique limited to the crown. If the fracture is deep into the dentin it may complicate by involving the pulp, which necessitates root canal treatment. The advantage of root canal treatment gives an opportunity to increase the coronal reinforcement by incorporating the post into the root canal.

| Year | Description |
|-------------|-------------------------------------------------------------------------------------------------------------------------------------------------------------------------------------------------------------------|
| 1728 | Pierre Fauchard introduced "tenon," which is metal post screwed into the root of the teeth to retain the bridge [5]. |
| Mid - 1800s | "pivot crown," a wooden post fitted to an artificial crown and into the root canal [5]. |
| 1878 | The Richmond crown introduced in 1878 and incorporated as threaded tube in the canal with Screw-retained crown. It later modified to eliminate the threaded tube and redesigned as a 1-piece dowel and crown [6]. |
| 1930s | During the 1930s, the custom cast post-and-core developed to replace the one-piece post crowns. |

2. Case – Report

A 18 year old male patient reported to the Department of Conservative Dentistry and Endodontics with trauma to the maxillary left central incisor (fig 1). The patient had a fight during sport and suffered injury to his front tooth 2 days back. Clinical examination revealed a complicated oblique crown fracture with fractured part slightly mobile. After removing fracture mobile tooth structure it showed widely open pulp chamber. The tooth showed tender on percussion and on radiographic examination revealed widened apical periodontal ligament space (fig 2). The treatment options explained to the patient like

- a) No treatment – leaving the condition of the tooth as it is and keeping under medication till severe pain or swelling occurs.
- b) Extraction followed by tooth replacement
- c) Endodontic treatment followed by prefabricated post, composite core build up and ceramic crown placement.
- d) Options of possible reattachment of fractured tooth by union of custom made prefabricated post and natural fractured tooth fragment.

All about the advantages, disadvantages, cost/benefit and prognosis of treatment options discussed with the patient and explained the procedures and patient finally decided to go for reattachment of fractured tooth using hybrid Richmond crown technique. Patient informed consent taken.

The tooth is anesthetized using local anesthesia. The fractured tooth fragment removed and stored under normal saline. The tooth isolation done with rubber dam and two visit endodontic treatment carried out. The post space prepared till the coronal gutta percha using Para Post (Coltene Whaledent, USA) drill sizes 5. and light transmitting fiber ParaPost Fiber Lux size 5(1.25mm) checked for snug fit and confirmed with radiograph. In this case, parallel ParaPost is made conical by bonding ParaCore automix, dual cure core (Coltene Whaledent, USA) material onto the middle & coronal third of the post. For making final impression, the canal was coated with light body impression material (Impressiv) and then a small piece of orthodontic wire, coated with light body was placed in the canal. Later light body was injected around the prepared tooth, putty impression material (Perfit) was loaded in stock tray and final impression is made and cast poured. The accuracy of the post modified for snug fit (fig 3, 4).

. The custom modified conical post is initially bonded to the fractured tooth structure using ParaCem universal dual core cement (Coltene Whaledent, USA). Small retentive grooves prepared on the internal aspect of fractured crown fragment, any necrosed pulp tissue removed. Now the entire fractured tooth fragment and conical post is one unit and resemble richmond crown, as it is combination of prefabricated ParaPost, ParaCore bonded onto ParaPost and fractured natural tooth structure, it is termed as “HYBRID RICHMOND CROWN” (fig 5). This entire unit is checked into the canal and bonded into the canal using ParaCem. All the bonding procedures were done according to manufacturer’s instructions. The rough margin present labially as well as palatally made smooth and extra cement removed using composite polishing kit Soflex (Shofu, Japan) (fig 6, 7). Anterior Deep bite checked and made free of occlusion. Patient re-called every 3 months and after 12 months follow-up showed no gingival inflammation, healthy periodontium, intact tooth structure with no symptoms.

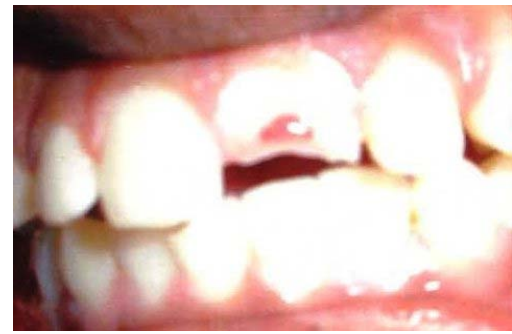

Fig 1: Pre-Operative View

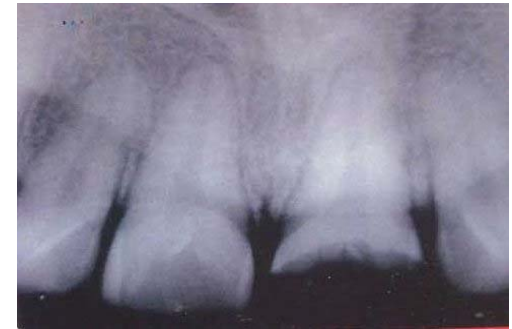

Fig 2: Pre-Operative Iopa X-Ray

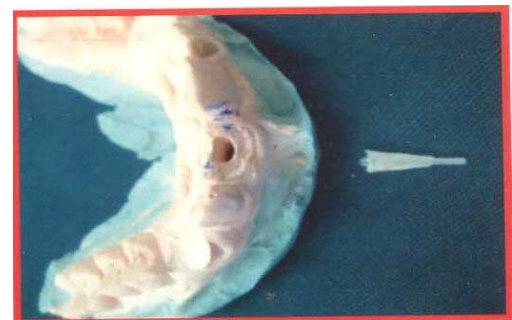

Fig 3: Cast and Conically Modified Glass Fiber Post

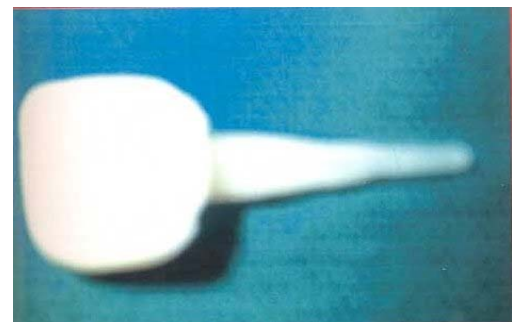


Fig 4: Conical Custom Glass Fiber Post Bonded To Fractured Natural Tooth Fragment Resembling RICHMOND CROWN

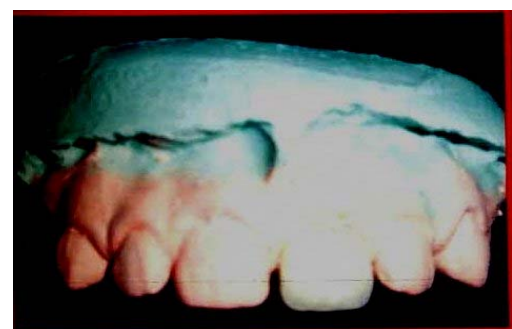

Fig 5: Hybrid Richmond Crown on Cast

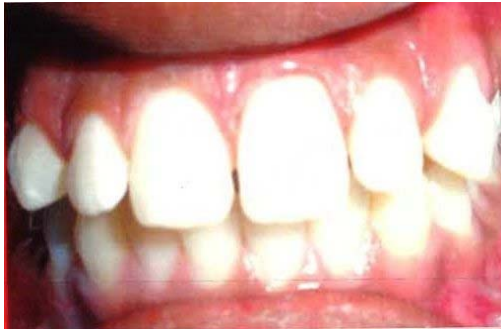

Fig 6: Post-Operative

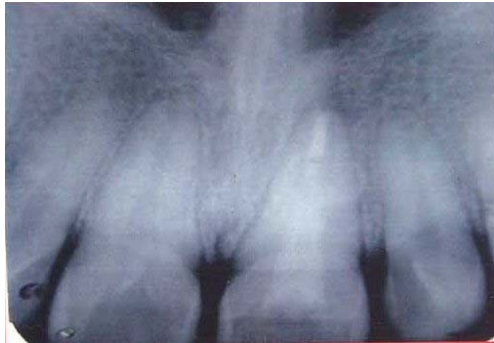

Fig 7: Post-Operative View Iopa

3. Discussion

Adhesive material development created newer perspective in fractured teeth reconstruction.

Nowadays the reattachment of fractured tooth is successful because of the advancement in the development of bonding agents, which is essential to have good bonding to the tooth structure. During reattachment various biological conditions, various materials used and the technique employed are carefully assessed and managed accordingly. Whenever possible the fractured segment should be reattached and should be the first choice [7, 8].

The advantages of the reattachment is it will give positive psychological response to the patient, it will be economical compared to other treatment modalities like extraction and replacement, also the colour of the fractured tooth in reattachment will match to the adjacent tooth and also the original contour will be well maintained [7, 8].

Crown fracture involving pulp requires endodontic therapy and the advantage of pulp space after endodontic therapy is used as inner reinforcement which will avoid cutting of sound tooth structure [8]. The post increases retention and transfer the forces along the long axis of the root. The glass fiber post, the core material added onto the glass fiber post, the resin cement bonded to the post as well as to the root canal and coronal tooth structure forms a MONOBLOCK EFFECT [10].

In this case report, the reattachment of fractured tooth fragment done by making hybrid richmond crown, which means the parallel glass fiber post modified and made conical post and fractured tooth structure bonded to the post and all in toto cemented into the canal using standard manufacturer's instructions. As the whole hybrid richmond crown is in contact with root dentinal wall and crown portion, it will transfer and distribute the masticatory forces all along the long axis of the root. Preserving the lost tooth structure by maintaining the original colour and contour of the fracture tooth fragment was maintained and made to look similar like the adjacent tooth. Clinically the follow-up done for the periodontal examination, swelling, sinus opening all were evaluated but none of the symptoms were seen which was in accordance with other

studies [11-13]. But it needs several other studies regarding the long term survival of the tooth and prognosis of the reattachment.

4. Conclusion

The tooth fragment reattachment was a successful method of treatment. The combination of parallel glass fiber post, core build up resin composite added onto the post to make it conical, exactly configuring tightly & snugly fitting into the root canal wall and the coronal fractured fragment attached to the conical modified post using bonding agent. And all this resembling Richmond crown termed as HYBRID RICHMOND CROWN, is cemented into the root canal using resin cement and this new technique was found to be successful. Patient was highly satisfied but before recommending this study for routine use, it requires long term follow-up and also the prognosis should be compared in response to other extraction and replacement techniques.

5. References

1. Katz RV. Epidemiological survey of accidental dentofacial injuries among U.S. Army personnel, *Community Dent. Oral Epidemiol* 1979; 7:30.
2. Carter AP. Dental injuries in Seattle's public school children: school year 1969-70, *J Public Health Dent*. 1972; 32:251.
3. Ferguson FS, Ripa LW. Prevalence and type of traumatic injuries to the anterior teeth of preschool children, *J Pedod.* 1979; 4:3.
4. Andreasen JO. *Traumatic injuries of the teeth*, ed. 2, Philadelphia, W.B. Saunders Co, 1981.
5. Smith CT, Schuman NJ, Wasson W. Biomechanical criteria for evaluating prefabricated post- and -core systems: a guide for the restorative dentist. *Quintessence Int* 1998; 29:305-312.
6. Smith CT, Schuman N. Prefabricated post-and-core systems: an overview. *Compend Contin Educ Dent*. 1998; 19:1013-1020.
7. Yucel Yihnaz, Cigdem Zehir, Ozge Eyuboglu, Nihal Belduz. Evaluation of success in the reattachment of coronal fractures. *Dent Traumatol* 2008; 24:151-158.
8. Georgia Macedo V, Patricia Diaz I. Carlos Augusto. Reattachment of anterior teeth fragments: A conservative approach. *J esthetic Restor Dent* 2008; 2:5 -20.
9. Villat C, Machtou P Naulin – Ifi C. Multidisciplinary approach to the immediate esthetic repair and long term treatment of an oblique crown – root fracture. *Dent Traumatol* 2004; 20:56-50.
10. Franklin Tay R, David Pashley H. Monoblocks in root canals: A hypothetical or a Tangible Goal. *J Endod.* 2007; 33:391-398.
11. Chu FCS, Yim TM, Wei SHY. Clinical considerations for reattachment of tooth fragments. *Quintessence Int* 2000; 3:385-91.
12. Rappelli G, Massaccesi C, Patignano A. Clinical procedures for the immediate reattachment of a tooth fragment. *Dent Traumatol* 2002; 18:281-84.
13. Worthington RB, Murchison DF, Vandewalle KS. Incisal edge reattachment; the effect of preparation utilization and design. *Quintessence Int* 1999; 30:637-43.