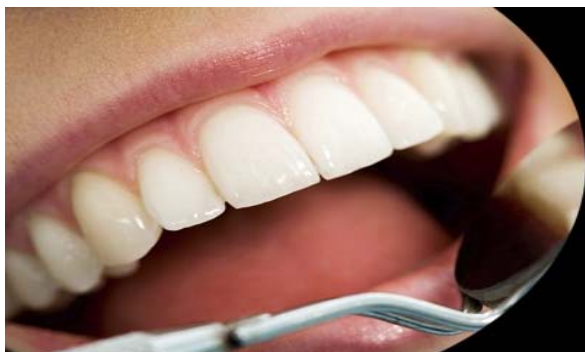



ISSN Print: 2394-7489
ISSN Online: 2394-7497
IJADS 2016; 2(2): 71-73
© 2016 IJADS
www.oraljournal.com
Received: 09-02-2016
Accepted: 10-03-2016

Dr Bijo Kurian

Postgraduate student,
Dept. Conservative dentistry and
endodontics Dayananda Sagar
College of dental sciences

Dr Swapna D V

Reader,
Dept. Conservative dentistry and
endodontics Dayananda Sagar
College of dental sciences

Dr Roopa R Nadig

Head of the department,
Dept. Conservative dentistry and
endodontics Dayananda Sagar
College of dental sciences

Dr Vedawathi B

Reader
Dept. Conservative dentistry and
endodontics Dayananda Sagar
College of dental sciences

Correspondence

Dr Bijo kurian

PG student,
Dept. Conservative dentistry and
endodontics Dayananda Sagar
College of dental sciences

Hemisection-Survival of fittest

Dr. Bijo Kurian, Dr. Swapna DV, Dr. Roopa R Nadig, Dr. Vedawathi B

Abstract

Every natural tooth must be given a chance to survive as long as possible. Teeth which are periodontally diseased with severe bone loss, vertical root fracture, therapeutic mishaps, decay, resorption, around one root may well be retained by removal of diseased root by hemisection. This article describes a procedure of hemisection in mandibular molar with periodontally compromised distal root and its subsequent prosthetic restoration, which yielded a satisfactory result.

Keywords: Hemisection, Furcation, Bone loss, Prosthetic Rehabilitation

1. Introduction

A molar with extensive decay, periodontal problem or a root fracture is difficult to restore. The treatment options for such situations are limited and may include extraction of involved tooth followed by placement of partial denture/bridge or a dental implant to replace the missing tooth [1]. Alternative treatment option of removing only the diseased part of root (hemisection), can be undertaken in specific situations. The treatment may involve combining restorative dentistry, endodontics, periodontics and prosthodontics so that the teeth are retained in whole or in part. Thus hemisection procedures are conservative treatment modality used to preserve as much tooth structure as possible rather than sacrificing the whole tooth [2, 3, 4]

Hemisection (removal/surgical separation of one root) involves removing significantly compromised root structure and the associated coronal structure through deliberate excision [5, 6]. Weine [7] has listed the following indications for tooth resection:

Periodontal Indications

1. Severe vertical bone loss involving only one root of multi-rooted teeth.
2. Through and through furcation destruction.
3. Unfavourable proximity of roots of adjacent teeth, preventing adequate hygiene maintenance in proximal areas.
4. Severe root exposure due to dehiscence.

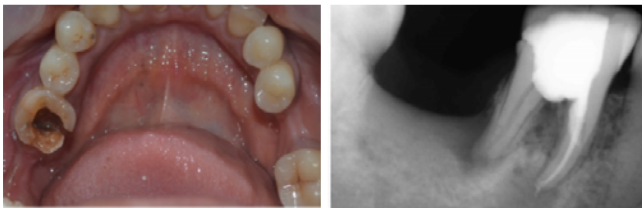Endodontic and Restorative Indications

1. Prosthetic failure of abutments within a splint: If a single or multi-rooted tooth is periodontally involved within a fixed bridge, instead of removing the entire bridge, if the remaining abutment support is sufficient, the root of the involved tooth is extracted.
2. Endodontic failure: Hemisection is useful in cases in which there is perforation through the floor of the pulp chamber, or pulp canal of one of the roots of an endodontically involved tooth which cannot be instrumented.
3. Vertical fracture of one root: The prognosis of vertical fracture is hopeless. If vertical fracture traverses one root while the other roots are unaffected, the offending root may be amputated.
4. Severe destructive process: This may occur as a result of furcation or sub gingival caries, traumatic injury, and large root perforation during endodontic therapy.

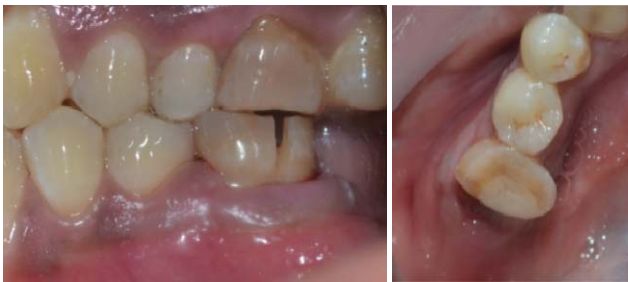The treatment goal is preservation of remaining tooth structure and restoration of the function. This case report describes hemisection procedure which was chosen to retain the endodontically treated mesial root of mandibular left first molar and extraction of periodontally involved distal root.

Case report

35 years old female patient reported with the chief complaint of pain in left mandibular first molar. On examination, the tooth was sensitive to percussion. On probing, there was a 13mm deep periodontal pocket around the distal root of the tooth with grade I mobility.

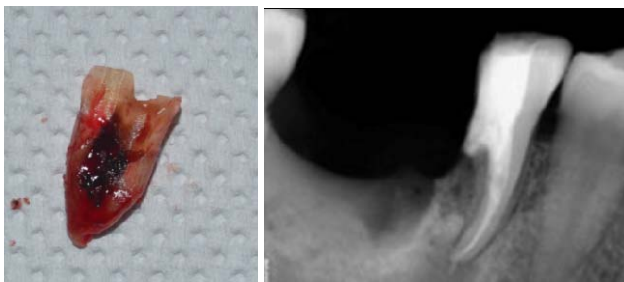


Pre-operative



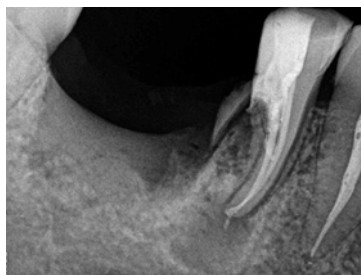
Placement of grooves

after hemisection

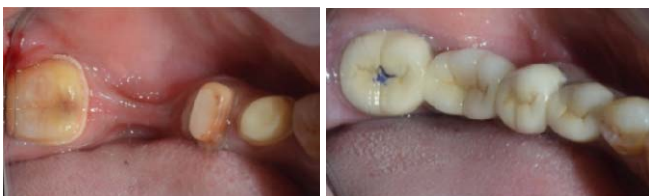

Hemisected root

post-operative radio graph



3 month follow up



Crown pre-paration

Permanent crown cemented

On radiographic examination, extensive vertical bone loss was evident surrounding distal root involving the furcation area. The bony support of mesial root was completely intact. It was decided that the distal root should be hemisected after completion of endodontic therapy of the tooth. The working length was determined and the canals were biomechanically

prepared using Protaper (F2). The canals were obturated with single cone method and the access cavity was restored with composite resin.

Under local anesthesia, the vertical cut method was used to respect the crown. A long shank tapered fissure carbide bur was used to make vertical cut toward the bifurcation area. A fine probe was passed through the cut to ensure separation. The distal root was extracted and the socket was irrigated adequately with sterile saline to remove bony chips.

The reduced molar resembled premolar in shape. A temporary bridge was seated during healing and consolidation phase to prevent drifting of the remaining root. Definitive restoration therapy was accomplished 3 months after hemisection. A four unit bridge with sanitary pontic replaced second molar and distal root of first molar with retained mesial half of mandibular first molar (36), mandibular second premolar (35) and mandibular third molar (38).

Discussion

Success of hemisection/any resection procedures are predictable, if certain basic consideration are taken into account^[8, 9]. They being^[5, 10].

1. Advanced bone loss around one root with acceptable level of bone around the remaining roots.
2. Angulation and position of the tooth in the arch. A molar that is buccally, lingually, mesially or distally titled, cannot be respected.
3. Divergence of the roots - teeth with divergent roots are easier to resect.
4. Closely approximated or fused roots are poor candidates.
5. Length and curvature of roots - long and straight roots are more favourable for resection than short, conical roots.
6. Feasibility of endodontics and restorative dentistry in the root/roots to be retained.

Added on, patient's oral hygiene, caries index and medical status should be considered^[2]. However, there are few disadvantages associated with it. As with any surgical procedure, it can cause pain, anxiety and the site of hemisection are more susceptible to caries. Often a favourable result may be negated by decay after treatment. Failure of endodontic therapy due to any reason will cause failure of the procedure^[10].

Present case, showed excessive bone destruction around distal half of distal root by vertical bone loss and grade I mobility. But the mesial root had adequate bone support and hence, hemisection was carried out with removal of the distal root and crown and preservation of mesial root of 36.

Unfortunately, a restoration can contribute to periodontal destruction, if the margins are defective or do not have physiologic form. Also, an improperly shaped occlusal contact area may convert acceptable forces into destructive forces and predispose the tooth to trauma from occlusion and ultimate failure of hemisection^[10]. Here an occlusal table for retained mesial root of 36 was reduced by giving a premolar form, thus reducing trauma from occlusion and a single sanitary molar pontic was used for space closure. Lateral forces were reduced by making cuspal inclines less steep and eliminating balancing incline contacts^[3, 11, 12].

Park *et al.*^[13]. Have suggested that hemisection of molars with questionable prognosis can maintain the teeth without detectable bone loss for a long-term period, provided that the patient has optimal oral hygiene.

Saad *et al.*^[8]. have also concluded that hemisection of a mandibular molar may be a suitable treatment option when the decay is restricted to one root and the other root is healthy and

remaining portion of tooth can very well act as an abutment. Also, Fugazzotto reported 15-year cumulative success rates of 96.8% for root resected molars and 97% for molar implants [14]. The use of hemisection to retain a compromised tooth offers a prognosis comparable to any other tooth with endodontic treatment [15].

This clinical report illustrates solution to the endo-perio problem by hemisection and fixed partial dentures [16]. Although such involvement diminishes the long-term prognosis of the affected tooth, extraction is not always an option. Root resection therapy is one of the several treatment modalities that can be used in such cases.

Conclusion

The prognosis for hemisection is the same as for routine endodontic procedures provided that the case selection has been correct, the endodontic therapy has been performed adequately and the restoration is of an acceptable design relative to the occlusal and periodontal needs of the patient.

References

1. Saurabh Yadav. Hemisection-divide&rule: a case report, journal of dental Sciences &oral rehabilitation, 2012.
2. Atul Jain, Rachana Bahuguna. Hemisection as an Alternative Treatment for Resorbed Multirooted Tooth - A Case Report, Asian Journal of Oral Health & Allied Sciences, 2011, 1(1),
3. Parmar G. Hemisection: a case report and review. Endodontology, 2003, 15.
4. Behl AB. Hemisection of a Multirooted Tooth-A Case Report, 2012; 1:336. doi:10.4172/scientificreports.336
5. Bühler H. Survival rates of hemisected teeth: an attempt to compare them with survival rates of alloplastic implants. Int J Periodontics Restorative Dent. 1994; 14(6):536-543.
6. Weine FS, Endodontic Therapy, Mosby, St Louis, Mosby, USA, 5th edition, 154-168.
7. Saad. Hemisection as an alternative treatment for decayed multirooted terminal abutment, a case report, JCDA, 2009.
8. Kurtz GM, Silverstein LH. Hemisection as an alternative treatment for vertically fractured mandibular molars. Compend contin educ dent 2006; 27(2):126-9.
9. Park JB. Hemisection of teeth with questionable prognosis. Report of a case with seven-year results; J Int Acad Periodontol. 2009; 11(3):214-9.
10. Kost WJ, Stakiw JE. Root amputation and Hemisection J Can Dent Assoc. 1991; 57(1):42-45.
11. Bashutski JD, Wang HL. Common implant esthetic complications. Implant Dent 2007; 16:340-348.
12. Rapoport RH, Deep P. traumatic hemisection and restoration of maxillary first premolar: a case report. Gen Dent 2003; 51:340-342.
13. Park Shin, Yang Kye. Factors influencing the outcome of root resection therapy in molars: A 10 year retrospective study, Periodontol, 2009.
14. Fugazzotto PA. A comparison of the success of root resected molars and molar position implants in function in a private practice: Results of up to 15-plus years. J Periodontol. 2001; 72:1113-1123.
15. Savitha Tooth. Hemisection & Restoration an alternative to extraction-a case report, International journal of dental clinic, 2011.
16. Nowakowski T. Anthony, Serebnitski Alex, Hemisection as a treatment option: a case report. Oral health journal. 2010.

17. Carranza's Clinical Periodontology, 10th edition
18. Clinical periodontology and oral implantology by Jan Lindhe.
19. Ingles, Endodontics, 6th edition