



ISSN Print: 2394-7489
ISSN Online: 2394-7497
IJADS 2016; 2(4): 34-37
© 2016 IJADS
www.oraljournal.com
Received: 10-08-2016
Accepted: 11-09-2016

Dr. Shantipriya Reddy
Professor Head, Department of
Periodontics, Dr. Syamala
Reddy Dental College, Hospital
and Research Centre, Bengaluru-
560037, Karnataka, India

Dr. Prasad MGS Reader
Reader, Department of
Periodontics, Dr. Syamala
Reddy Dental College, Hospital
and Research Centre, Bengaluru-
560037, Karnataka, India

Dr. Nirjhar Bhowmik
Sr. Lecturer, Department of
Periodontics, Dr. Syamala
Reddy Dental College, Hospital
and Research Centre, Bengaluru-
560037, Karnataka, India

Dr. Savita Singh
Sr. Lecturer, Department of
Periodontics, Dr. Syamala
Reddy Dental College, Hospital
and Research Centre, Bengaluru
560037, Karnataka, India

Dr. Huzaifa Rashid Pandit
Post Graduate Student,
Department of Periodontics,
Dr. Syamala Reddy Dental
College, Hospital and Research
Centre, Bengaluru- 560037,
Karnataka, India

Dr. Vimal SK
Post Graduate Student,
Dept. of Conservative Dentistry
and Endodontics,
Krishnadevaraya College of
Dental Sciences, Karnataka,
India

Correspondence

Dr. Huzaifa Rashid Pandit
Post Graduate Student,
Department of Periodontics,
Dr. Syamala Reddy Dental
College, Hospital and Research
Centre, Bengaluru- 560037,
Karnataka, India

Vestibular incision subperiosteal tunnel access (VISTA) with platelet rich fibrin (PRF) and connective tissue graft (CTG) in the management of multiple gingival recession- A case series

**Dr. Shantipriya Reddy, Dr. Prasad MGS, Dr. Nirjhar Bhowmik,
Dr. Savita Singh, Dr. Huzaifa Rashid Pandit and Dr. Vimal SK**

Abstract

Gingival recession is clinically manifested by an apical displacement of the gingival tissues, leading to root surface exposure. It is a concern for both patients and clinician for several reasons such as root hypersensitivity, erosion, root caries, and esthetics. Recently, new techniques have been suggested for the surgical treatment of multiple adjacent recession type defects. The current case series introduce a novel, minimally invasive approach applicable for both isolated recession defects as well as multiple contiguous defects in the maxillary anterior region. This case series describes the use of the vestibular incision subperiosteal tunnel access (VISTA) technique in combination with platelet-rich fibrin (PRF) membrane and VISTA with connective tissue graft (CTG) the treatment of GR defects. To the best of the authors' knowledge, this is the first report on the use of the PRF membrane and CTG – reinforced VISTA technique for treating multiple gingival recession defects.

Case Series: Four patients with multiple GRs were selected for this case series. The VISTA technique allowed coronal repositioning of the gingival margin, which was then stabilized by the coronally anchored suturing technique. PRF membrane was inserted inside the subperiosteal tunnel for group I and CTG for group II, and the vertical incision was sutured. Patients were kept under observation for 6 months.

Conclusion: This use of PRF membrane and CTG along with the VISTA technique allows clinicians to successfully treat multiple GR defects.

Keywords: Platelet rich fibrin, connective tissue graft, gingival recession, tunnel technique, sutures, wound healing

1. Introduction

Gingival recession is defined as apical migration of gingival margin beyond the cemento-enamel junction (CEJ) [1]. Main indications for root coverage procedures are aesthetic concern, dentinal hypersensitivity, prevention of root caries and cervical abrasion, improve plaque control efforts [2]. The treatment of recession defects associated with multiple teeth poses greater challenge to clinician as avascular root surface area is more extensive. Also, thin biotype, decreased keratinized tissue width (KTW), root prominence and root proximity make the choice of surgical treatment difficult as compared to localized gingival recession type defects [3]. Different tunnel techniques that can maintain the better blood supply and maintain critical papillary integrity have been attempted for management of recession defects. However, these procedures are technique sensitive and tissue trauma to sulcular epithelium led to unfavorable healing outcomes as reported in some studies [4]. To avoid these complications in treatment procedures, the vestibular incision subperiosteal tunnel access (VISTA) approach was introduced.

Connective tissue graft (CTG) technique is the most commonly used free soft tissue graft showing predictable and reproducible results in root coverage. Thus, it is considered as a gold standard though it has its own limitations which include the need of a second surgical site and technique sensitive procedure [4]. Along with various techniques for root coverage procedure, adjunctive agents like recombinant human growth factors and platelet rich plasma, have been

Used to accelerate healing and further enhance clinical outcomes [5]. Platelet rich fibrin (PRF) a second generation platelet concentrate, has been used extensively in combination with bone graft materials for periodontal regeneration, ridge augmentation, sinus lift procedures for implant placement and for coverage of gingival recession defects in the form of a membrane [6]. It has become a focus of current studies because of its potential to accelerate healing [7]. The purpose of this case report is to evaluate clinically, the efficacy of the novel and minimally invasive VISTA in combination with PRF and CTG in the treatment of gingival recession defects.

2. Case Report

The study comprised of four patients with mean age of 30 years who came to the Department of Periodontology, Dr. Syamala Reddy Dental College, Hospital and Research Centre Bangalore with chief complaint of sensitivity to cold water in the upper front tooth region and anaesthetic appearance. No relevant medical and dental history was reported. Patients were segregated by flip of coin method. Clinical parameters were recorded and tabulated in table 1. All patients were treated by VISTA technique; Case 1 and 3- VISTA technique with PRF membrane. CASE 2 and 4 VISTA technique with CTG.

Case 1 presented with Miller Class I recession defect with respect to 11,12 and 13. After a baseline examination, the surgical site was anaesthetized. Recipient sites were prepared by thorough scaling and root planing.

The VISTA approach began with a vestibular access incision mesial to the recession defect. Subperiosteal tunnel was created, exposing the facial osseous plate and root dehiscence. This tunnel was extended at least one or two teeth beyond the teeth requiring root coverage so as to mobilize gingival margins and facilitate coronal repositioning with microsurgical periosteal elevator (VISTA 1 and VISTA 2, Dowell Dental Products). Additionally, the subperiosteal tunnel was extended interproximally under each papilla as far as the embrasure space permits, without making any surface incisions through the papilla, it is achieved by using elevator with bayonet curves (VISTA 3 and VISTA 4, Dowell Dental Products). Once coronal advancement of the gingival margin was established, for Case 1 the freshly prepared PRF membrane was trimmed and adjusted to cover the dehiscence on root through the subperiosteal tunnel with a fine tipped curved serrated forceps. The membrane and mucogingival complex were then advanced coronally and stabilized in the new position with a coronally anchored suturing, by placing a horizontal mattress suture at approximately 2 to 3 mm apical to the gingival margin of each tooth (or within the band of keratinized gingiva). The suture was then tied to position the knot at the mid coronal point of the facial aspect of each tooth, which was secured with help of composite resin to prevent apical relapse of the gingival margin during initial stages of healing. Periodontal dressing was placed to cover the surgical site.

Case 2 was a 32-year-old male who presented with Millers class I gingival recession defects, ranging from 1 to 2mm, on maxillary central incisor teeth. Application of VISTA technique to treat gingival recession in this case was similar as described above. Only difference was connective tissue being harvested from premolar-molar area of palate using double incision technique and secured in tunnel. The vertical incision was approximated and sutured. Sutures in the vestibular area were removed after 1 week and coronally anchored sutures were removed at the 3-week postoperative visit and followed up for 6 months. For both patients antibiotics and analgesic were prescribed and kept on strict oral hygiene maintenance.

Case 3 was a 30-year-old male who presented with Millers Class I gingival recession defects, ranging from 2 to 3 mm, involving 11,21 teeth. Application of VISTA technique to treat gingival recession in this case was similar as described above in conjunction with PRF.

Case 4 was a 27-year-old male who presented with Millers class II gingival recession defects, ranging from 1 to 4 mm, involving 22,23,24 teeth. Application of VISTA technique to treat gingival recession in this case was similar as described above in conjunction with CTG.

Placement of the initial incision and a tunnel entrance within the maxillary frenum results in little to no visible scarring, assisting in maximizing the esthetic outcome in this critical restorative area [4]

3. Results

The results demonstrated 100% root coverage in all the cases at 6 months respectively.

4. Discussion

Earlier periodontal therapy was limited to eliminate and to avoid disease by maintenance of a functional healthy dentition and supporting hard and soft tissues [8]. However, more recently periodontal therapy is increasingly directed at esthetic outcomes for patients. Patients have become more conscious of dental esthetics and are demanding precision treatment for exposed root surfaces [9].

Treatment of gingival recessions and achieving complete root coverage up to the cemento-enamel junction is the goal now. Furthermore, even if complete root coverage is surgically accomplished; the result in terms of esthetics may not be completely satisfactory in the case of excessive thickness of gingiva or poor blending of the area [14]. Growth factors present in PRF plays crucial role in hard and soft tissue repair. These growth factors include (PDGFs), epidermal growth factor (EGF), transforming growth factor beta (TGF- β), vascular endothelial growth factor (VEGF), insulin like growth factor-1 (IGF-1) [10]. Also these growth factors has been shown to accelerate bone repair and promote fibroblastic proliferation, increase tissue vascularization. Considering the fact that PRF may enhance the healing of soft tissues as well as bone, its placement under coronally positioned flap (CAF) in recession defects have been previously reported [11, 12] A recent 12-month study evaluated the use of PRF in the treatment of multiple gingival recessions with VISTA and found the significant improvement during the early periodontal healing phase with 96% root coverage [13].

The connective tissue graft is one of the most common mucogingival technique leading to predictable and reproducible results. Surgical techniques which resulted in unsatisfactory results could be due to poor case selection, improper technique, inadequate root preparation and insufficient blood supply.

The minimally invasive VISTA approach, combined with a PRF and CTG, has a number of advantages for the successful treatment of multiple recession defects: The vertical incision that is given mesial to the defect reduces the possibility of traumatizing the gingiva of the teeth being treated [4]. Also subperiosteal dissection reduces the tension of the gingival margin during coronal advancement and maintaining blood supply to interdental papillae.

In VISTA technique advancement of gingival margin with augmented membrane or graft coronal to CEJ and securing the gingival margin in fixed stable position to prevent relapse in earlier stage of healing gives better results in gingival recession coverage.

Table 1

Case no.	Tooth no.	Recession Height (Pre Op)	Recession Height (Post Op)	Root Coverage (%)
Case 1	11	2	0	100%
	12	1	0	100%
	13	2.5	0	100%
Case 2	11	2	0	100%
	21	1	0	100%
Case 3	11,	3	0	100%
	21	2	0	100%
Case 4	22	1	0	100%
	23	4	0	100%
	24	2	0	100%

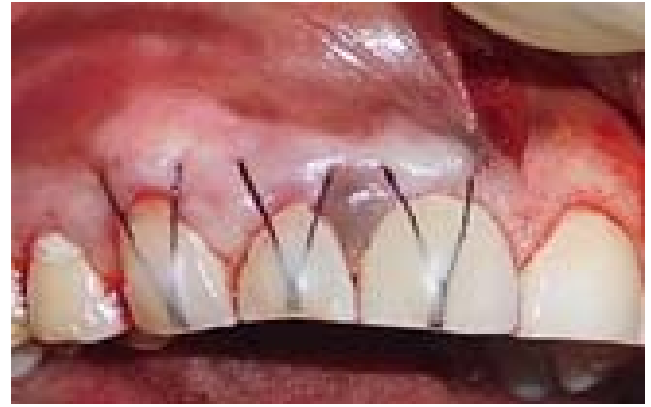

Fig 4: Case1 coronally anchored suture with composite stops

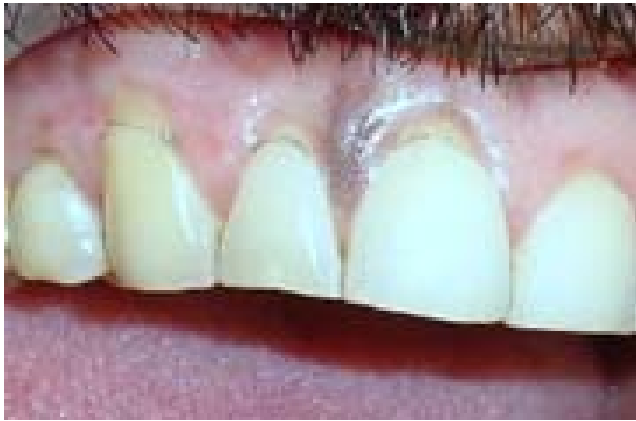

Fig 1: Case 1 preoperative view

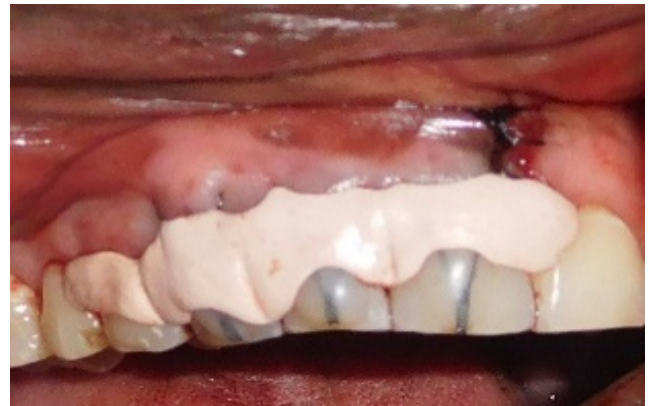

Fig 5: Case 1 periodontal dressing placed

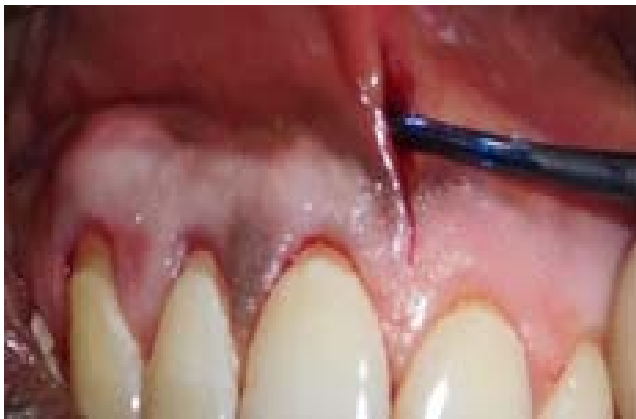

Fig 2: Case 1 Periosteal tunnel preparation

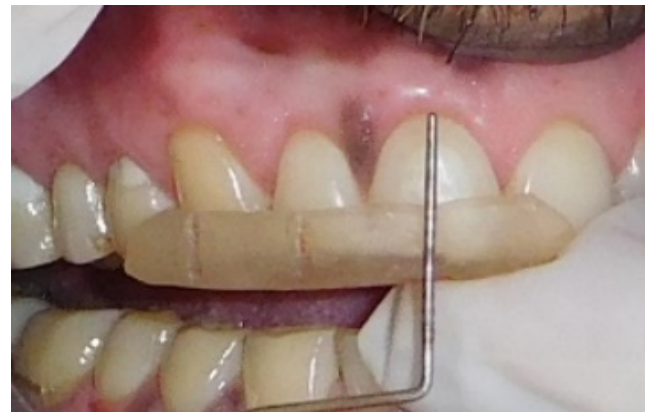

Fig 6: Case 1 Post-operative 6 month

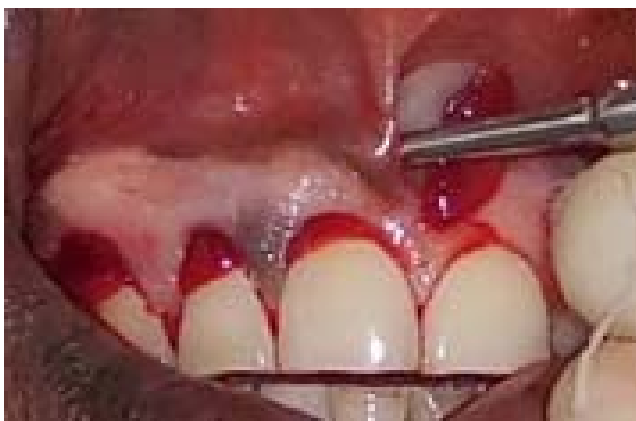


Fig 3: Case 1 Insertion of platelet rich fibrin

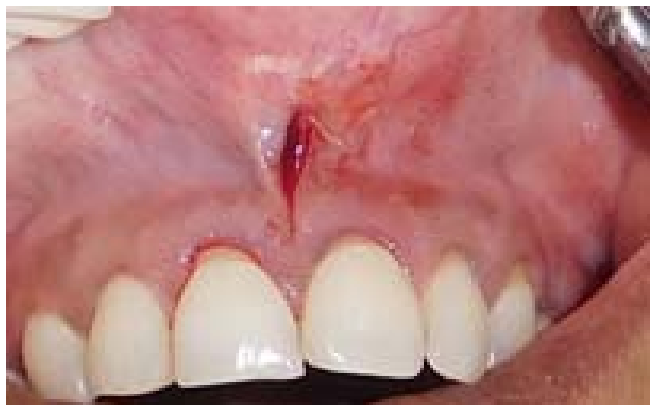

Fig 1: Case 2: Vertical incision

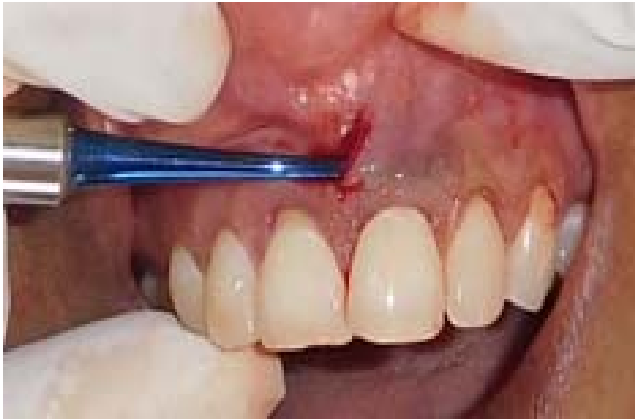

Fig 2: Case 2: Periosteal tunnel preparation

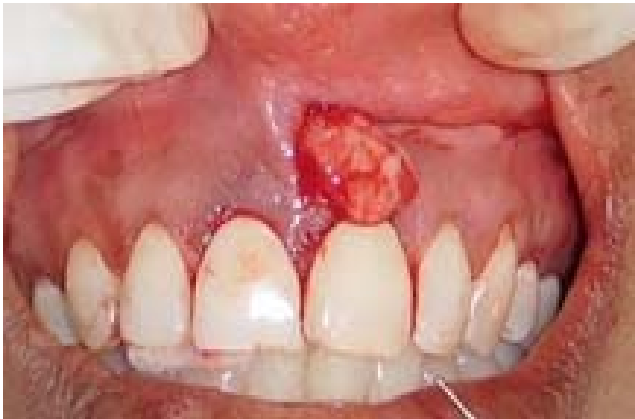

Fig 3: Case 2: Connective tissue graft inserted

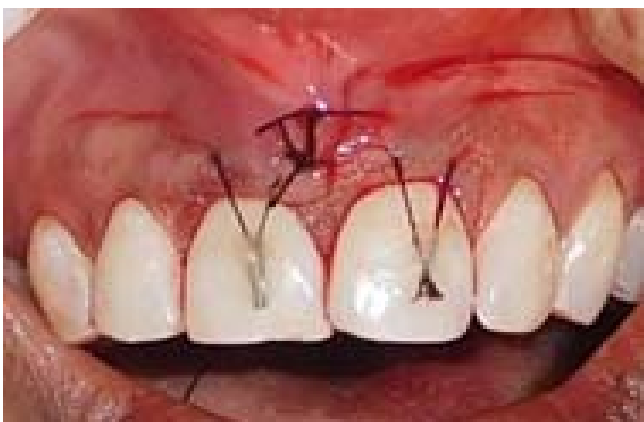

Fig 4: Case 2: Coronally anchored suture with composite stops

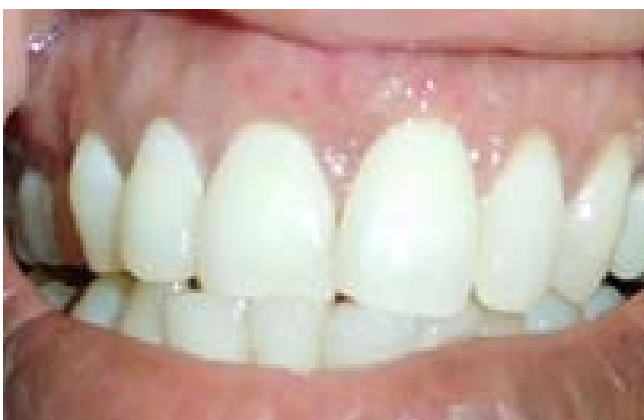

Fig 5: Case 2 Post-operative 6 month

5. Conclusion

Various treatment options exist for the treatment of gingival recession however treatment of multiple gingival recession is always a greater challenge compared to single recession defects. Hence, VISTA technique used in our study is aimed at overcoming the shortcoming of other treatment options and gives better results. However, further studies with large sample size and longer duration are advised to determine the success and predictability of this technique

6. References

1. Chambrone L, Sukekava F, Araujo MG, Pustiglioni FE, Chambrone LA, Lima LA. Root coverage procedures for the treatment of localised recession-type defects. *Cochrane Database Syst Rev.* 2009; (2):CD007161.
2. Dersot JM, Moubarak N. Design making in root coverage surgical techniques. *Dent News.* 2005; 1:8-12.
3. American academy of periodontology. position paper: epidemiology of periodontal diseases. *J periodontol.* 1996; 67:935-945.
4. Zadeh HH. Minimally invasive treatment of maxillary anterior gingival recession defects by vestibular incision subperiosteal tunnel access and platelet-derived growth factor BB. *Int J Periodontics Restorative Dent.* 2011; 31:653-660
5. Jankovic S, Klokkevold P, Dimitrijevic B, Kenney EB, Camargo P. Use of platelet rich fibrin membrane following treatment of gingival recession: a randomized control clinical trial. *Int J Periodontics Restorative Dent.* 2012; 32:e41-e50.
6. Dohan Ehrenfest DM. How to optimize the preparation of leukocyte- and platelet-rich fibrin (LPRF, Choukroun's technique) clots and membranes: Introducing the PRF Box. *Oral Surg Oral Med Oral Pathol Oral Radiol Endod.* 2010; 110:275-278.
7. Choukroun J, Diss A, Simonpieri A. Platelet-rich fibrin (PRF): A second-generation platelet concentrate, Part IV: Clinical effects on tissue healing. *Oral Surg Oral Med Oral Pathol Oral Radiol Endod.* 2006; 101:e56-60.
8. Oates TW, Robinson M, Gunsolley JC. Surgical therapies for the treatment of gingival recession. A systematic review. *Ann periodontol.* 2003; 8:303-20
9. Anilkumar K. platelet-rich-fibrin: A novel root coverage approach: case report *JISP.* 2009; 13:50-54.
10. Anitua E, Sanchez M, Orive G, Andia I. The potential impact of the preparation rich in growth factors (PRGF) in different medical fields. *Biomaterials.* 2007; 28:4551-60.
11. Reddy S, Prasad MJS, Agnihotri J, Amudha D, Singh S, Krishnanand P. Management of multiple recession defect using modified coronally advanced flap alone or with PRF. *Int J Health Sci Res.* 2013; 3:133-138.
12. Aroca S, Keglevich T, Barbieri B, Gera I, Etienne D. Clinical evaluation of a modified coronally advanced flap alone or in combination with a platelet-rich fibrin membrane for the treatment of adjacent multiple gingival recessions: a 6-month study. *J Periodontol.* 2009; 80:244-252.
13. Anirban Chatterjee, Ena Sharma, Gayatri Gundanavar, Shobha Krishna Subbaiah. Treatment of multiple gingival recessions with vista technique: A case series. *J Indian Soc Periodontol.* 2015; 19:232-5.