



ISSN Print: 2394-7489  
ISSN Online: 2394-7497  
IJADS 2017; 3(1): 1-4  
© 2017 IJADS  
www.oraljournal.com  
Received: 14-11-2016  
Accepted: 23-12-2016

**Dr. Inderpreet Singh Oberoi**  
PG scholar, Department of Oral  
Medicine and Radiology,  
Government Dental College and  
Hospital, Srinagar, Jammu and  
Kashmir, India

**Dr. Altaf Hussain Chalkoo**  
Professor and HOD, Department  
of Oral Medicine and Radiology,  
Government Dental College and  
Hospital, Srinagar, Jammu and  
Kashmir, India

**Dr Kuku Dhingra**  
Bds, Tutor, Dasmesh Dental  
College, Faridkot, Punjab, India

**Correspondence**

**Dr. Inderpreet Singh Oberoi**  
PG scholar, Department of Oral  
Medicine and Radiology,  
Government Dental College and  
Hospital, Srinagar, Jammu and  
Kashmir, India

## Evaluation of rugae pattern in individuals of a known population: A population based study

**Dr. Inderpreet Singh Oberoi, Dr. Altaf Hussain Chalkoo and Dr Kuku Dhingra**

### Abstract

**Background:** Palatal rugae analysis may serve as an important aid in forensic odontology as they remain consistent in shape, pattern, direction & unification throughout the life of an individual except change in their size with growth of the palate.

**Materials & methods:** Total of 120 subjects, 60 males and 60 females in the age group of 17 – 25 years of student population belonging to Jammu and Kashmir were chosen randomly and included in the present study. This study was conducted after obtaining institutional ethical committee clearance and informed written consent from the subjects. The materials used were: Alginate powder, perforated metal maxillary impression tray, Mixing bowl, Spatula, Dental Stone and Water. The rugae seen as elevated impressions were marked on these casts using a black permanent marker pen. The rugae pattern was classified based on their length, shape, direction and unification. The recorded data was compiled and entered in a spreadsheet (Microsoft Excel) and then exported to data editor of SPSS Version.

**Results:** Mean palatal primary rugae was more in males ( $7.52 \pm 2.67$ ) than females ( $6.43 \pm 1.91$ ) and was statistically significant ( $P$ -value=0.011), whereas mean palatal secondary and tertiary rugae were more in females than males but the results were not statistically significant ( $P$ -value>0.05). Based on shape of palatal rugae both genders showed wavy type (males= $4.62 \pm 2.56$  and females= $4.52 \pm 2.18$ ) followed by straight, curved and circular type of distribution.

**Conclusion:** Straight and wavy variety are the most commonly seen rugae pattern in both males and females.

**Keywords:** Identification, Rugae

### Introduction

Human identification is of paramount importance and it is indeed challenging considering the fact that every individual has distinctive trait. This requires a combination of different procedures to individualize a person or an object. "Identity" is a set of physical characteristics, functional or psychic, normal or pathological, that define an individual [1]. In forensic medicine, the main methods of identifications used are the DNA test, retina, fingerprints and dental characteristics. DNA testing is the gold standard in forensic science but it is very costly and cannot be conducted for everybody. In many instances, one or all of these methods may not be totally effective or conclusive. Many criminal investigations and victims of aircraft accidents have been identified by their dentition. Thus the use of human palatal rugae has also been suggested as an alternative method of identification. Forensic odontology involves participation of a dental surgeon in assisting legal and criminal issues [2]. Rugae are not damaged from trauma due to their internal position in the oral cavity and are insulated from heat by tongue and buccal fat pads [3]. In one study, it was reported that no two palates are alike in their configuration and that the palatal print did not change [4]. In twins also, the studies indicated that the patterns may be similar but not identical.<sup>2</sup> Events contributing to changes in Rugae pattern [5,6]:

- Finger sucking in childhood
- Persistent pressure due to orthodontic treatment
- Local effect on lateral rugae after tooth extraction (mainly effects the lateral part of rugae)
- Changes in the lateral edge of the rugae with orthodontic tooth movement

Rugae were first described by Winslow in 1732.

The earliest illustration of Palatal rugae was probably by Santorini in 1775, wherein he put a drawing depicting 3 wavy lines crossing the midline of palate. The first palatal classification system was put forth by Gorla in 1911. The first suggestion for the use of palatal rugae as a method of personal identification was suggested by Harrison Allen in 1889<sup>[7]</sup>. The term "Palatal rugoscopy" was proposed in 1932, by a Spanish investigator named Trobo Hermosa<sup>[8]</sup>. Embryologically, Palatal rugae appears around the 3rd month of intrauterine life from the covering of connective tissue in the palatal process of maxillary bone. Once formed they may experience changes in their size due to growth of the palate, but its shape is generally maintained<sup>[5]</sup>.

### Relevance of Palatal Rugae in Forensic Odontology

Palatal rugae analysis may serve as an important aid in forensic odontology as they remain consistent in shape, pattern, direction & unification throughout the life of an individual except change in their size with growth of the palate. They are well protected from heat, chemicals & trauma due to their internal position. In a study conducted by Muthusubramanian *et al.*, it was found that among the subjects with third-degree pan-facial burns, 93 percent of the palatine rugae were normal. The authors observed no changes in the colour or surface anatomy of the palatine rugae in 77 percent of the human cadavers. They concluded that the palatine rugae could be used as a reference landmark during forensic identification of an individual<sup>[9]</sup>.

Keeping in view of the following literature, we planned the present study to provide an overview of palatal rugae classification, methods of rugae analysis, and a brief review on its application in forensic odontology & dentistry.

### Material and Methods

Total of 120 subjects, 60 males and 60 females in the age group of 17 – 25 years of student population belonging to Jammu and Kashmir were chosen randomly and included in the present study. This study was conducted after obtaining institutional ethical committee clearance and informed written consent from the subjects. Inclusion Criteria:

Subjects without braces, removable partial dentures, fixed partial dentures and Student population belonging to Jammu and Kashmir were included.

Exclusion Criteria:

Subjects with abnormalities of palate and lips like the cleft palate and left lip, subjects who were wearing partial dentures and braces were excluded.

The various steps involved in the sample study were as follows:

- Obtaining consent from the subjects, Preparation of maxillary dental casts.
- Interpretation of the rugae pattern in the casts obtained by Thomas & Kotze classification<sup>[5]</sup>
- Subjects, both male and female, in the age group 17-25 years of student population and who belonged to Jammu and Kashmir were chosen randomly.

### Collection of the Palatal Prints

The materials used were: Alginate powder, perforated metal maxillary impression tray, Mixing bowl, Spatula, Dental Stone and Water. The rugae seen as elevated impressions were marked on these casts using a black permanent marker pen.

The rugae pattern was classified based on their length, shape, direction and unification. The parameters assessed were:

- 1) Total number of rugae
- 2) Number of primary rugae
- 3) Predominant Shape
- 4) Predominant Direction
- 5) Unification of rugae.

### The rugae were classified based on their length as

- 1) Primary->5mm,
- 2) Secondary- 3mm to 5mm
- 3) Fragmentary-<3mm

Rugae less than 2 mm were disregarded. A rugae's length was determined by measuring its greatest dimension regardless of its shape. The rugae were divided into 4 types based on their shape as:

- 1) Curved: They had a crescent shape and curved gently.
- 2) Wavy: If there was a slight curve at the origin or termination of a curved rugae.
- 3) Straight: They run directly from their origin to termination.
- 4) Circular: Rugae that form a definite continuous ring were classified as circular.

The direction of the rugae was determined by measuring the angle formed by the line joining its origin and termination and the line perpendicular to the median raphe. Based on the direction rugae were classified as:

- 1) Forwardly directed rugae – associated with positive angles
- 2) Backwardly directed rugae - associated with negative angles
- 3) Perpendicular rugae – associated with zero angles.

Unification was said to have occurred when two rugae joined at their origin or termination:

- 1) Diverging- If two rugae had the same origin from the midline but immediately branched.
- 2) Converging- Rugae with different origins from midline, but which joined on their lateral portions.

The recorded data was compiled and entered in a spreadsheet (Microsoft Excel) and then exported to data editor of SPSS Version 16.0 (SPSS Inc., Chicago, Illinois, USA). Continuous variables were summarized as Mean±SD and categorical variables as percentages. Student's Independent t-test was employed for comparison of parametric data and Chi-square test was used for comparison of categorical variables. Graphically the data was presented by bar diagrams. A P-value of less than 0.05 was considered statistically significant. All P-values were two tailed.

### Results

The total number of palatal rugae in the study sample was 1414 (691 in males and 723 in females). Mean palatal primary rugae was more in males (7.52±2.67) than females (6.43±1.91) and was statistically significant (P-value=0.011), whereas mean palatal secondary and tertiary rugae were more in females than males but the results were not statistically significant (P-value>0.05). Based on shape of palatal rugae both genders showed wavy type (males=4.62±2.56 and females=4.52±2.18) followed by straight, curved and circular type of distribution. However, the differences were statistically insignificant (P-value>0.05). Gender-wise distribution of mode of unification of the rugae showed predominant converging pattern (56.7%) in males and diverging pattern (63.3%) among females with a p-value of 0.028, which shows that difference is statistically significant.

**Table 1:** Mean distribution of study sample based on the number and shape of palatal rugae according to gender

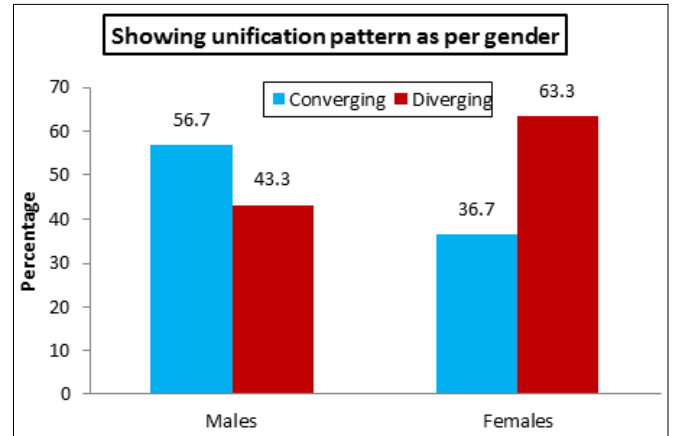
		Males [n=60]		Females [n=60]		P-value
		Mean	SD	Mean	SD	
Number	Primary	7.52	2.67	6.43	1.91	0.011*
	Secondary	2.40	2.78	3.20	2.56	0.104
	Tertiary	1.60	2.72	2.42	2.83	0.108
Shape	Straight	3.72	2.49	3.63	2.35	0.839
	Wavy	4.62	2.56	4.52	2.18	0.818
	Curved	1.43	2.37	1.40	1.79	0.937
	Circular	1.75	2.84	2.50	2.75	0.144

\*Statistically Significant Difference (P-value<0.05)

**Table 2:** Showing unification pattern as per gender

Unification Pattern	Males [n=60]		Females [n=60]		P-value
	No.	%age	No.	%age	
Converging	34	56.7	22	36.7	0.028*
Diverging	26	43.3	38	63.3	
Total	60	100	60	100	

\*Statistically Significant Difference (P-value<0.05)

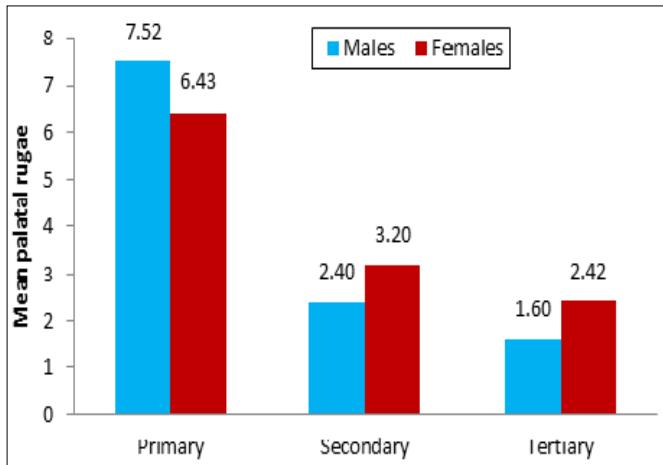


**Graph 3:** Percentage of palatal rugae pattern in between males and females

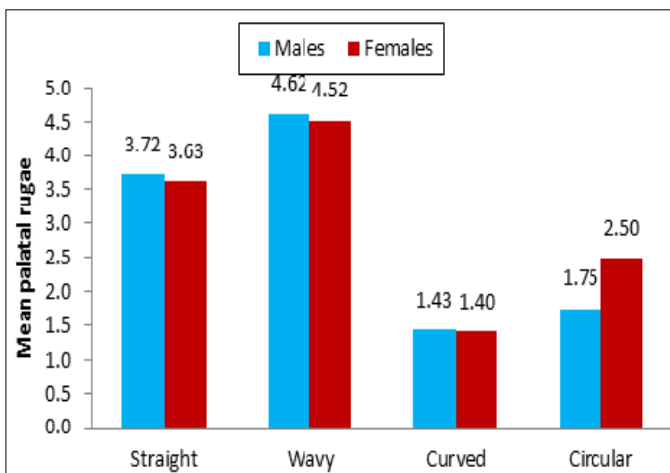
**Discussion**

According to glossary of prosthodontic terms, palatal rugae is defined as an anatomical fold or wrinkle usually made in the plural sense; the irregular fibrous connective tissue ridges located in the anterior third of the hard palate. It is also known as plica palatinae. Palatal rugae appear in the 3rd month of intra-uterine life. Due to its anatomic position, rugae are protected from thermal insults by the tongue and buccal pad of fat. Rugoscopy involves the study of palatal rugae pattern for human identification. Due to the stability and uniqueness of the palatal rugae pattern, it has been considered as one of the relevant parameters for human identification in the field of forensic medicine. Palatal rugoscopy was first proposed by Trobo Hermosa in 1932<sup>[10]</sup>. Hence; we planned the present study to provide an overview of palatal rugae classification, methods of rugae analysis, and a brief review on its application in forensic odontology & dentistry.

In the present study, we observed that straight and wavy pattern of palatal rugae pattern were the most common rugae pattern encountered among males and females. Thabitha *et al.* analyze the role of palatal rugoscopy in personal identification and sex determination of Nalgonda pediatric population. The study group consisted of 100 children having mixed dentition within the age range of 8–11 years, residing in Nalgonda district. Palatal rugae pattern, shape of the incisive papillae, length of the median palatal raphae, and shape of the dental arches were analyzed using Chi-square and Mann-Whitney tests between males and females. Wavy and curved patterns appeared to be most prevalent in both males and females but with no significant difference. The number of primary rugae in females and secondary rugae in males, on left side of the palate, was significantly more than their counterparts (P < 0.05). When rugae unification was observed, diverging type was significantly more in males than in females. Parabolic dental arch form, elliptical type of incisive papilla, and medium length of median palatal raphae was observed in majority of the subjects. Their study hypothesized the uniqueness of the rugae in personal identification as no two palates showed similar type of rugae in either of the genders. The rugae pattern also contributes minimally towards sex determination as there was no significant difference observed between the two variables.<sup>10</sup> Sekhon *et al.* recorded the biometric characteristics of shape, size, direction, number and position of palatal rugae and analyze whether palatal rugoscopy can be used as a tool for personal identification and for sex determination. The sample consisted of 100 subjects (50 males, 50 females) between 18 and 25 years. Maxillary impressions were made with elastomeric impression material



**Graph 1:** Distribution of palatal rugae pattern in between males and females



**Graph 2:** Distribution of pattern of palatal rugae pattern in between study population

and dental stone was used to make models. The palatal rugae patterns were traced and analyzed with a magnifying hand lens. The biometric characteristics of number, size, shape, and direction were analyzed using Thomaz and Kotz classification (1983). The casts were coded to blind the examiners about the identity of the subjects. The average number of rugae was slightly more in females. Wavy (44.9%) and curved (41.8%) shapes were more prevalent. Maximum number of rugae was found in E quadrant (40.73%). The average size was 9.221 mm. Most rugae were forwardly directed in both groups. They concluded that rugae pattern are highly individualistic and can be used as a supplementary method for personal identification and sex determination. Further inter-observer and intra-observer variability were not found to be significant, which further validates the use of rugoscopy as a forensic tool.<sup>11</sup>

### Conclusion

From the above results, it can be concluded that straight and wavy variety are the most commonly seen rugae pattern in both males and females. Future studies are recommended.

### References

1. Gopichand PV, Kaushal S, Kaur G. Personal identification using lip prints (Cheiloscopy) - A study in 500 Punjabi females. *J Indo Pac Acad Forensic Odontol.* 2010; 1:20-2.
2. Fahmi FM, Al-Shamrani SM, Talic YF. Rugae pattern in a Saudi population sample of males and females. *Saudi Dent J.* 2001; 13:92-5.
3. Indira AP, Manish Gupta, Maria Priscilla David: Rugoscopy for Establishing Individuality. *Indian Journal of Dental Advancements. IJDA.* 2011; 3:427-32.
4. Van der Linden FPGM. Changes in the position of posterior teeth in relation to ruga points. *Am J Orthod.* 1978; 74:142-61.
5. Hermosilla VV, San Pedro VJ, Cantín IM, Suazo GIC. Palatal rugae: systematic analysis of its shape and dimensions for use in human identification. *Int. J. Morphol.* 2009; 27:819-25.
6. Hauser G, Daponte A, Roberts MJ. Palatal rugae. *J Anat.* 1989; 165:237-49.
7. Sanjaya PR, Gokul S, Prithviraj KJ, Rajendra S. Significance of Palatal rugae: A Review. *Int J Dent Update.* 2012; 2:74-82.
8. Bansode S, Kulkarni M. Importance of palatal rugae in individual identification. *J Forensic Dent Scie.* 2009; 1:77-81.
9. Muthusubramanian M, Limson KS, Julian RJ. Analysis of rugae in burn victims and cadavers to simulate rugae identification in cases of incineration and decomposition. *J Forensic Odontostomatol.* 2005; 23:26-9.
10. Thabitha RS, Reddy RE, Manjula M, Sreelakshmi N, Rajesh A, Kumar VL. Evaluation of palatal rugae pattern in establishing identification and sex determination in Nalgonda children. *Journal of Forensic Dental Sciences.* 2015; 7(3):232-237.
11. Sekhon HK1, Sircar K, Singh S, Jawa D, Sharma P. Determination of the biometric characteristics of palatine rugae patterns in Uttar Pradesh population: a cross-sectional study. *Indian J Dent Res.* 2014; 25(3):331-5.