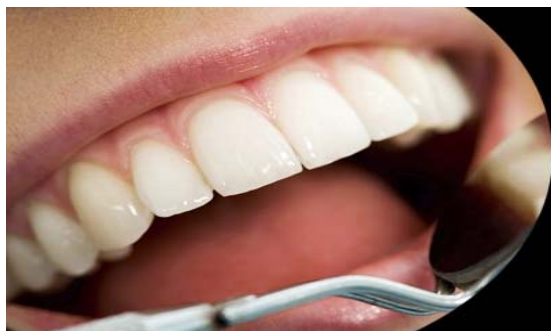



ISSN Print: 2394-7489
ISSN Online: 2394-7497
IJADS 2017; 3(1): 98-100
© 2017 IJADS
www.oraljournal.com
Received: 19-11-2016
Accepted: 20-12-2016

Dr. Malik Sartaj
Post Graduate Scholar,
Department of Conservative
Dentistry and Endodontics,
Srinagar, Jammu and Kashmir,
India

Ankush Sangra
Post Graduate Scholar,
Department of Conservative
Dentistry and Endodontics,
Srinagar, Jammu and Kashmir,
India

Riyaz Farooq
Professor/Principal Dean, Govt
Dental College Srinagar,
Srinagar, Jammu and Kashmir,
India

Aamir Rashid
Associate Professor, Department
of Conservative Dentistry and
Endodontics, Srinagar, Jammu
and Kashmir, India

Fayaz Ahmad
Assistant Professor, Department
of Conservative Dentistry and
Endodontics, Srinagar, Jammu
and Kashmir, India

Correspondence
Dr. Malik Sartaj
Post Graduate Scholar,
Department of Conservative
Dentistry and Endodontics,
Srinagar, Jammu and Kashmir,
India

C-Shaped configuration of the root canal system of mandibular second molar: A case report

Malik Sartaj, Ankushsangra, Riyaz Farooq, Aamir Rashid and Fayaz Ahmad

Abstract

The successful endodontic management needs proper knowledge about aberrant root canal systems. Appropriate mode can be selected depending upon this morphology. The C shaped canal is a special feature of some lower second molars. Some or all of the canal orifices are joined in the form of a groove or isthmus with a shape of the letter C. Biomechanical preparation and obturation of C- shaped canals needs variation from the usual endodontic techniques.

Keywords: Morphology, Biomechanical, endodontic

Introduction

Thorough knowledge on root canal anatomy and its variations is a key factor for successful root canal treatment. One of the most important anatomic variations is the 'C' configuration of the canal system. A great deal of variations can present, especially in the canal configuration of the mandibular second molar. Mandibular second molars usually have two roots and three root canals but variations in the number of roots as well as canal morphology are not uncommon. The mandibular second molars with C-shaped root canals vary in their configurations and many methods have been used to classify such canals. The C-shaped canal, which was first reported by Cooke and Cox in 1979.¹ The definition of the C-shaped root canal system is that the morphology of its horizontal cross section is in the form of a C, with canals which may or may not be separate^[2]. Although it is most frequently found in mandibular second molars with percentage ranging between 2.7%-45.5%.^[3, 4, 5, 6] this root canal configuration may occur in any molar area such as the mandibular first molar, first premolar and maxillary molars.^[7, 8, 9] It has been found that there is no correlation of C-shaped canal configuration with gender and also with age and tooth position but ethnic variation is found with highest frequency being reported in the East Asian population groups like Chinese population (29.7%) and Koreans (31.3%-45.5%)^[1]. This C- shaped canal is an anatomical variation of a root fusion and a type of taurodontism. This results from the failure of Hertwig's epithelial sheath to develop or fuse in the furcation area in the developing stage of the teeth^[10]. Fan *et al.*, modified Melton's method into the following categories:

1. Category I (C1): interrupted "C" with no separation or division [Figure 1a].
2. Category II (C2): resembled a semicolon resulting from a discontinuation of the "C" outline [Figure 1b], but either angle α or β [Figure 2] should be no less than 60°.
3. Category III (C3): 2 or 3 separate canals [Figure 1c and d] and both angles, α and β , less Than 60°.
4. Category IV (C4): Only one round or oval canal in the cross- section [Figure 1e].
5. Category V (C5): No canal lumen could be observed (which is usually seen near the apex only) [Figure 1f].

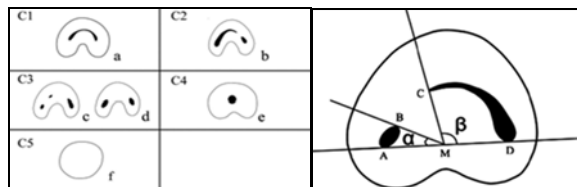


Fig 1

Fig 2

Four types of pulp floors were found in mandibular second molars in relation to c shaped canals [11].

- Type 1. Peninsula like floor with continuous C shaped orifice
- Type 2. Here abuccal strip of dentin separate C shaped groove into mesial and distal orifice
- Type 3. Mesial strip of dentin separate shaped groove into small ML and large MD-D orifice.
- Type 4. Non C shaped floors.

Gao Y *et al.* [12] gave a three dimensional classification of c shaped canal configurations as:

- Type I. merging type canal merge into one main canal
- Type II. Symmetrical type separate mesial and distal canals
- Type III. Separate mesial and distal canals with distal canal having long isthmus across furcation area.

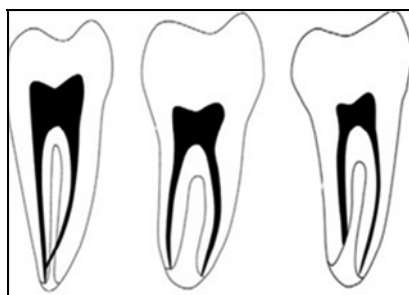


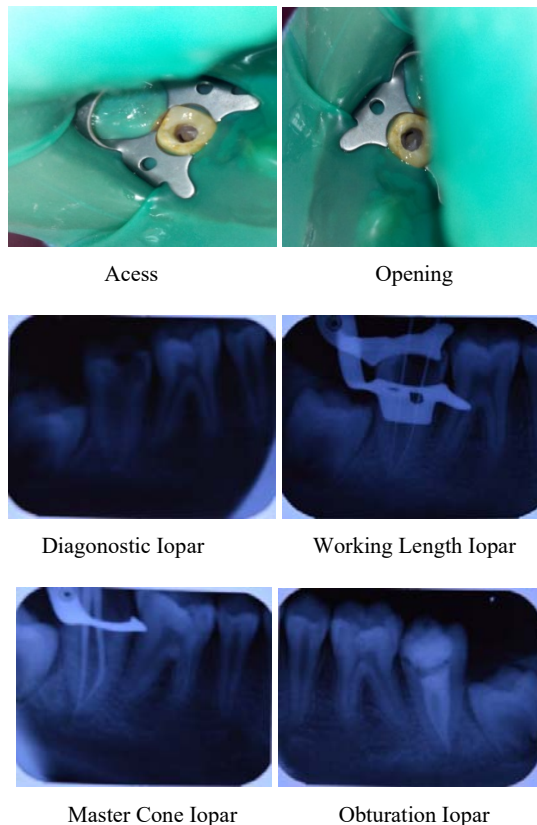
Fig 3

Recent studies done on mandibular molars with C- shaped roots, NiTi rotary instrumentation was associated with a higher percentage (59.6%) of uninstrumented canal areas than the manual K- file group (41.6%) with more dentine removed from the convex aspect of the C- shaped canal [13]. The C- shaped canal system thus represents a challenge to its proper debridement and obturation. This paper describes successful management of two unusual cases of C- shaped canal.

Case report

A 36- year- old male patient reported to Department of Conservative Dentistry and Endodontics with a complaint of pain of his lower left back tooth. There was no associated history of swelling or pus discharge. Clinically, there was a presence of deep disto-occlusal carious lesion approaching pulp. Radiograph shows presence of periapical radiolucency with respect to 47. Cold test using ice pencil and EPT gave negative response. The medical history was non-contributory. The presence of conical shaped root outline and radiolucent line in middle of the roots suggested C- shaped root canal morphology. So we make diagnoses of necrotic tooth with acute apical periodontitis with respect to tooth 47 with C shaped canals. Endodontic treatment was planned and explained to the patient. After rubber dam isolation and profound anesthesia, an access cavity was prepared. On exploration of pulp chamber, two orifices were recognized, which were then negotiated till apex with the use of multiple

small K files with the help of RC- Prep (Am Dent) and 5%NaOCl. After working length determination by using electronic apex locator (Root ZX mini, J. Morita), it was confirmed with a radiograph. A No. # 20 Hedstrom file was directed into the mesial corner and a No. # 20 K- file was placed into the distal aspect of the canal in order to determine the apical extension and possible bifurcation of the C-shaped canal. The root canals were enlarged using H files with 5 % sodium hypochlorite as the irrigating solution. EndoActivator with # 30 tip was used to flush wide canals and ultrasonic tip was used to enlarge and flare the canals. The final shaping of the canals was achieved with hand instruments. Calcium hydroxide (RC- Cal, India), an intra-canal medicament was used and the patient was recalled after two week. In the next appointment, Master cone was fitted to the working length and radiograph was taken and the canal was obturated with selected master gutta- percha cone along with accessory cones with AH- Plus endodontic sealer (Dentsply Maillefer Company, USA). To ensure proper placement of the master cones within the C-shaped canal, a large diameter spreader was placed into the most distal portion of the canal. The spreader was removed without dislodging the mesial master cone and the distal master cone was inserted. Obturation of canal was done by warm lateral condensation technique. A heated tip (Touch N Heat, API Instruments) is introduced into a tooth already obturated by lateral condensation to soften the gutta-percha mass and enhance adaptation to the internal anatomy of the canal. This technique is useful to increase the adaptation and density of teeth obturated with lateral condensation, it is especially indicated for C-shaped canals.



Discussion

Clinical cases of a C shaped pulp chamber and root canal

system shows that this root canal aberration occurs in a wide variety and variability with a single root canal up to two, three and four separate root canals. The diameter of the root canal themselves also varies from very wide to such with a small diameter. The teeth that qualified as having a C- shaped canal system had to exhibit all the following three features: Fused roots, a longitudinal groove on the lingual or buccal surfaces of the root, and at least one cross- section of the canal belongs to the C1, C2, or C3 configuration ^[14, 15]. Clinical recognition of C- shaped canals is based on the definite observable criteria (i.e., the anatomy of the floor of the pulp chamber and the persistence of haemorrhage or pain when separate canal orifices were found ^[16]. CBCT may be used as an adjunct in diagnoses and treatment planning of C shaped canals ^[17]. In our case report, initial evaluation of the radiograph suggested the presence of single root with two wide canals which are centrally located. suggesting type I C- shaped configuration of the canal. After access preparation, two canal orifices joined by were negotiated, which showed presence of a single root canal in middle and apical thirds. The morphological variant of single root and single canal is easily detected in routine radiographs. Regarding the filling of root canal system one method is not enough to seal the endodontic space. Thermo plasticized gutta- percha technique is the recommended technique for such cases. But since most of dental practitioners use only lateral condensation technique, we used warm lateral compaction for obturation of root canals with good results.

Conclusion

The proper diagnosis plays a key role for the management of C- shaped canals. Depending upon the morphology the management mode can be selected. Due to the unusual anatomy of teeth with C-shaped root canal system, successful cleaning and shaping followed by three dimensional sealing of aberrant space, it's necessary to know and learn appropriate techniques of irrigation and filling with suitable techniques.

References

1. Fernandes M, de Ataide I, Wagle R. C-shaped root canal configuration: A review of literature. *J Conserv Dent* 2014; 17:312-9
2. Vieira MVB, Vieira MM, Pileggi R. "C-shaped canal": an anatomical variation. *RBO*. 1998; 55(4):204-08.
3. Manning SA. Root canal anatomy of mandibular second molars. Part I: *Int Endod J*. 1990; 23:34-9.
4. Fan B, Cheung GS, Fan M, Gutmann JL, Bian Z. C-shaped canal second system in mandibular molars: Part I- Anatomical features. *J. of Endodon*, 2004; 30(12):899-903
5. Gulabivala K, Opananon A, Ng YL, Alavi A. Root and canal morphology of Thai mandibular molars. *IntEndod J* 2002; 35:56-62.
6. Jin GC, Lee SJ, Roh BD. Anatomical study of C-shaped canals in mandibular second molars by analysis of computed tomography. *J Endod* 2006; 32:10-3.
7. Chai WL, Thong YL. Cross sectional morphology and minimum canal wall widths in C-shaped roots of mandibular molars. *J. of Endod*. 2004; 30(7):509-12.
8. Fan B, Ye W, Xie E, Wu H, Gutmann JL. Three-dimensional morphological analysis of C-shaped canals in mandibular first premolars in a Chinese population. *Int Endod J*. 2012; 45:1035-41.
9. Sikri VK, Sikri P. Mandibular premolars: aberrations in pulp space morphology. *Indian J. Dent. Res.* 1994; 5(1):9-14.
10. Kadam NS, Ataide IN. Management of C-shaped canals Two case reports. *J Orofac Sci*. 2013; 5:37-41.
11. Min Y, Fan B, Cheung GS, Gutmann JL, Fan M. C-shaped canal system in mandibular second molars Part III: The morphology of the pulp chamber floor. *J Endod*. 2006; 32:1155-9.
12. Gao Y, Fan B, Cheung GS, Gutmann JL, Fan M. C-shaped canal system in mandibular second molars part IV: 3-D morphological analysis and transverse measurement. *J Endod* 2006; 32:1062-5.
13. Cheung LH, Cheung GS. Evaluation of a rotary instrumentation method for C- shaped canals with microcomputed tomography. *J Endod* 2008; 34:1233-8.
14. Nie YK, Wan Bakar WZ, Alam MK. C-shaped root canal. *Dental Research Journal*. 2013; 10(1):132-133.
15. Kirilova J, Topalova-Pirinska S. C-shaped configuration of the root Canal system – problems and solutions *J of IMAB*. 2014; 20:1.
16. Zheng Q, Zhang L, Zhou X, Wang Q, Wang Y, Tang L, *et al*. C- shaped root canal system in mandibular second molars in a Chinese population evaluated by cone- beam computed tomography. *Int Endod J*. 2011; 44:857-62.
17. Deepak Raisingani, Shailendra Gupta, PrachiMital, PoorvaKhullar. Anatomic and Diagnostic Challenges of C-Shaped Root Canal System *Int J Clin Pediatr Dent*. 2014; 7(1):35-39.