



## International Journal of Applied Dental Sciences

ISSN Print: 2394-7489  
ISSN Online: 2394-7497  
IJADS 2018; 4(2): 33-35  
© 2018 IJADS  
www.oraljournal.com  
Received: 08-02-2018  
Accepted: 09-03-2018

**Muhammad Waqar Hussain**  
Assistant Professor,  
Department of Prosthetic  
Dentistry College of Dentistry,  
King Khalid University, Abha,  
Saudi Arabia

**Talib Amin Naqash**  
Assistant Professor,  
Department of Prosthetic  
Dentistry College of Dentistry,  
King Khalid University, Abha,  
Saudi Arabia

**Ayesha Nasser Al-Shahrani**  
Intern, College of Dentistry,  
King Khalid University, Abha,  
Saudi Arabia

**Asrar Mohammed Al-Manie**  
Intern, College of Dentistry,  
King Khalid University, Abha,  
Saudi Arabia

**Abrar Mohammed Al-Osbi**  
Intern, College of Dentistry,  
King Khalid University, Abha,  
Saudi Arabia

### Correspondence

**Muhammad Waqar Hussain**  
Assistant Professor,  
Department of Prosthetic  
Dentistry College of Dentistry,  
King Khalid University, Abha,  
Saudi Arabia

## Inter commissural width as a guide for selection of maxillary anterior teeth in Saudi female population

**Muhammad Waqar Hussain, Talib Amin Naqash, Ayesha Nasser Al-Shahrani, Asrar Mohammed Al-Manie and Abrar Mohammed Al-Osbi**

### Abstract

**Aim:** In situations with non-availability of pre extraction records, selection of artificial teeth for edentulous patients becomes difficult. Numerous guidelines have been proposed for determining the width of the maxillary anterior denture teeth. This study was undertaken to evaluate the use of inter commissural width as a guide for the selection maxillary anterior teeth in Saudi female population of Aseer region, KSA.

**Materials and Methods:** Ninety nine female Saudi subjects aged 18–35 were selected. Inter commissural width was measured directly on the participants of the study using digital caliper with precision of 0.01mm. Combined width of maxillary central incisors were measured indirectly on the cast with the help of dental floss and digital caliper.

**Results:** The mean values for inter commissural width and distance between the distal aspects of canines (combined width of maxillary anterior teeth) in females were 45.51mm and 49.81 mm. In addition, the correlation value between inter commissural width and the difference between inter commissural width and the distance between the distal surfaces of the canines in Saudi female participants was found to be statistically significant ( $r = 0.273$ ,  $p\text{-value} = 0.018$ ).

**Conclusion:** The findings of the study indicated that, to select the combined mesiodistal width of maxillary anterior teeth, inter commissural width of the required patient should be multiplied by 1.094.

**Keywords:** Inter commissural width, Inter canine distance, maxillary anterior teeth

### Introduction

The apprehensions of a completely edentulous patient are primarily related to comfort, function and esthetics. Failure to accomplish the esthetic appearance of an edentulous patient often results in the rejection of well-constructed, comfortable and efficient denture. For a completely edentulous patient, it is mandatory that the color, size and the form of the teeth must be in harmony with the surrounding facial environment<sup>[1-4]</sup>. All these objectives are difficult to achieve when pre extraction records of the natural teeth such as casts or photographs are not available<sup>[5]</sup>.

The selection of appropriate size of artificial teeth takes an important place in aesthetic designing of complete denture prosthesis<sup>[5]</sup>. The width of the teeth is considered by some to be more critical than the length<sup>[4]</sup>.

There are numerous studies penned down in the literature to identify normal tooth proportions<sup>[5, 6]</sup>. However, the standards or proportions commonly used as a guide have been developed mainly on Caucasian populations<sup>[5]</sup>.

The objective of this study was to investigate the relationship between inter commissural width in the selection of combined mesiodistal width of maxillary six anterior teeth in Saudi female population of Aseer region, KSA.

### Materials and Methodology

A total of 99 female dentate subjects were selected from Sameer Campus, King Khalid University, College of Dentistry, Abha; age ranged from 18-35. The selection criteria required the subjects to have all their natural anterior teeth except for possibly the third molars, no history of orthodontic treatment, no tooth size alteration, rotation, spacing, crowding and restoration. Subjects with a history of congenital anomaly, orbital disease, trauma, or facial

surgery were excluded from the study. The informed consent was taken from all the subjects for using their data in the research.

All the measurements were made using a digital caliper (Mitutoyo Ltd., UK) with precision of 0.01mm and measuring distances from 0 to 150mm. During the measurement the subjects were seated comfortably in an upright position and asked to look straight ahead.

Inter commissural distance was measured directly on the subjects of the study by single observer. Before the beginning of the measurement, the participants were required to widely open and close their mouth several times. This helped the fatigued musculature around the lips to relax during the measurement.

During measurement of inter commissural width, the mandible was in the rest position and the lips un-stretched. Then the lip vermilion was measured between left and right commissure of mouth using the digital caliper. Each measurement was recorded three times for accuracy and precision (Figure 1).

For measuring the combined width of maxillary anterior teeth the artificial stone casts of maxillary arches were made from irreversible hydrocolloid impressions in perforated stock trays. Dental floss was placed at the greatest curvature of the maxillary cast and was fixed with the adhesive tape. The marks were made on the distal surface of both the canines (Figure 2a, 2b). The dental floss was sectioned at the

markings, made straight. The distance between the marks was measured using digital caliper (Figure 3).

The data was analyzed in statistical software (SPSS version 11). Pearson’s correlation coefficient was used to find out the correlation between inter commissural width with combined width of maxillary anterior teeth. P-value < 0.05 was considered for significance.

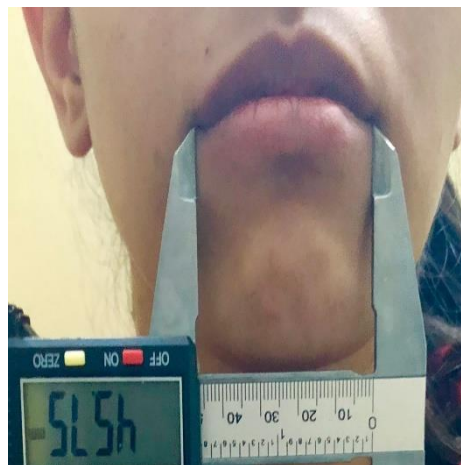


Fig 1: Measurement of inter commissural width with the help of digital caliper.

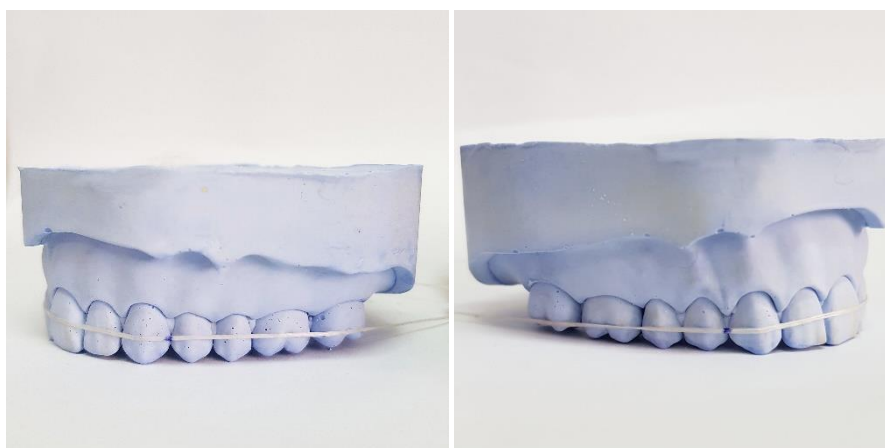

Fig 2: Markings made on the dental cast on the distal end of each canines at the greatest curvature.



Fig 3: The distance between the marks was measured using digital caliper.

**Results**

Measurements obtained from the 99 female participants were tabulated. Mean value of the age of participants is presented in Table 1. Mean values of combined width of maxillary anterior teeth and inter commissural distance are respectively presented in Table 2 and 3. Correlation of the difference of inter commissural distance and combined width of maxillary anterior teeth is depicted in Table 4.

Table 1: Mean value and standard deviation of the age of participants

	N	Minimum	Maximum	Mean	Standard Deviation
Age	99	18	36	24.17	4.56

Table 2: Mean and standard deviation values of combined width of maxillary anterior teeth

	N	Minimum	Maximum	Mean	Standard Deviation
Combined width of maxillary anterior teeth	99	40.47	56.51	49.81	2.95

**Table 3:** Mean and standard deviation values of inter commissural distance

	N	Minimum	Maximum	Mean	Standard Deviation
Inter commissural distance	99	36.40	52.75	45.51	2.99

**Table 4:** Correlation of the difference of inter commissural distance and combined width of maxillary anterior teeth

	Mean	Pearson correlation "r"	Significance (2 tailed) "p value"	Ratio
Combined width of maxillary anterior teeth	49.81	0.237	0.018	1:1.094
Inter commissural distance	45.51			

## Discussion

A perfect smile is an important part of facial esthetics; it should be always in proportion with the rest of face. The relationship between various facial measurements and natural teeth are penned down in the literature and can be used as a reliable guide to achieve acceptable esthetics.

Gomes et al. stated that the estimation of mesiodistal width of maxillary anterior teeth is one of the most difficult aspects in complete denture therapy. There are numerous studies in the literature that aim at estimating correlation between the combined mesiodistal width of maxillary anterior teeth with other facial measurements [8-11]. The present study evaluated the use of inter commissural width as a guide for the selection of combined width of maxillary anterior denture teeth in Saudi female population.

The mean values for inter commissural width and distance between the distal aspects of canines in females were 45.51mm and 49.81 mm. In addition, the correlation value between inter commissural distance and the difference between inter commissural width and the distance between the distal surfaces of the canines in Saudi female participants was found to be statistically highly significant ( $r = 0.273$ ,  $p$ -value = 0.018).

The ratios between mean inter commissural distance and combined width of maxillary anterior teeth measurements are given in Table 4. For the sample population the ratio was 1:1.094 for the combined width of maxillary anterior teeth and inter commissural distance. The results from the present study are in accordance with earlier studies conducted by Deogade SC [12], Kini AY [13] and Thalib B [14]

## Limitations

The study had the following limitations. Male participants need to be included in the study. Larger sample size need to be addressed in the future studies

## Conclusion

It was concluded that inter commissural width measurement is accurate for the selection of the maxillary anterior teeth for the completely edentulous patients in Saudi female population ( $p$  value less than 0.05). The results could be used as a helpful guide for initial selection of anterior teeth width in female Saudi population.

## References

1. Frush JP, Fisher RD. How dentogenic restorations interpret the sex factor. *J Prosthet Dent.* 1956; 6:160-72.
2. Young HA. Denture esthetics. *J Prosthet Dent.* 1956; 6:748-55.
3. Lombardi RE. The principles of visual perception and their clinical application to denture esthetics. *J Prosthet Dent.* 1973; 29:358-82.
4. Krajicek DD. Natural appearance for the individual denture patient. *J Prosthet Dent.* 1960; 10:205-14.
5. Shah SA, Naqash TA, Abdullah S, Bashir U, Gulzar S,

6. Bashir S. Significance of Intercanthal distance in the selection of width of maxillary anterior teeth size in Kashmiri Population: A Research. *Int J Health Sci Res.* 2015; 5(2):213-216.
7. Shillinberg HT, Kaplan MJ, Grace CS. Tooth dimensions- a comparative study. *J South Calif Dent Assoc.* 1972; 40:830- 9.
8. Gomes VL, Goncalves LC, Parado CJD, Junor IL. Correlation between facial measurements and the mesiodistal width of the maxillary anterior teeth. *J Esthet Restor Dent.* 2006; 18:196-205.
9. Alwazzan KA. The relationship between intercanthal dimensions and the widths of maxillary anterior teeth. *J Prosthet Dent.* 2001; 86(6):608-12.
10. Abdullah MA. Intercanthal distance and geometric progression as a predictor of maxillary central incisor width. *J Prosthet Dent.* 2002; 88:16-20
11. Abdullah MA, Stipho HD, Talic YF, Khan N. The significance of intercanthal distance in Prosthodontics. *Saudi Dent J.* 1997; 9:36-9.
12. Freihofer HP. Intercanthal and inter orbital distances. *J Maxillofac Surg.* 1980; 8(4):324-6.
13. Deogade SC, Mantri SS, Saxena S, Hemasha D. Correlation between combined width of maxillary anterior teeth, interpupillary distance and intercommissural width in a group of Indian people. *Int J Prosthodont Restor Dent.* 2014; 4(4):105-111.
14. Kini AY, Angadi GS. Biometric ratio in estimating widths of maxillary anterior teeth derived after correlating anthropometric measurements with dental measurements. *Gerodontology.* 2013; 30(2):105-11
15. Thalib B, Saputri A. Correlation between interalar width and inter commissural width against mesiodistal width of central upper incisors in buginese tribe. *J dentomaxillofac Sci.* 2016; 1(1):25-30.