



ISSN Print: 2394-7489
ISSN Online: 2394-7497
IJADS 2018; 4(2): 80-82
© 2018 IJADS
www.oraljournal.com
Received: 07-02-2018
Accepted: 11-03-2018

Dr. Shahid Farooq
Post Graduate Student, Dept. of
Oral and Maxillofacial Surgery,
GDC, Srinagar, Jammu and
Kashmir, India

Dr. Rizwan Hamid
Post Graduate Student, Dept. of
Oral Medicine and Radiology,
GDC, Srinagar, Jammu and
Kashmir, India

Dr. Gurvinder Kour
Junior Resident, Dept. of Oral
Medicine and Radiology, GDC,
Srinagar, Jammu and Kashmir,
India

Dr. Ajaz Shah
Prof. and Head, Dept. of Oral
and Maxillofacial Surgery, GDC,
Srinagar, Jammu and Kashmir,
India

Traumatic ulcerative granuloma with stromal eosinophilia: A clinical study

Dr. Shahid Farooq, Dr. Rizwan Hamid, Dr. Gurvinder Kour and Dr. Ajaz Shah

Abstract

Background: Oral ulcers are a common symptom in clinical practice. Among different types of ulcers in oral cavity, traumatic ulcerative granuloma with stromal eosinophilia (TUGSE) appears to be quite neglected by the clinicians due to the limited knowledge and awareness. Traumatic ulcerative granuloma with stromal eosinophilia (TUGSE) is a reactive benign and self-limiting lesion of the oral mucosa. It may mimic squamous cell carcinoma as well as other malignant lesion. The cause is unknown but a traumatic background has been suggested. Oral TUGSE shows regression after a conservative surgical treatment.

Objectives: To analyse the clinical features of 8 TUGSE lesions.

Materials and Methods: 8 cases of TUGSE were retrieved from the files of the Department of Oral medicine and radiology. Their clinical data and histopathological features were examined, collected, and analyzed.

Results: The reported cases included six males and two female patients. Age ranged from 9 to 81 years with mean age of 48 years. The most common site was the tongue followed by buccal mucosa. Clinically, the lesions showed chronic ulcers. The lesions were resolved after the biopsy. All patients were followed up for four months, no recurrence had been found.

Conclusion: Traumatic ulcerative granuloma with stromal eosinophilia (TUGSE) appears to be quite neglected by the clinicians due to the limited knowledge and awareness. It is important to recognise this mucosal entity as it has a close resemblance with malignancy of the oral cavity. Prognosis of TUGSE is normally favourable and aggressive surgical treatment is usually not required.

Keywords: clinical feature; oral cavity; traumatic ulcerative granuloma with stromal eosinophilia, chronic traumatic ulcer

Introduction

Traumatic ulcerative granuloma with stromal eosinophilia (TUGSE) is a rare, benign ulcerative lesion of the oral mucosa. Although the tongue is the most commonly location involved [1-3], oral TUGSE lesions can also occur on other oral mucosal sites including buccal mucosa, retromolar area, floor of the mouth, vestibular mucosa, gingiva, and palatal mucosa [1-4]. Clinically, an oral TUGSE lesion manifests as a slow-healing ulcer with an elevated or rolled border, mimicking a squamous cell carcinoma. The duration of healing ranges from 1 week to 1 year [2-4]. Delayed healing of TUGSE lesions has been reported to be associated with the lack of secretion of transforming growth factor (TGF)- α and TGF- β by eosinophils infiltrating the lesions [5]. The etiology of TUGSE is still not clear, but traumatic irritation is considered to be the most likely cause [1, 4]. Histologically, TUGSE is characterized as a lesion with surface ulceration and underlying granulomatous tissues showing an inflammatory infiltrate rich in eosinophils. The same histological manifestation in infants is called Riga Fede disease, in which the lesion usually occurs on the ventral surface of tongue and is caused by irritation of erupting mandibular incisors [3]. Oral TUGSE is generally considered to be a reactive lesion [4]. However, CD30+ cells and a monoclonal rearrangement of the T-cell receptor γ (TCR γ) chain gene similar to those found in primary cutaneous CD30+ lymphoproliferative disorders have been reported in part of TUGSE lesions [1, 4, 6-9]. Therefore, some authors even suspected that TUGSE may be the oral counterpart of primary cutaneous CD30+ lymphoproliferative disorder [6].

Correspondence

Dr. Shahid Farooq
Post Graduate Student, Dept. of
Oral and Maxillofacial Surgery,
GDC, Srinagar, Jammu and
Kashmir, India

Materials and Methods: 8 cases of TUGSE were retrieved from the files of the Department of Oral medicine and radiology. Demographic data, including the sex and age of patients as well as the location, clinical diagnosis, symptoms and signs, treatment, and recurrence of the lesions were obtained by reviewing the dental and medical charts.

Results

The reported cases included six males and two female patients (Fig. 1).

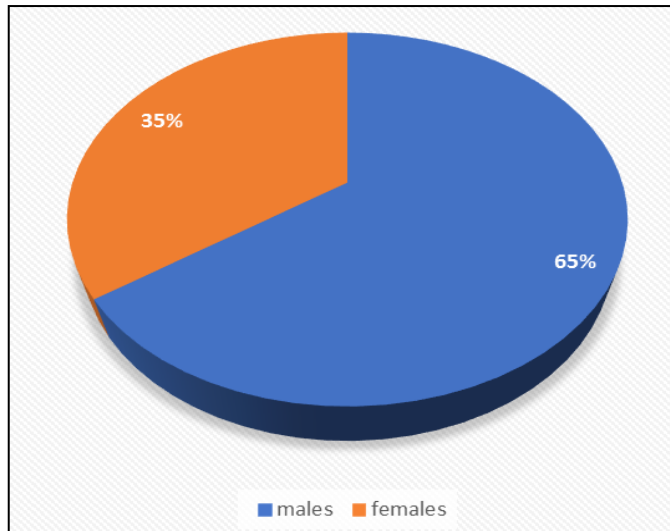


Fig 1: Gender distribution

Age ranged from 9 to 81 years with mean age of 48 years, with the highest incidence being in the fifth and sixth decades. After reviewing the medical and dental charts, we found that pain was the general symptom and oral ulceration was the universal sign for all oral TUGSE lesions. The most common site was the tongue followed by buccal mucosa. Oral TUGSE lesions were correctly diagnosed in only 4 cases. Marginal induration was palpable in 4 cases (32.4%), and thus the initial clinical diagnosis was “rule out cancer” for these 4 cases. The remaining 4 cases were diagnosed as traumatic ulcer or nonspecific chronic ulcer. Moreover, none of these 8 patients had concomitant cutaneous lesions or developed lymphomas. The lesions were resolved after the biopsy. All patients were followed up for four months, no recurrence had been found.

Discussion

Although the true etiology for oral TUGSE lesion is still unknown, the most possible etiology is traumatic irritation. Sharp tooth margins, ill-fitting dentures, and incisional biopsy for oral leukoplakia have been found as possible causes.¹⁻⁴ Only one case developed TUGSE lesions after wide surgical excision of their primary oral squamous cell carcinomas, and were suspected as recurrent cancers clinically. However, most reported TUGSE lesions are deficient of obvious clinical causes to confirm the traumatic origin of the lesion. The dysfunction of the immune system may be taken into consideration. A previous study showed a lack of TGF- α and TGF- β production in eosinophils infiltrating in oral TUGSE lesions⁵ and this may be why oral TUGSE lesions have a prolonged healing process and are often suspected as malignant lesions⁵. In addition to oral squamous cell carcinomas, clinical differential diagnoses of TUGSE lesions may include deep fungal infections, necrotizing bacterial

infections, syphilis, and granulomatous disorders due to the slow-healing process and the presence of elevated or rolled border of TUGSE lesions^{1, 4, 8} However, oral TUGSE is a self-limiting lesion, and aggressive surgical treatment is usually not required. Moreover, healing of the lesion is usually uneventful after incisional or conservative excisional biopsy of the lesion¹⁻³ A soft diet and application of corticosteroid or nonsteroidal anti-inflammatory drug ointments are suggested for patients with oral TUGSE to reduce the uncomfortable feelings caused by the lesion. The most common location for oral TUGSE lesions is the tongue¹⁻³, which was also seen in this study. In addition, the second common location for TUGSE lesions is the buccal mucosa. The high frequency of occurrence of TUGSE lesions on the tongue and buccal mucosa is because the tongue and buccal mucosa are more susceptible to injury by teeth during occlusion or chewing than other oral mucosal sites. The finding that oral TUGSE lesions occurring on the tongue and buccal mucosa also suggests the possible traumatic etiology of oral TUGSE lesions. There was a male predilection for this study, with the male to female ratio of 3:1, which was not comparable to the male to female ratio of 1.38:1 reported by Fonseca *et al.*², which could be due to small sample size in our study. In the series by Elzay *et al.* of 41 patients with TUGSE (the sex is unknown in one patient), there is an equal number of male and female patients (n =20)³. However, in the series by Salisbury *et al.* of 37 patients with TUGSE, a female predilection with the male to female ratio of 1:1.85 is found¹. Fonseca *et al.*² demonstrated no predilection of eosinophils for the muscle fibers surrounding the TUGSE lesion. CD30 is a transmembrane protein of the tumor necrosis factor (TNF) family. CD30 positivity is found in various lesions ranging from reactive conditions to T- or B-cell lymphomas^{6, 8-12} However, strong and homogeneous CD30 expression in most neoplastic cells is restricted to classic Hodgkin lymphoma, anaplastic large cell lymphomas, and primary cutaneous CD30+ T-cell lymphoproliferative disorders⁹ CD30+ cells are also observed in a part of reported TUGSE lesions. Scattered or clustered infiltrates of CD30+ cells were found in 5 of 12 (42%), 11 of 19 (58%), and 26 of 37 TUGSE lesions (70%) reported by Hirshberg *et al.*,⁴ Fonseca *et al.*,² and Salisbury *et al.*,¹ respectively. These CD30+ cells in TUGSE lesions include large mononuclear cells and small reactive T cells.² Using immunohistochemistry for CD30 protein and polymerase chain reaction (PCR) analysis for the TCR γ chain gene, some atypical TUGSE lesions were found to have CD30+ cells and a monoclonal rearrangement of the TCR γ chain gene.^{1,4,6} However, negative expression of anaplastic lymphoma kinase protein, a marker associated with large cell CD30+ lymphoma, supports the reactive nature of TUGSE lesion⁴ Alobeid *et al.*⁶ even found the same pattern of monoclonal rearrangement of the TCR γ chain gene in specimens of both oral and cutaneous eosinophilic ulcers of the same patient. They thought that TUGSE lesions seem to be the oral counterpart of primary cutaneous CD30+ lymphoproliferative disorders. The large mononuclear cells in TUGSE lesions exhibit irregular nuclear contour, fine chromatin, and abundant cytoplasm⁴. They are suspected of heterogeneous origins. As mentioned before, large mononuclear cells have been found to be positive for CD30,² B-cell marker CD20,⁷ T-cell marker CD3,^{8, 10} macrophage marker CD68,¹¹ or Langerhans cell marker CD1a.¹² Moreover, Abdel-Naser *et al.*¹⁰ also discovered the expression of Epstein-Barr virus (EBV) encoded latent membrane protein 1 in CD3-positive

large mononuclear cells. However, this finding is contradictory to the fact that EBV-infected cells are usually of the B-cell lineage. Recurrence of TUGSE lesion has been reported in only two cases with CD30+ cells and a monoclonal rearrangement of the TCR γ chain gene [1-8]

Conclusion

Traumatic ulcerative granuloma with stromal eosinophilia (TUGSE) appears to be quite neglected by the clinicians due to the limited knowledge and awareness. It is important to recognise this mucosal entity as it has a close resemblance with malignancy of the oral cavity. Prognosis of TUGSE is normally favourable and aggressive surgical treatment is usually not required.

References

1. Salisbury CL, Budnick SD, Li S. T-cell receptor gene rearrangement and CD30 immunoreactivity in traumatic ulcerative granuloma with stromal eosinophilia of the oral cavity. *Am J Clin Pathol.* 2009; 132:722e7.
2. Fonseca FP, de Andrade BA, Coletta RD. Clinicopathological and immunohistochemical analysis of 19 cases of oral eosinophilic ulcers. *Oral Surg Oral Med Oral Pathol Oral Radiol Endod.* 2013; 115:532e40.
3. Elzay RP. Traumatic ulcerative granuloma with stromal eosinophilia (Riga-Fede's disease and traumatic eosinophilic granuloma). *Oral Surg Oral Med Oral Pathol.* 1983; 55:497e506.
4. Hirshberg A, Amariglio N, Akrish S. Traumatic ulcerative granuloma with stromal eosinophilia: a reactive lesion of the oral mucosa. *Am J Clin Pathol.* 2006; 126:522e9.
5. Elovic AE, Gallagher GT, Kabani S, Galli SJ, Weller PF, Wong DT. Lack of TGF-alpha and TGF-beta 1 synthesis by human eosinophils in chronic oral ulcers. *Oral Surg Oral Med Oral Pathol Oral Radiol Endod.* 1996; 81:672e81.
6. Alobeid B, Pan LX, Milligan L, Budel L, Frizzera G. Eosinophilrich CD30 β lymphoproliferative disorder of the oral mucosa. A form of "traumatic eosinophilic granuloma". *Am J Clin Pathol.* 2004; 121:43e50.
7. Chatzistamou I, Doussis-Anagnostopoulou I, Georgiou G. Traumatic ulcerative granuloma with stromal eosinophilia: report of a case and literature review. *J Oral Maxillofac Surg.* 2012; 70:349e53.
8. Segura S, Romero D, Mascaró Jr JM, Colomo L, Ferrando J, Estrach T. Eosinophilic ulcer of the oral mucosa: another histological simulator of CD30 β lymphoproliferative disorders. *Br J Dermatol.* 2006; 155:460e3.
9. de Leval L, Gaulard P. CD30 β lymphoproliferative disorders. *Haematologica.* 2010; 95:1627e30.
10. Abdel-Naser MB, Tsatsou F, Hippe S. Oral eosinophilic ulcer, an Epstein-Barr virus-associated CD30 β lymphoproliferation? *Dermatology.* 2011; 222:113e8.
11. Regezi JA, Zarbo RJ, Daniels TE, Greenspan JS. Oral traumatic granuloma. Characterization of the cellular infiltrate. *Oral Surg Oral Med Oral Pathol.* 1993; 75:723e7.
12. Ficarra G, Prignano F, Romagnoli P. Traumatic eosinophilic granuloma of the oral mucosa: a CD30 β (Ki-1) lymphoproliferative disorder? *Oral Oncol.* 1997; 33:375e9.