



ISSN Print: 2394-7489
ISSN Online: 2394-7497
IJADS 2018; 4(4): 79-81
© 2018 IJADS
www.oraljournal.com
Received: 11-08-2018
Accepted: 15-09-2018

Dr. Gurnimrat Grewal
BDS, DMD, Graduate of
Dentistry from Boston
University and Currently
Practices in Calgary, Canada

Dr. Eileen Lo
MS (Ortho), FRCD, Graduate of
Dentistry, University of British
Columbia and Completed Her
Masters in Orthodontics from
University of Manitoba; She
Maintains A Private Practice
Limited to Orthodontics in
Calgary, Canada

Management of delayed eruption and orthodontic repositioning of maxillary central incisors in 12 year old female: A case report

Dr. Gurnimrat Grewal and Dr. Eileen LO

Abstract

This case highlights the importance of careful triage and communication between the general dentist and other dental specialists to ensure the best possible outcome for the patient. Another aspect that it highlights is the significance of various modalities of radiography and regular dentist visits which not only form the basis of preventative model of dental care but also help in early detection and thus, timely management of issues such as delayed eruption.

Keywords: management of delayed eruption, maxillary central incisors

Introduction

Case presentation

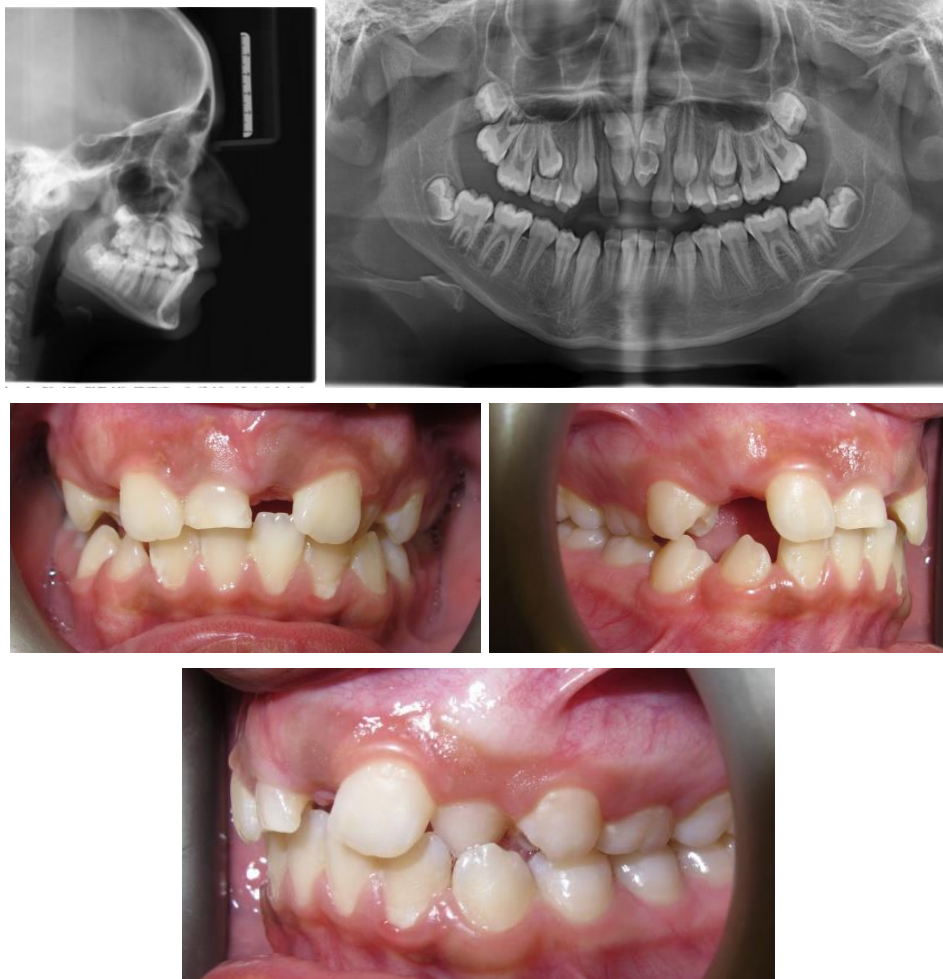
An 11 year old female with late mixed dentition was seen at our family dental practice as a new patient. The patient's mother's chief concern was missing "front teeth". The patient was otherwise healthy with no other significant medical history. She was not taking any medications and had never been treated for a serious illness or required hospitalization. She had not received routine dental maintenance for past four years and primarily saw the dentist only when an issue arose. Brief family history was taken to check for hereditary aspect of anodontia, which was negative for the same. Extra oral examination revealed mild retrognathic mandibular skeletal pattern. Intraoral examination revealed late mixed dentition with dental class II malocclusion. At the time of examination the primary dentition present was maxillary right second molar, right central incisor, left canine and left second molar. Oral hygiene was fair. Patient reported brushing with manual toothbrush twice a day and sporadic flossing.

Baseline imaging was done with bitewing x-rays and a panoramic radiograph. Pre-treatment panoramic radiograph revealed two supernumerary teeth in the positions of right and left Maxillary central incisors. The central incisors were found to be impacted deep over the supernumerary teeth. Due to the two dimensional nature of the PAN x-ray it was impossible to predict the exact orientation of the impacted adult teeth and if their roots were fully formed. At this point the parents were informed that further imaging was essential to determine if these central incisors could be orthodontically repositioned and that treatment planning would likely involve dental specialists such as Orthodontist and Oral and Maxillofacial surgeon. Any decision on how to proceed could only be made after consultation with the Orthodontist. Based upon the results of further imaging and viability of the impacted central incisors the treatment could involve surgical exposure followed by fixed orthodontics or surgical removal followed by space maintenance and implant supported prosthesis once the skeletal growth is complete.

Patient was then referred to the Orthodontist for assessment and treatment planning. Lateral cephalogram indicated horizontally impacted maxillary incisors whose crowns were directed upwards and incisal edges forward.

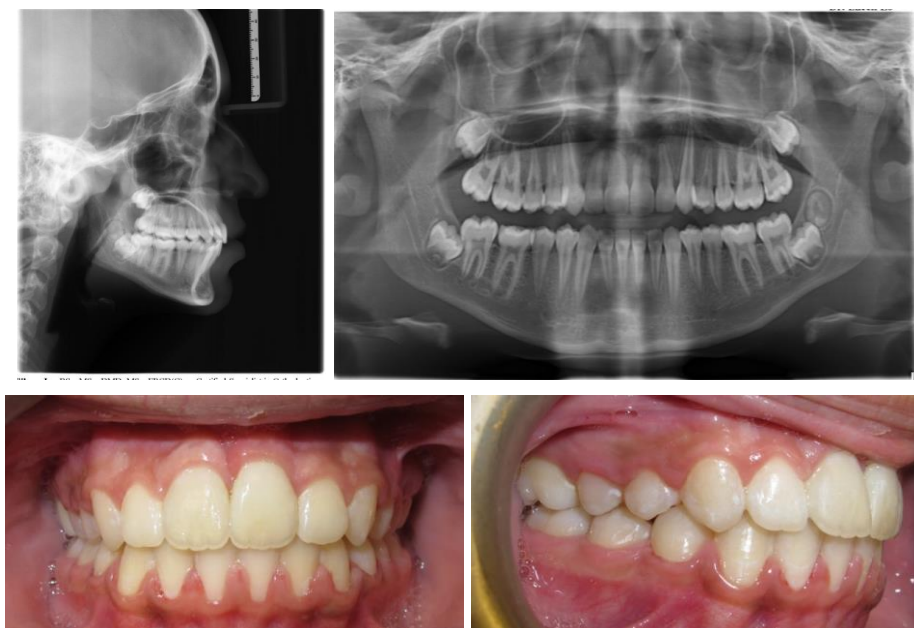
Correspondence

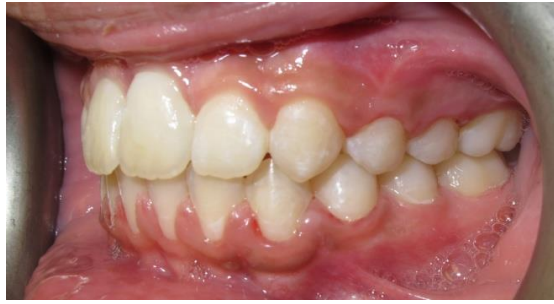Dr. Gurnimrat Grewal
BDS, DMD, Graduate of
Dentistry from Boston
University and Currently
Practices in Calgary, Canada



Treatment was started with removal of supernumeraries and surgical exposure of the impacted maxillary incisors by the oral and maxillofacial surgeon followed by traction of impacted incisors with fixed orthodontics treatment. Post treatment records indicate a dental class I occlusion with OJ =2mm OB=10%. Her posterior teeth are in proper interdigitation. Post treatment radiographs suggested that the maxillary right central incisor and maxillary left central incisors may have dilacerated roots. The root of the maxillary right central incisor may be shorter than that of the left central

incisor. Clinical examination revealed slight discoloration of the aligned maxillary incisors, which requires ongoing assessment for nerve vitality. Post treatment retention protocol is life time retention with removal retainers to maintain tooth alignment. She is being monitored for the need of fixed lingual retainers if the maxillary central incisors showed any signs of intrusive movement.





Discussion

Supernumerary teeth can interfere with eruption of teeth frequently in the pre maxillary region. They can delay eruption of the central incisors in 26-52% cases and can also cause ectopic eruption and displacement in 26%-63% cases in the central incisors [8]. If the delayed eruption is noted and managed in early mixed dentition there is greater chance of eruption of central incisors through normal eruptive forces. Delay in management after completion of root formation will almost always require use of orthodontic forces to erupt the maxillary incisors [8]. If left untreated the unerupted incisor can lead to esthetic, functional and pathological concerns. There might be mesial migration or tipping of the adjacent teeth due to availability of space, cyst formation around impacted teeth can occur over time, pressure from the impacted teeth can cause root resorption of adjacent teeth [11]. Presence of these teeth in the pre maxillary region can complicate treatment in case implant therapy is needed.

References

1. Supernumerary teeth: Report of four unusual cases Arun Kumar, Ritu Namdev, Lokesh Bakshi, Samir Dutta.
2. Supernumerary teeth- An overview of Classification, Diagnosis and management M. Thérèse Garvey, B. Dent. Sc, D. Orth., M. Orth., M.Sc., FDS Hugh J. Barry, BDS, MA, FDS, FFD Marielle Blake, B. Dent. Sc., MA, D. Orth., M. Orth., FDS(Orth.), MRCD(C).
3. Agnihotri A, Marwah N, Dutta S. Dilacerated unerupted central incisor: A case report. *J Indian Soc Pedod Prev Dent.* 2006; 24:152-54.
4. Nik-Hussein NN. Supernumerary teeth in the premaxillary region: its effects on the eruption and occlusion of the permanent incisors. *Aust Orthod J.* 1990; 11:247-50
5. Hall AM. Supernumerary upper anterior teeth. *Br Dent J.* 2000; 188:642-43.
6. Management of Unerupted maxillary Incisors: Omar Yaqoob, Julien O' Neill, Terry Gregg, Joe Noar, Martyn Cobourne, David Morris
7. Management of Delayed Eruption of Permanent Maxillary Incisor associated with the Presence of Supernumerary Teeth: A Case Report Naveen Manuja, Nagpal, Mousomi Singh, Seema Choudhary. *Int J Clin Pediatr dent.* 2011; 4(3):255-259.
8. Gardiner JH. Supernumerary teeth. *Dent Pract.* 1961; 12:63-73.
9. Solares R. The complications of late diagnosis of anterior supernumerary teeth: A case report. *ASDC J Dent Child.* 1990; 57(3):209-211.
10. Rusmah M. Natal and neonatal teeth: a clinical and histological study
11. Eruption Disturbances of the Maxillary Incisors: A Literature Review Kristin L. Huber*/ Lokesh Suri **/ Parul Taneja. *J Clin Pediatr Dent.* 1991; 15:251-253.