



ISSN Print: 2394-7489  
ISSN Online: 2394-7497  
IJADS 2018; 4(4): 356-360  
© 2018 IJADS  
www.oraljournal.com  
Received: 14-08-2018  
Accepted: 18-09-2018

**Dr. Hina Zainab**  
Professor & Head, Department  
of Oral Pathology and  
Microbiology, Al-Badar Dental  
College and Hospital, Gulbarga,  
Karnataka, India

**Dr. Mohammad Khaja Moinuddin**  
PG. Student, Department of  
Oral Pathology and  
Microbiology, Al-Badar Dental  
College and Hospital, Gulbarga,  
Karnataka, India

**Dr. Shahnaaz Saba**  
PG. Student, Department of  
Oral Pathology and  
Microbiology, Al-Badar Dental  
College and Hospital, Gulbarga,  
Karnataka, India

## Assessment of field cancerization in apparently safe surgical margins in radical neck dissection specimens of oral squamous cell carcinoma

**Dr. Hina Zainab, Dr. Mohammad Khaja Moinuddin and Dr. Shahnaaz Saba**

### Abstract

**Introduction:** The oral cavity is one of the predominant and prevalent sites of development of potential malignancies, since it comes into direct contact with many carcinogens. Despite monitoring the original tumor site following an advanced surgical and non-surgical therapy, the overall mortality rate remains unchanged probably due to the recurrence of the tumor either locally or at a remote site, development of second primary tumors, even when the surgical margins are histopathologically free from tumor corroborates to the concept of field cancerization.

**Aim:** To determine the histological characteristics of mucosa which appears normal clinically at different sites from the apparent tumor margins in oral squamous cell carcinoma patients.

**Materials and Methods:** A total of 15 pre diagnosed cases of oral squamous cell carcinoma were included in the study. The cases were clinically evaluated for safe margins using vital staining and the resected RND specimens were eventually evaluated histologically for field cancerization.

**Results:** The observations in the present study showed that, 6 (40%) out of 15 cases with tumor infiltration into the adjacent margins (vital stain negative areas) at a distance of 1cm from the so called clinically safe surgical margins even after the surgeons employed vital staining for safe margins during pre-operative period. When the margins were statistically evaluated all parameters showed statistically significant differences.

**Conclusion:** This study probably assess field cancerization of clinically normal appearing mucosa at different sites from the apparent tumor margins in oral squamous cell carcinoma patients.

**Keywords:** field cancerization, squamous cell carcinoma, RND

### Introduction

“Field Cancerization” is the term which was introduced in 1953 to describe histologically abnormal tissues surrounding oral squamous cell carcinoma, particularly in the upper aerodigestive tract, likely related to exposure to carcinogens. Lateral cancerization is an another term used subsequently to indicate the lateral spread of tumors which was due to progressive transformation of cells adjacent to a tumor. The concept of field cancerization is most commonly associated with the development of multiple cancer, in which several tumors develop at different distant sites due to gene aberration induced by carcinogens<sup>[1]</sup>.

The field of genetically altered cells in patients with squamous cell carcinoma called ‘field cancerization’, has been documented with numerous clinical, histopathological and molecular studies. Therefore, the patients with head and neck squamous cell carcinoma are subject to risk of developing local recurrences or second primary tumors as a consequence of field cancerization, which is considered to be a bad prognostic sign<sup>[2]</sup>.

The optimal width of the surgical margin for oral cancer has always been an issue of debate. There however has not been consensus on the impact of margin status on survival. A decrease in survival with a positive margin has been reported by some, but not by other investigators. A close, but clear margin, is also felt to contribute to an adverse outcome. This consideration is important in establishing the adequate depth and width of surgical resection. The most widely accepted definition of a close margin is tumor within 5 mm of the inked resection margin<sup>[3]</sup>.

This an arbitrary designation and when recurrence rates are specifically cited for close margins they are generally less than the rate observed for patients with tumor at the inked resection margin.

### Correspondence

**Dr. Hina Zainab**  
Professor & Head, Department  
of Oral Pathology and  
Microbiology, Al-Badar Dental  
College and Hospital, Gulbarga,  
Karnataka, India

Patients with clear but close margins are often considered from a clinical standpoint to have positive or inadequate margins. The precise definition of the clear or adequate surgical margin is an important prognostic consideration with clinical implications in the selection of patients for adjunctive treatment. An inadequate surgical margin, including the clear but close margin, is generally considered an indication for adjunctive radiotherapy. This study examines the impact of the width of the close surgical margin on treatment outcome following the surgical resection of oral cancer [3].

Although histological grade and tumor size are important prognostic factors, inadequate resection margins remain one of the most significant predictors of local recurrence for bone and soft tissue carcinomas, even in the presence of adjuvant therapies [2, 3].

**Methodology**

A total of 15 RND specimens were retrospectively evaluated with respect to gross and histopathological features. The specimens were grossly evaluated for tumor infiltration by vital staining done by the surgeons during resection. All the margins marked as safe were sectioned and evaluated for tumor invasion. The results were tabulated and subjected for statistical analysis.

**Results**

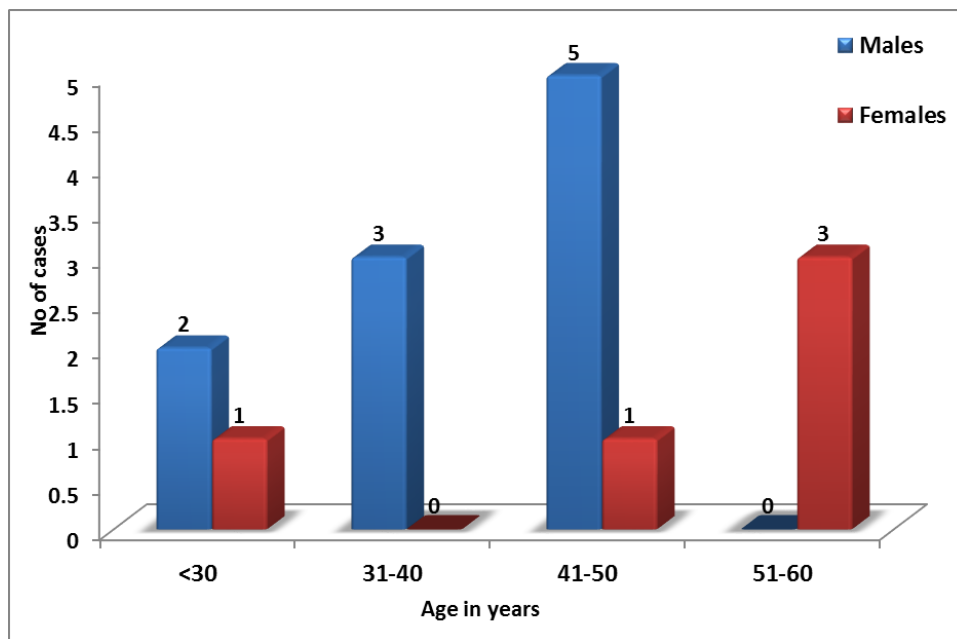
The data thus obtained were tabulated. Statistical analysis was

performed using IBM SPSS 20.0 version software. Data was spread on excel sheet and calculated statistical parameters mean and standard deviation. For quantitative data analysis applied unpaired t test, for qualitative data analysis chi-square test were applied for statistical significance. If p value was less than 0.05 considered as significant.

**Table 1:** Age and sex wise distribution of cases

Age in years	Males		Females		Total	
	No.	%	No.	%	No.	%
<30	2	20.0	1	20.0	3	20.0
31-40	3	30.0	0	0.0	3	20.0
41-50	5	50.0	1	20.0	6	40.0
51-60	0	0.0	3	60.0	3	20.0
Total	10	66.7	5	33.3	15	100.0
Mean	39.3 ± 8.22		47.0 ± 10.88		41.86 ± 9.56	
t = test, P-value Significance	t = 1.54 P = 0.147 NS					

In the present study conducted on 15 cases; 10 (66.7%) males and 5 (33.3%) females. There were 60 margins; among them 54 (90.0%) margins were negative and 6 (10.0%) margins were positive. The mean age of males was 39.3 ± 8.22 and females mean age was 47.0 ± 10.88. There was no statistical significant difference of age among males and females (P>0.05).



**Chart 1:** Multiple bar diagram represents age and sex wise distribution of cases

**Table 2:** Comparison of methods of diagnosis

Methods of diagnosis	OSCC Positive cases	OSCC Negative cases	Total	Test value, P- value & significance
Histopathological	6 (40.0%)	9 (60.0%)	15	χ² Yates = 7.5, P<0.01, HS
Clinical	0 (0.0%)	15 (100.0%)	15	

Out of 15 cases, 6 (40.0%) cases of OSCC showed positive margins which were diagnosed histopathologically, whereas clinically these margins appeared negative. Study reveals that, there was statistically highly significant difference in diagnosis of OSCC positive margins (P<0.01).

Histopathological diagnosis was better to determine the histological characteristics of mucosa which appears clinically normal at different sites from the apparent tumor lesion margins in radical neck dissection specimens of oral squamous cell carcinoma.

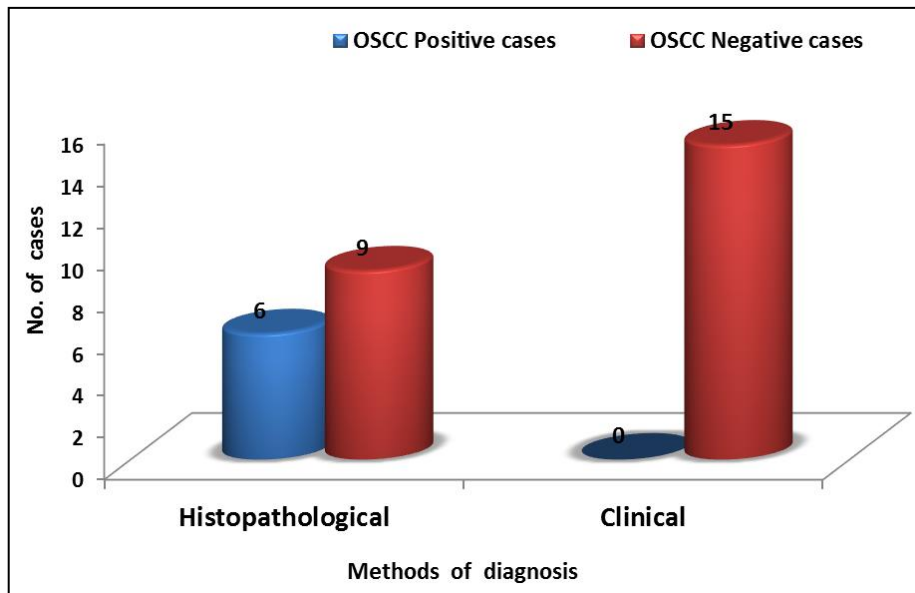


Chart 2: Multiple bar diagram represents comparison of methods of diagnosis

Table 3: Comparison of variables among OSCC Positive and Negative Margins

Variables		OSCC Positive cases	OSCC Negative cases	Test value, P- value & Significance
		Mean ± SD	Mean ± SD	
Measurement in mm	Anterior Margin	1.136 ± 0.15	1.044 ± 0.73	t = 0.39, P= 0.75, NS
	Inferior Margin	1.183 ± 0.33	0.921 ± 0.22	t = 1.89, P= 0.09, NS
	Posterior Margin	1.812 ± 2.04	1.173 ± 0.55	t = 0.91, P= 0.38, NS
	Superior Margin	1.812 ± 2.04	0.951 ± 0.20	t = 1.27, P= 0.22, NS
Age in years	-----	40.50 ± 11.87	42.73 ± 8.33	t = 0.44, P= 0.67, NS
Sex	Male No of cases	4	6	χ <sup>2</sup> <sub>yates</sub> = 0.01, P>0.05, NS
	Female No of cases	2	3	

Study reveals that, the mean measurement of anterior margin, inferior margin, posterior margin and superior margin in OSCC positive cases appears to be greater compare to OSCC negative cases. But statistically no significant difference in mean measurement of anterior margin, inferior margin, posterior margin and superior margin among OSCC positive and negative cases ( $P>0.05$ ) was seen.

There was no statistical significant difference of age and sex among OSCC positive and negative cases ( $P>0.05$ ).

### Discussion

Field cancerization also called field effect or field defect is a biological process in which large areas of cells at a tissue surface or within an organ are affected by carcinogenic alterations. Some molecular changes such as epigenetic changes and acquired genetic mutations are associated with field cancerization which occurs over a widespread, multifocal field. These molecular changes which are initial may later on progress to a recognizable foci of dysplasia and eventually lead carcinoma in situ (CIS) or cancer [4].

In the present study conducted on 15 cases; 10 (66.7%) males and 5 (33.3%) females. There were 60 margins; among them 54 (90.0%) margins were negative and 6 (10.0%) margins were positive. The mean age of males was  $39.3 \pm 8.22$  and females mean age was  $47.0 \pm 10.88$ . There was no statistical significant difference of age among males and females ( $P>0.05$ ) (Table 1 and chart 1).

The main objective of this investigation was to correlate clinically safe margin with histological evaluation. The surgical margin, called the surgical safety margin, is an important consideration when resecting primary oral cancers. In a review of surgical margins in head and neck cancer, 90% of surgeons considered the final resection margin to be

negative [4].

Study observes that, Out of 15 cases, 6 (40.0%) were OSCC positive which were diagnosed histopathologically, whereas clinically these cases appeared negative. Study reveals that, there was statistically highly significant difference in diagnosis of OSCC positivity among histopathological and clinical diagnosis ( $P<0.01$ ). Histopathological diagnosis was better to determine the histological characteristics of mucosa which appears clinically normal at different sites from the apparent tumor lesion margins in radical neck dissection specimens of oral squamous cell carcinoma. (Table 2 and Chart 2).

The clinical resection margin necessary to achieve an adequate histologic margin on permanent section needs to take into consideration the fact that surgical specimens shrink, in the order of 40% to 50%, when fixed in formalin. Thus, a minimum intraoperative resection margin of at least 1 cm is required to factor the ex vivo shrinkage. As systematically evaluated, a margin of 1 cm or more was associated with the significant overall safe clinical margin. The less than or equal to 5 mm but clinically clear margin was associated with a significant risk of recurrence [5]. Our results suggest that the widely accepted margin of 5 mm as “close” needs to be reassessed. In this study, the difference in the clinical margins and histological margins between 5-mm and 1-cm margins of excision showed significant differences.

The observations in the present study showed that, 6 (40%) out of 15 cases showed tumor infiltration into the adjacent margins (vital stain negative areas) at a distance of 1cm from the so called clinically safe surgical margins even after the surgeons employed vital staining for safe margins during pre-operative period (Table 3).

The results of this study indicate that clinically normal-

looking mucosa adjacent to tumor lesion in patients with oral squamous cell carcinoma had suffered certain histomorphologic changes. These histological abnormalities manifested were in conjunction with the study done by Yuichiro Okazaki showing signs of chronic mucosal irritation, cellular atypia, mild epithelium dysplasia or even squamous cell carcinoma caused by the effects of carcinogens (smoking, alcohol, radiation) on the entire oral mucosa<sup>[6]</sup>.

Similar results to ours were obtained by Thomson *et al.*,<sup>[7]</sup> in patients with a unilateral OSCC or a premalignant lesion with the sample of 26 consecutive new patients, 15 of them (58%) showed histologically abnormal tissue<sup>[7]</sup> in accordance with our study where 6 (40%) out of 15 cases showed tumor infiltration into the adjacent margins.

The field change can be large, a diameter of >70 mm in the oral cavity and oropharynx has been reported<sup>[7]</sup>. We have found histologically abnormal tissue of clinically normal looking mucosa at a distance of 1 cm from the tumor lesion in 6 (40%) patients. This concurs with the concept of field cancerization and questions the efficacy of the vital stains. In our study, we found 1 case, revealed tumor invasion at a distance of 6.5cms from the tumor mass and our findings were in accordance with studies conducted by Tabor *et al.*, that field change can be large and reported a diameter of >7cms in oral cavity and oropharyngeal lesions. These results show that increasing the distance between biopsy samples would significantly relate with the reduced degree and number of histological abnormalities of the oral mucosa adjacent to oral cancer<sup>[7]</sup>.

Inzeet *et al.*, state the role of chronic mucosal irritation induced by tobacco carcinogens in the multistep process of sequential neoplastic development in the upper aerodigestive tracts. On the biopsy specimen of the normal-looking mucosa, cellular pleomorphism, disorder in cellular maturation and the presence of inflammatory cells within the epithelium can be evaluated histologically<sup>[3]</sup>.

Boloching *et al.*, confirmed the concept of field cancerization by significantly increasing micronuclei (MN) count in patients with OSCC, especially in heavy smokers, as a result of the cytogenetic damage of the buccal mucosa cells. Comparing histological and molecular characteristics of the field with genetically altered cells based on the loss of the heterozygosity<sup>[3]</sup>.

Tabor *et al.*, suggest that precursor lesions are macroscopically not visible to the surgeon, however pathologists can recognize most of these lesions as mild dysplasia<sup>[3]</sup>, which was confirmed in 6 (40%) patients in our study. It has been previously described that altered expression of p53 genes in the histologically tumor-free surgical resection margins adjacent to the primary tumor may have indicated an early stage of cancer development. The high incidence of TP53 mutation in histologically tumor-free surgical margins in oral squamous cell carcinoma patients that has been reported in some studies is associated with an increased risk of developing local recurrences and multiple primary tumors<sup>[3, 7]</sup>.

On the other hand, some authors have previously shown no or small p53 activity, as well as rare TP53 mutation on the biopsy material in histologically normal epithelium adjacent to OSCC. This contradiction of results suggests that even with the lack of conventional histological examination, the application of the sophisticated diagnostic methods is not able to show a clear image of molecular events in clinically and histologically normal mucosa adjacent to oral squamous cell carcinoma, which indicated the complex nature of the field

cancerization concept<sup>[8-10]</sup>.

Poh *et al.*, previously reported that subclinical high-risk fields with cancerous and precancerous changes can be identified by direct visual fluorescence in the operating room setting. Some authors describe that a high proliferative status of oral mucosa epithelium, which has been found using Ki-67 expression in areas very distant from the primary tumor, is associated with the existence of premalignant fields, therefore it is a bad prognostic sign and indicator of the risk of development of new tumors<sup>[11]</sup>.

The association of margins with positive status in various studies indicate that negative margins are harder to achieve with large tumor loads, proximity to the mandible and location at the most posterior area in the oral cavity<sup>12</sup>. In a similar fashion, the ability to achieve a wide negative margin was associated with the use of composite resection and segmental mandibulectomy in this study. Therefore it can be considered that a wider margin may be necessary for achieving a margin which is histologically negative in a tumor that invades deeply as cords and nests of cells. The aggressiveness of the disease is indicated by the presence of tumor recognized at the resection margin. This area requires further evaluation in a large, well-designed prospective study using a standard definition for margin status

## Conclusion

Field cancerization possess a greater challenge, as it influences the morbidity and mortality of oral cancer patients. The presence of a field with genetically altered cells is a risk factor for cancer. It is necessary to give greater importance to field cancerization in oral squamous cell carcinoma patients for successful treatment and prevention of second primary tumors. Early identification and management of field change is a vital determinant for prevention of cancer mortality and morbidity.

Finally, it can also be concluded that vital stains need to be conjugated with alternative adjuvant methods in assessing the safe surgical margins to help the patients with respect to recurrence and better life expectancy. According to literature 5mm – 1.5cm is considered to be an adequate safe surgical margin, comparing the literature with our data the safe surgical margins cope up with a lower efficiency, therefore the accuracy of safe surgical margins remains questionable.

We hereby conclude that 1cm may not be an adequate safe surgical margin but a more sample size is recommended to comment for assessing the efficacy of vital stains and clinically safe surgical margins in field cancerization.

## Acknowledgement

Authors acknowledge the immense help received from the scholars whose articles are cited and included in references of this manuscript. The authors are also grateful to authors/ editors/ publishers of all those articles, journal and books from where this article has been reviewed and discussed.

## References

1. Archives of Medicine and Health Sciences / Jul-Dec 2013; 1(2).
2. Journal of Cancer Research and Therapeutics. 2013; 9(2).
3. Oral Surg Oral Med Oral Pathol Oral Radiol Endod. 2009; 107:625-629.
4. Archives of Medicine and Health Sciences / Jul-Dec 2013; 1(2).
5. Asian J Oral Maxillofac Surg. 2007; 19(2).
6. Journal of Cancer Research and Therapeutics. 2013

9(2):3.

7. Tabor MP, Braakhuis BJ, Van Der Wal JE, van Diest PJ, Leemans CR, Brakenhoff RH, *et al.* Comparative molecular and histological grading of epithelial dysplasia of the oral cavity and the oropharynx. *J Pathol.* 2003; 199:354-60.
8. Tabor MP, Brakenhoff RH, Ruijter-Schippers HJ, van der Wal JE, Snow GB, Leemans CR, *et al.* Multiple head and neck tumors frequently originate from a single preneoplastic lesion. *Am J Pathol.* 2002; 161:1051-60.
9. Thode C, Bilde A, von Buchwald C, Dabelsteen E. TP53 mutations in clinically normal mucosa adjacent to oral carcinomas. *J Oral Pathol Med.* 2010; 39:662-6.
10. Montebugnoli L, Gissi DB, Badiali G, Marchetti C, Cervellati F, Farnedi A, *et al.* Ki-67 from clinically and histologically “normal” distant mucosa as prognostic marker in early-stage (T1-T2N0) oral squamous cell carcinoma: Aprospective study. *J Oral Maxillofac Surg.* 2011; 69:2579-84.
11. Gonzales-Moles MA, Bravo M, Ruiz-Avila I, Acebal F, Gil-Montoya JA, Brener S, *et al.* Ki-67 expression in non-tumour epithelium adjacent to oral cancer as risk marker for multiple oral tumors. *Oral Dis.* 2010; 16:68-75.
12. Huang X, Pateromichelakis S, Hills A, Sherriff M, Lyons A, Langdon J, *et al.* p53 mutations in deep tissues are more strongly associated with recurrence than mutation-positive mucosal margins. *Clin Cancer Res.* 2007; 13:6099-106.