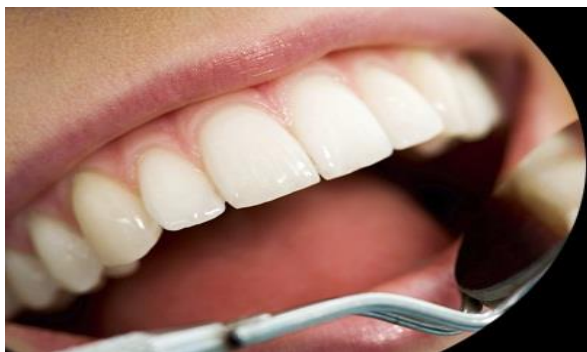



ISSN Print: 2394-7489
ISSN Online: 2394-7497
IJADS 2019; 5(1): 77-82
© 2019 IJADS
www.oraljournal.com
Received: 06-11-2018
Accepted: 10-12-2018

Dr. Bhawna Verma
MDS, Dept. of Pedodontics and
Preventive Dentistry,
Government Dental College and
Hospital, Ahmedabad, Gujarat,
India

Dr. Shantanu Choudhari
MDS, Dept. of Pedodontics and
Preventive Dentistry,
Government Dental College and
Hospital, Ahmedabad, Gujarat,
India

Dr. Swati Goyal
MDS, Dept. of Pedodontics and
Preventive Dentistry,
Government Dental College and
Hospital, Ahmedabad, Gujarat,
India

Dr. Gaurav Vispute
MDS, Deptt. of Pedodontics and
Preventive Dentistry,
Government Dental College and
Hospital, Ahmedabad, Gujarat,
India

Dr. Kanwaljeet Bharti
MDS, Dept. of Pedodontics and
Preventive Dentistry,
Government Dental College and
Hospital, Ahmedabad, Gujarat,
India

Dr. Suchita Choudhari
Dept. of Pedodontics and
Preventive Dentistry,
Government Dental College and
Hospital, Ahmedabad, Gujarat,
India

Correspondence

Dr. Bhawna Verma
MDS, Dept. of Pedodontics and
Preventive Dentistry,
Government Dental College and
Hospital, Ahmedabad, Gujarat,
India

Comparative evaluation of success of pulpotomy in primary molars treated with Formocresol, Pulpotec and Biodentine- 6 month follow up study

Dr. Bhawna Verma, Dr. Shantanu Choudhari, Dr. Swati Goyal, Dr. Gaurav Vispute, Dr. Kanwaljeet Bharti and Dr. Suchita Choudhari

Abstract

Background: Pulpotomy is generally performed with *Formocresol* in primary molars despite its disadvantages like cytotoxicity, necrosis, mutagenic and carcinogenic potential. Hence new materials like Pulpotec and Biodentine were used in this study to compare the success rates of the three materials.

Aim: To evaluate and compare the radiographic and clinical success of formocresol, pulpotec and biodentine as pulpotomy medicaments in primary molars.

Methodology: The study was conducted on 90 primary molars in children aged between 4-9 years. The pulpotomy procedure was performed on the 90 selected teeth which were randomly divided into three groups according to the pulp dressing material used. The patients were recalled again for clinical and radiographic evaluation after 3 and 6 months. The data was statistically analysed using Chi-square test ($P < 0.05$) and Anova single factor test to perform comparisons between the groups.

Result: At the end of 6 months, clinical success was 100% for all the three groups. Whereas radiographic success was 96.7% for formocresol and 100% for both pulpotec and biodentine group.

Conclusion: This study showed that Pulpotec and Biodentine used for primary teeth pulpotomy has good success rates on follow-up; and hence can be used as alternatives to Formocresol.

Keywords: pulpotomy, primary molars, biodentine, pulpotec

Introduction

A major goal in pediatric dentistry is to maintain primary dentition in an intact state until permanent successors erupt. Primary dentition is essential for maintenance of arch length, mastication, speech and esthetics and prevention of abnormal oral habits. Pulp diseases and trauma to pulp can lead to loss of vitality. This does not mean that tooth needs removal; it can be retained in oral cavity in a functional state with appropriate treatment^[1]. Maintaining the pulpally involved deciduous teeth in a healthy state until the time of normal exfoliation remains to be one of the prime concern for pedodontists^[2].

A high proportion of deep carious lesions in primary teeth is associated with pulpal exposure. The removal of the infected coronal pulp tissue (pulpotomy) is one of the treatment methods employed. In order to enhance treatment, to fix the pulp tissue and to preserve its vitality, the surface of the pulp is covered with a therapeutic agent. Since the years, many materials were researched upon to be used as a pulpotomy medicament.

Formocresol is regarded as the 'gold standard' and was first used for pulpotomy by Sweet (1930)^[3] with a 97% success rate. Formocresol induces an area of necrosis in the adjacent pulp tissue with the fixative effect diminishing as it progresses apically. The apical third of the pulp is unaffected, and retains its vitality for an extended time (Heys *et al.* 1981)^[4,5] However, the use of Formocresol has been challenged because of its deleterious effects, potential carcinogen in action, immune sensitization, mutagenicity and cytotoxicity^[6-10].

Hence, researchers have continued their efforts in the direction for invention of new dental materials with better properties and promising results over pulp healing process than Formocresol. The thought has led to the development of materials like Pulpotec and Biodentine which were used in this study.

Pulpotec (PD) is a radiopaque non resorbable material for simple rapid and long term treatment for pulpotomy of vital molar, the vitality of the residual radicular pulp after

treatment with Pulpotec is undisputable. Pulpotec is commercially available as resinous cement that contains polyoxymethylene, iodoform, dexamethasone acetate, formaldehyde, phenol, guaiacol, and excipient. It acts by cicatrization of the pulpal stump at the chamber-canal interface, while maintaining the structure of underlying pulp [11].

Biodentine™ (Septodont Ltd., Saint Maur des Fausse's, France) is a new tricalcium silicate (Ca₃SiO₅) based inorganic restorative commercial cement and advertised as 'bioactive dentine substitute'. The material is claimed to possess better physical and biological properties compared to other tricalcium silicate cements such as mineral trioxide aggregate (MTA) and Bioaggregate™ (Bioaggregate) [12, 13]. It is also used for single visit apexification procedures, direct and indirect pulp capping and perforation repair [14-16].

The success of a pulpotomy may also be influenced by the final restoration placed on the tooth [17]. Therefore in this study, we have given stainless steel crown as the final post op restoration for each tooth. The present study was aimed at evaluating the success of pulpotomy outcomes using Formocresol, Pulpotec and Biodentine; and comparing the efficacy of the agents used, both clinically as well as radiographically.

Materials and Methods

It was a randomized, double blind, controlled clinical trial carried out in the Department of Pedodontics and Preventive Dentistry, Ahmedabad. The study design was approved by the ethical committee of Government Dental College and Hospital, Ahmedabad. The study was conducted on 90 primary molars in children aged between 4-9 years visiting the department. The patients with one or more restorable and vital primary molars with deep carious lesions and no relevant medical history were screened for inclusion in the study. The 90 teeth considered for the study were radiographed preoperatively and only those who fulfill the selection criteria were included in the study.

The definitive inclusion of the screened patients was done on the basis of the following criteria:

- Children aged 4-9 years
- Carious exposure of vital pulp
- No clinical evidence of pulp degeneration like history of spontaneous or nocturnal pain, tenderness to percussion, pathologic tooth mobility, swelling or fistulous tract.
- No radiographic evidence of pulp degeneration such as internal root resorption, external root resorption or furcal radiolucency.
- Presence of 2/3rd of root
- Teeth which can be restored
- Children with prior parental consent.

The patients screened for the study were excluded if they show any of the following signs:

- History of any systemic disease
- Teeth showing clinical or radiographic evidence of pulp degeneration
- Hemostasis not achieved within 5 minutes of pulp amputation, by direct contact with a wet cotton pellet prior to the material placement
- The remaining radicular tissue was non-vital (with suppuration or purulence necrosis)
- Selected deciduous teeth without permanent successor

The selected 90 molars were divided randomly into three groups of the pulpotomy medicaments. Each group consisted of 30 molar teeth as follows:

- **Group I:** Formocresol (Control group)
- **Group II:** Pulpotec (Study group)
- **Group III:** Biodentine (Study group)

Randomization of the pulpal medicament was achieved using the envelope draw method with each sealed envelope containing the name of a medicament.

The pulpotomy procedures were all performed by a single operator. Local anesthesia was induced using lidocaine hydrochloride 2% with 1: 100,000 epinephrine and rubber dam isolation was performed. Caries removal and deroofting of the pulp chamber was performed using a high speed 330 carbide bur with ample water spray. The coronal pulp was amputated using a sterile sharp spoon excavator. The pulp chamber was irrigated with normal saline. Pulp hemostasis was achieved using a sterile wet cotton pellet applied for 2 to 3 minutes.

For the *Formocresol group*, a cotton pellet dipped in Buckley's formocresol and squeezed in a piece of cotton was placed in the pulp chamber for 1 minute (Fig. 1(a)). The pulp chamber was then covered with zinc oxide eugenol paste which was sealed with glass ionomer cement.

In the *Pulpotec group*, the treatment was provided in two visits. In the first visit and

according to the manufactures' instructions, pulpotomy was performed in the usual way. After removal of the coronal pulp tissue, the powder and the liquid were mixed on a glass slab and blended until the mix reaches the consistency of a small, supple ball of putty. The ball was then inserted directly into the pulp-chamber. The cement was condensed with help of a plastic filling instrument (Fig. 1(b)) and later sealed with temporary cement. A cotton roll was placed between the 2 dental arches and the patient was asked to bite progressively yet firmly, so that the Pulpotec paste clings to the walls of the pulp-cavity as well as to the root canal orifices. The setting time of Pulpotec is approximately 7 hours. Hence the final restoration with glass ionomer cement was done the next day once the initial Pulpotec insert has set.

Biodentine is available in the form of a premeasured capsule and unit dose liquid form. Biodentine capsule was gently tapped on a hard surface (to diffuse powder); five drops of liquid from the single dose dispenser were poured into the capsule which was placed in an amalgamator for 30 sec. The mixture of Biodentine was then introduced into the pulp chamber using amalgam carrier, and the procedure was completed as before. It was condensed tightly with a metal condenser (Fig.1(c)). After 12 minutes, once the biodentine was set, the access cavity was filled by restorative glass ionomer cement as the final restoration.

Each of the molar teeth was later restored with a stainless steel crown after 24 hours. All pulpotomized teeth were followed up clinically as well as radiographically (using periapical films size 2) by examiners other than the operator, who did not know which tooth received which material at 3 and 6 months (Fig. 2(a) (b) and (c)).

The pulpotomized teeth were judged as clinically successful if they met the following criteria:

- Absence of pain
- No tender on percussion
- No swelling/sinus
- No pathological tooth mobility

The pulpotomized teeth were judged as radiographically successful if they met the following criteria:

- No loss of lamina dura
- Normal periodontal ligament space

- No external/internal resorption
- No periapical /furcation radiolucency

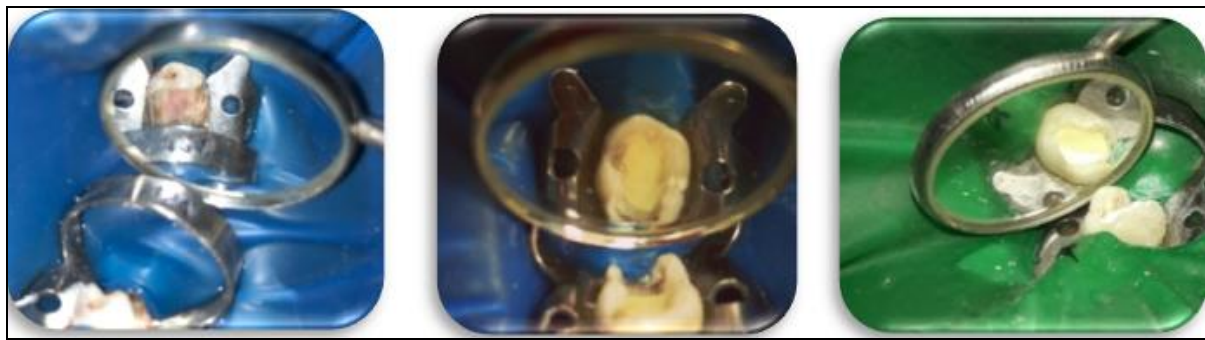


Fig 1: Application of: a) Formocresol, b) Pulpotec, c) Biodentine

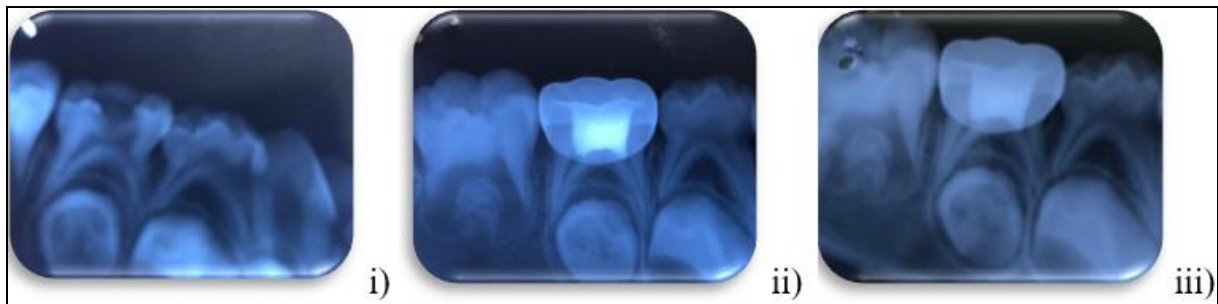


Fig 2: (a) Formocresol pulpotomy in 85 (group I): (i) Pre-operative; (ii) Follow-up after 3 months; and (iii) Follow-up after 6 months

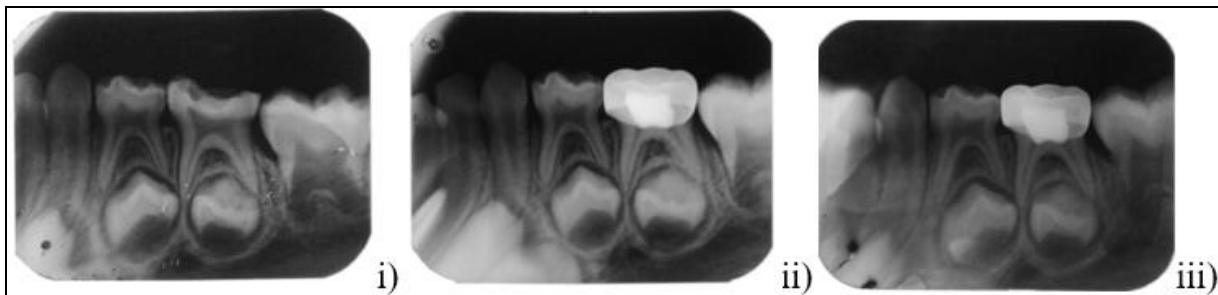


Fig 2: (b) Pulpotec pulpotomy in 75 (group III): (i) Pre-operative; (ii) Follow-up after 3 months; and (iii) Follow-up after 6 months

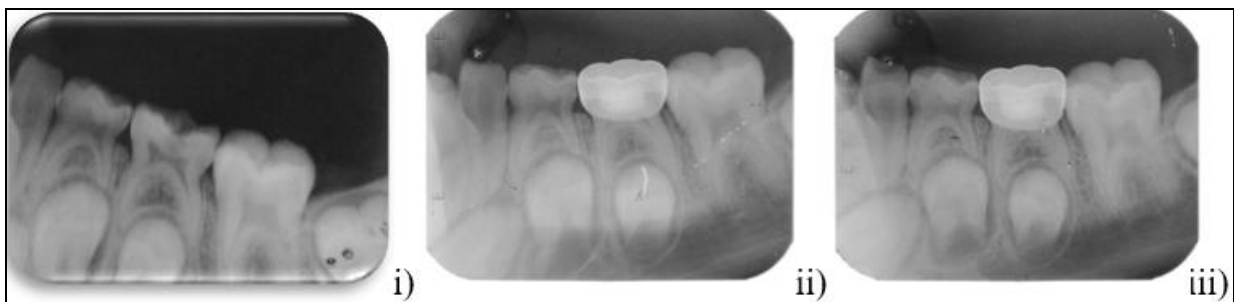

Fig 2: (c) Biodentine pulpotomy in 75 (group III): (i) Pre-operative; (ii) Follow-up after 3 months; and (iii) Follow-up after 6 months

Results

A total of 62 patients were included in the study (32 males and 30 females). Overall 90/90 teeth were available for follow up at the 3 and 6 month intervals. Data was collected, tabulated and statistically analysed using Chi- square test at a level of significance $P < 0.05$ and Anova single factortest to perform comparisons between the groups. The percentage of

mandibular teeth treated was higher than that of the maxillary molars. The most frequently treated tooth was mandibular second primary molar (52) followed by mandibular first primary molar (20), Maxillary second primary molar (10) and maxillary first primary molar (08). The baseline data of the study is summarized in table 1.

Table 1: Baseline data of the study

Characteristic	Classification and number treated
No. Of teeth treated	90 primary molars
No. According to sex	Male : 32 Female :30
No. According to age	4 yrs :6 5 yrs:12 6 yrs: 20 7 yrs:11 8 yrs:8 9 yrs:4
Mean age	6.49yrs
No. According to arch	Maxillary molars :18 Mandibular molars :72
No. According to molar type	Maxillary first primary molar :8 Maxillary second primary molar :10 Mandibular first primary molar :20 Mandibular second primary molar:52

The above comparisons concluded that the subjects of the three groups were age and sex matched and comparable (p value > 0.05) and hence may not influence the study primary outcomes. The demographic characteristics of each group are

summarized in the table no. 2.

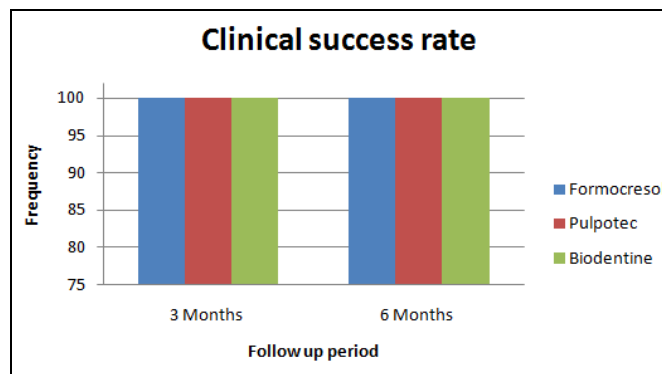
Table 2: Basic characteristics of each group

Characteristic	Formocresol group (number/%)	Pulpotec group (number/%)	Biodentine group (number/%)
Age (yrs)			
Mean +-SD	6.06+-1.36	6.67+-1.49	6.73+-1.25
Sex:			
Males	11	09	11
Females	09	12	09

Clinical success of the three pulpotomy medicaments is depicted in table 3 and graph 1. Radiographic success is shown in table 4 and graph 2.

Table 3: Clinical success of each group at follow up evaluation

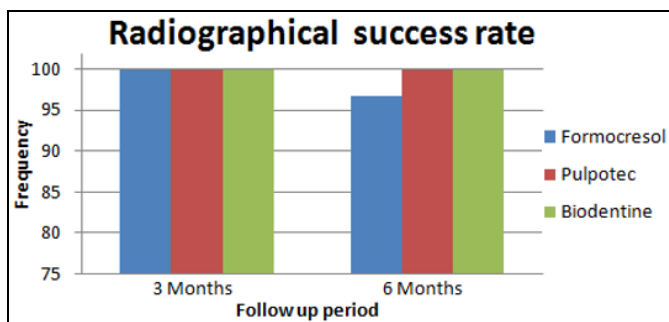
Clinical success	Formocresol (Failure/Success)	Pulpotec (Failure/Success)	Biodentine (Failure/Success)	P value
At 3 months	0/30	0/30	0/30	-
At 6 months	0/30	0/30	0/30	-
% of success	100	100	100	



Graph 1: Clinical success rates of the three medicaments at 3 and 6 month follow up period

Table 4: Radiographical success of each group at follow up evaluation

Radiographic success	Formocresol (Failure/Success)	Pulpotec (Failure/Success)	Biodentine (Failure/Success)	P value
At 3 months	0/30	0/30	0/30	-
At 6 months	1/29	0/30	0/30	0.364
% of success	96.7	100	100	



Graph 2: Radiographical success rates of the three medicaments at 3 and 6 month follow up period

Discussion

Vital pulpotomy is considered as a one-stage procedure with the objective of preserving the vitality, function of the remaining radicular portion of pulp and maintain it asymptomatic without adverse clinical signs or symptoms such as sensitivity, pain, or swelling. So the ideal requisites of any pulpotomy material should be bactericidal, harmless to

the pulp and surrounding structures, promote healing of remaining radicular pulp without interfering with the physiologic root resorption and not possess any toxicity [18]. In the present study, formocresol was selected as the control group because inspite of its reported adverse effects it is still considered by many to be the gold standard for pulpotomy and thus was used as a control agent [3, 6, 7] Pulpotec and biodentine possess anti-inflammatory and regenerative properties, respectively, thus these two materials were chosen as the experimental group to assess their efficacy as the pulpotomy medicament. Biodentine possess better sealing properties and hence can be used as the final restorative material also [11, 16].

Children between 4 to 9 years of age with at least one primary molar with deep caries were selected for this study, irrespective of their sex, race and economic or social background. This age group was selected taking into consideration the lack of cooperation in younger age group and physiological root resorption in the elder ones.

In the present study, the selection and treatment of teeth were done in accordance to the AAPD guidelines on pulp therapy

for primary teeth and immature permanent teeth, ^[19] as case selection is a very crucial factor in clinical studies involving pulpotomy, especially when young children are the subjects. The first and second primary molars of either arch were included in this study.

To remove the influence of such confounding variables, the definitive selection in the present study was done intraoperatively. Screened teeth with evidence of insufficient hemostasis or a recommencement of bleeding were excluded from the study. ^[20] In the present study, in order to standardize the treatment procedures, rubber dam isolation was used in all pulpotomies. For standardization, all pulpotomized primary molars in the present study were restored with SSCs.

All pulpotomized teeth were followed up clinically and radiographically at 3 and 6 months by two investigators other than the operator, who were blinded to the material being evaluated. After 6 month follow up period, the results of the present study showed 100% clinical success rate for all Formocresol, Pulpotec and for Biodentine treated pulpotomized teeth. The high success rates could be attributed to proper case selection, proper isolation, high aseptic standards, correct protocols and appropriate use of the three medicaments. There were no signs of clinical failure in any of the three groups.

The high success rates of formocresol in this study are in accordance with the success rates observed with other studies at 6 months follow up. ^[1, 20, 21] The high success rates of formocresol is attributed to its antiseptic and fixative properties. However the results are not in accordance with the study by Z. Dahan. ^[22] Omar EL *et al* (2016) ^[23] studied biodentine and formocresol as pulpotomy agents for primary teeth. In his study, he concluded that both the materials showed favourable radiographic and clinical outcomes at 6 month follow up period without any significant difference in which both the groups showed 100% success rates both clinically and radiographically. In his study, the only radiographic feature which was present at the follow up was pulp canal obliteration in both the groups at the follow up evaluation in contrast with the present study.

Clinically, the success rate of pulpotec obtained in this study was 100%. Pulpotec (PD) is composed of powder (polyoxymethylene, iodoform, and zinc) and liquid (dexamethasone acetate, formaldehyde, phenol, guaiacol, and subsidiary substances). The addition of pharmacological constituents will make sure that the treatment is aseptic treatment, induces cicatrization of the pulpal stump at the chamber-canal interface, whilst maintaining the structure of the underlying pulp, and also avoids the numerous failures that have been noted with total pulpectomy ^[24]. B Sunitha *et al.* (2017) ^[25] reported 94% success rates with pulpotec clinically.

At the three month follow up period, no radiographic findings were detected in any of the three groups. At 6 month evaluation, one tooth in formocresol showed widening of periodontal ligament. However, it was not associated with any external root resorption, inter radicular radiolucency radiographically or with clinical signs and symptoms of pulp degeneration. Hence PDL widening occurring all alone cannot be considered as a failure. In the pulpotec group, no tooth showed periodontal ligament widening. There were no abnormal radiographic findings in the bio dentine group in the entire follow up periods which is in accordance with the study by Omar El *et al.* (2016) ^[23]

The results of current study showed that there was no statistically significant difference between the groups

($p > 0.05$). Hence both the agents can be used as alternative pulpotomy agents to formocresol in primary teeth.

The present study has been designed to overcome potential bias and confounding variables as much as possible. Still we recognize some factors as minor limitations which might be curtailed in future studies. The main limitations being smaller sample size and shorter follow up period. Unfortunately, the three materials were of different types, requiring different protocols and manipulations, the examiners's cognitive bias for either pulpotomy material could not be eliminated in this study.

As already mentioned, the findings of the present study suggest that biodentine and pulpotec can be used as substitutes to formocresol as pulpotomy medicaments. It however necessitates further clinical and histologic studies to be carried out with a longer follow up period to make definitive conclusions as the 6-month follow-up of patients as in our study is rather short for evaluating the outcome of pulpotomy and success rate. This study might provide a basis for further studies in this field with a long-term follow-up and more participants.

Conclusion

- The present study shows that the clinical and radiographic success rates of Biodentine and Pulpotec is similar to that of Formocresol for primary molars over a 6 month follow up period. Hence it can be concluded that Biodentine and Pulpotec can be used as reliable alternatives to Formocresol for the pulpotomy procedures in primary teeth.
- However, further *clinical* and *histologic* research is suggested, with a *longer follow up* period and a *larger sample size* to draw a definitive conclusion.

References

1. Godhi B. Effects of mineral trioxide aggregate and formocresol on vital pulp after pulpotomy of primary molars: An *in vivo* study; *Contemp Clin Dent.* 2011; 2(4):296-301
2. Ghajari MF. Comparison of pulpotomy with formocresol and MTA in primary molars: a systematic review and metaanalysis; *IEJ Summer* 2008; 3(3).
3. Sweet CA. Procedure for treatment of exposed and pulpless deciduous teeth. *J Am Dent Assoc.* 1930; 17:1150-53,
4. David R Myers. Tissue changes induced by the absorption of formocresol from pulpotomy sites in dogs; *Pediatr Dent*, 1983
5. Omar El-Meligy. Histological evaluation of electrosurgery and formocresol pulpotomy techniques in primary teeth in dogs; *The Journal of Clinical Pediatric Dentistry* 2001; 26(1).
6. Paula Jane Waterhouse. "New Age" Pulp Therapy: Personal Thoughts on a Hot Debate; *Pediatric dentistry v* 2008; 30(3).
7. BLewis B. Formaldehyde in dentistry: a review of mutagenic and carcinogenic potential; *JADA*, 1981, 103.
8. Huey-Wen Jeng. Comparison of the cytotoxicity of formocresol, formaldehyde, cresol, and glutaraldehyde using human pulp fibroblast cultures. *Pediatric dentistry.* 1987, 9
9. Zarzar PA. Formocresol mutagenicity following primary tooth pulp therapy: an *in vivo* study; *Journal of Dentistry* 2003; 31:479-485
10. Lewis B. The obsolescence of formocresol.- *Journal of*

the California Dental Association, 2010

11. Kakarla P. Dental pulp response to collagen and pulpoteccement as pulpotomy agents in primary dentition: A histological study. *J Conserv Dent.* 16:434-8.
12. Rajasekharan S, Biodentine TM. Material characteristics and clinical applications: a review of the literature *Eur Arch Paediatr Dent*, 2014.
13. Prajakta G. Biodentine: A Revolution in Conservative Dentistry & Endodontics - *Journal of Interdisciplinary Dental Sciences.* 2013; 2(1).
14. Gurudutt Nayak. Biodentine a novel dentinal substitute for single visit apexification, *Restor Dent Endod.* 2014; 39(2):120-125.
15. Harpreet Singh. Biodentine: A Promising Dentin substitute; *J Interdiscipl Med Dent Sci.* 2014; 2:5.
16. Sulaiman Mohamed Allazzam. Clinical Applications of Biodentine in Pediatric Dentistry: A Review of Literature, *Oral Hyg Health.* 2015, 3:3.
17. Naila S Farooq. Success rates of formocresol pulpotomy and indirect pulp therapy in the treatment of deep dentinal caries in primaryteeth, *Pediatric Dentistry.* 2000; 22:4.
18. Yeliz Guven. Success Rates of Pulpotomies in Primary Molars Using Calcium Silicate-Based Materials: A Randomized Control Trial, *Bio Med Research International*, 2017.
19. Guideline on Pulp Therapy for Primary and Immature Permanent Teeth AAPD Reference Manual. 2016; 37:6-15.
20. Elham Farrokh Gisoure, Comparison of Three Pulpotomy Agents in Primary Molars: A Randomised Clinical Trial, *Iran Endod J. Winter.* 2011; 6(1):11-14.
21. Esma Yildiz, Evaluation of formocresol, calcium hydroxide, ferric sulfate, and MTA primary molar pulpotomies, *Eur J Dent.* 2014; 8(2):234-240.
22. Zeyneb AA, Al- Dahan. Clinical and radiographical evaluation of pulpotomy in primary molars treated with Pulpotec (PD), Formocresoland Mineral Trioxide Aggregate (MTA), *J Bagh Coll**ege Dentistry.* 2013; 25(4).
23. Omar Abd El Sadek El *et al.* Comparison between biodentine and fromocresol for pulpotomy of primary teeth: A radomized clinical trial; *Qij.* 2016; 47(7).
24. Melekhov SV, Tairov VV. Results in the treatment of pulpitis in teeth by the pulpotomy method employing pulpotec: Proceedings of the Moscow Meeting of the Organisation of Dental Management Economics and Accounting, Krasnodar. 2005, 409-411.
25. Sunitha B. Clinical and Radiographic Evaluation of Four Different Pulpotomy Agents in Primary Molars: A Longitudinal Study. *Int J Clin Pediatr Dent.* 2017; 10(3):240-244.