



International Journal of Applied Dental Sciences

ISSN Print: 2394-7489
ISSN Online: 2394-7497
IJADS 2019; 5(1): 66-69
© 2019 IJADS
www.oraljournal.com
Received: 11-11-2018
Accepted: 14-12-2018

Dr. Ritesh Garg

Reader, Department, Oral and Maxillofacial Surgery, Institute of Dental Studies and Technologies, Modinagar, Ghaziabad, Uttar Pradesh, India

Dr. Abhishek Rathi

Senior Lecturer, Department, Oral and Maxillofacial Surgery, Institute of Dental Studies and Technologies, Modinagar, Ghaziabad, Uttar Pradesh, India

Dr. Gaurav Mittal

Head of Department, Department, Oral and Maxillofacial Surgery, Institute of Dental Studies and Technologies, Modinagar, Ghaziabad, Uttar Pradesh, India

Dr. Siddharth Sharma

Reader, Department, Oral and Maxillofacial Surgery, Institute of Dental Studies and Technologies, Modinagar, Ghaziabad, Uttar Pradesh, India

Dr. Anmol Agarwal

Reader, Department, Oral and Maxillofacial Surgery, Institute of Dental Studies and Technologies, Modinagar, Ghaziabad, Uttar Pradesh, India

Dr. Pratiksha Dwivedi

Post Graduate Student, Department, Oral and Maxillofacial Surgery, Institute of Dental Studies and Technologies, Modinagar, Ghaziabad, Uttar Pradesh, India

Correspondence

Dr. Pratiksha Dwivedi

Post Graduate Student, Department, Oral and Maxillofacial Surgery, Institute of Dental Studies and Technologies, Modinagar, Ghaziabad, Uttar Pradesh, India

Nasopalatine duct cyst: A case report

Dr. Ritesh Garg, Dr. Abhishek Rathi, Dr. Gaurav Mittal, Dr. Siddharth Sharma, Dr. Anmol Agarwal and Dr. Pratiksha Dwivedi

Abstract

The Nasopalatine duct cyst (NPDC) is an intraosseous, developmental, epithelial, non-neoplastic cyst that is considered to be the most common non-odontogenic cyst of the midline of the anterior palate. It is accounting for between 3 and 12% of operated cysts of the jaw with maximum incidences are seen in adult males. This cyst mainly develops from the epithelial remnants of the naso-palatine ducts within the incisive canals. Radiographically NPDC is well defined round or roughly heart shaped. Enucleation is preferred treatment plan for removal of NPDC. The presented report deals with diagnosis and management of NPDC in a 24 year old male who complained of swelling and pain in the anterior maxillary region.

Keywords: Nasopalatine duct cyst, epithelial remnants, radiographically, enucleation

Introduction

The nasopalatine duct cyst (NPDC) was first described by Meyer in 1914. When cyst occurs in the soft tissues of the palate, at the opening of the canal, it is called the 'cyst of the palatine papilla' [1-5]. The term 'nasopalatine duct cyst' is most popular than other synonyms such as 'incisive canal cyst', "anterior middle cyst", "anterior middle palatine cyst", and "incisor duct cyst" [6]. Nasopalatine duct cyst develops from the epithelial remnants of the oro-nasal ducts within the incisive canals. The majority of the cases occur between 4th and 6th decades of life. Men are affected more often than women – ratio 3:1. Nasopalatine cysts are believed to develop from epithelial remnants of paired embryonic nasopalatine ducts within the incisive canal. The etiological factors include local trauma in denture wearing patients, bacterial infection and genetic factors [1, 7].

Lesions are normally asymptomatic. Involvement of inflammation leads to palatine growth or expansion. The most commonly reported clinical symptom is swelling on the anterior part of the palate but in rare cases patients have complained burning sensation in the anterior part of the maxilla that occasionally radiates into the bridge of the nose and the orbits [1, 8].

The radiographic appearance of cysts of the incisive canal often consists of a round, bilateral symmetric radiolucency which is sometimes heart-shaped; because of the super-imposition of the nasal spine on the radiolucent area. The margin is corticated, provided infection has not developed [7].

The differential diagnosis must be established with other conditions such as an enlarged nasopalatine duct, central giant cell granuloma, a root cyst associated to the upper central incisors, a supernumerary tooth follicular cyst (normally mesiodens), primordial cyst, naso-alveolar cyst, osteitis with palatal fistulization, and bucco-nasal and/or bucco-sinusal communication [9].

Treatment of nasopalatine duct cyst includes complete removal of the lesion by combination of both palatal and labial approaches and only palatal or labial approach [10].

Case Report

A twenty four year old male patient reported with chief complaint of loosening of teeth in upper front region since one month. Physical examination revealed a moderately built and nourished male with mild hypertension. The swelling had remained asymptomatic. Neither any history of trauma was elicited nor any systemic infections. There was no history of any discharge.

On extra-oral examination no apparent finding or evidence of lesion were seen. On intra-oral examination there was diffuse non-tender solitary swelling was present on the anterior mid palatal region posterior to palatine papilla. The swelling was about 4x3 cm in size extended from 14 to 24 tooth region Figure 1(a). The swelling was non-compressible, hard in consistency, non-pulsatile, non-reducible, regular and covered by normal appearing mucosa with no fluctuation and sensation over palatine mucosa. No restricted tongue movements. Lymph nodes were not palpable. Mesial inclination of crown of both central incisors was present Figure 1(b).

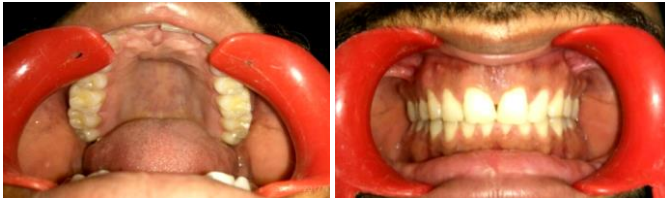


Fig 1(a): Intra oral photograph depicting cyst in mid palatal region
(b) frontal view

Maxillary occlusal view revealed a well-circumscribed unilocular radiolucency in anterior maxilla between central incisors which was round and measured 4 × 3 cm involving 13 to 23 region posterior to anterior nasal spine and has corticated margins. Superiorly it extends into palatal vault causing expansion and resorption of nasal floor (Figure 2). The shadow of nasal spine is superimposed on the radiolucency giving it a heart shape. There was divergence of the central incisors roots with no root resorption. Panoramic radiograph showed well defined corticated radiolucent lesion in anterior maxilla. The lesion is roughly heart-shaped. It extends from root of canine crossing the midline to mesial aspect of roots of left premolar. There was distal displacement of the roots of central incisors associated with radiolucency.

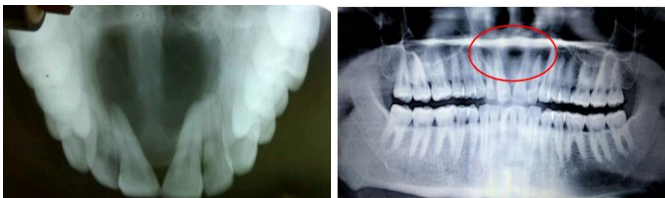

Fig 2: Maxillary occlusal view and ortho pantomograph showing a well-defined roughly heart shaped radiolucent lesion

Routine hemogram and urine examination were normal. On the basis of clinical and radiological examination a provisional diagnosis of nasopalatine duct cyst was made. Complete blood examination revealed no abnormality.

Treatment

The possibility of tooth avulsion or extractions of incisors were explained to the patient, and informed consent was obtained. Enucleation of the lesion followed by aggressive curettage was performed under general anesthesia. Endodontic therapy was previously performed with respect to 11,12,21,22 and 23. Intraorally crevicular incision was given on anterior maxillary region from 14 to 24. Mucoperiosteal trapezoidal flap was raised. Cystic lining was enucleated followed by careful and thorough curettage of the residual bone cavity. Apicoectomy of respective teeth 11, 21, 22 and 23 were done. Mineral trioxide aggregate was placed in the root apices. Absorbable gelatin sponge (ABGEL) was packed

inside bony cavity. Surgical site was closed with vicryl by placing interpapillary sutures (Figure 3& 4). The specimen was sent for histopathological examination.

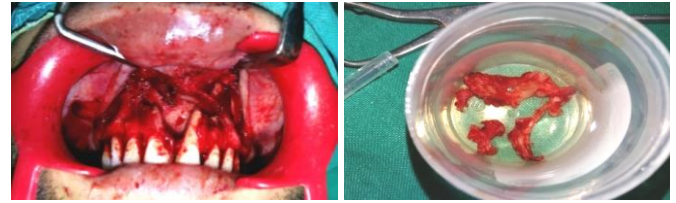


Fig 3(a): Raised flap and b) Excised specimen

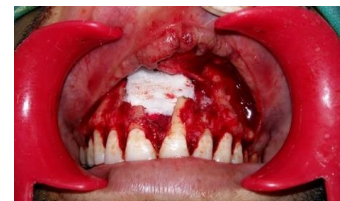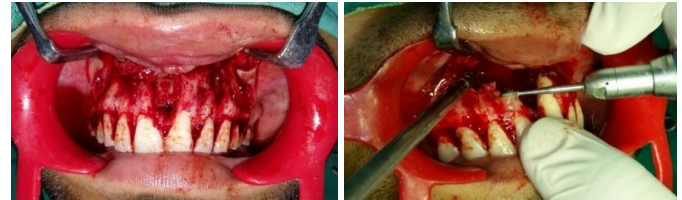


Fig 4(a): Enucleation of cyst b) Apicoectomy c) Cavity filled with Ab-gel

Discussion

According to the classification of the World Health Organization (WHO) it is regarded as one of the commonest type of fissural, non-odontogenic, intraosseous, developmental, epithelial, non-neoplastic cyst in the incisive canal at the midline of the anterior palate including or non-including palatine papilla is called a nasopalatine duct cyst. It is accounting for between 3 and 12% of operated cysts of the jaw. Adults are more affected than children with higher incidence among males than females^[9, 11-13]. However it has been suggested that in young African Caribbean's, NPDC appears to be more clinically aggressive with larger and symptomatic lesions than in other ethnic groups^[14].

Many authors suggest a spontaneous proliferation theory for NPDCs' origin. Previously they were considered as fissural cysts, originated from the epithelium trapped during the fusion of embryological process, but this concept has been discarded⁷. Now many authors suggest that NPDCs develop from the epithelial remnants of the oro-nasal ducts (nasopalatine ducts) within the incisive canals that are a communication through the bone into the hard palate linking the oral and nasal passages^[1, 15, 16]. The incisive canal also contains blood vessels, nerves and glandular structures. Epithelium from Jacobson's organs that are located at the base of the nasal septum or in the roof of the mouth has also been proposed as a possible cause of cysts^[12].

The stimulus for cyst formation from the epithelial remnants of the nasopalatine canal is uncertain. Local trauma during mastication or ill fitting dentures, bacterial infection, spontaneous proliferation and blockage of glandular ducts as well as racial or genetic factors are possible causes^[1].

Study shows that 87% of the cases are asymptomatic and found only during routine clinical and radiographic examination^[17]. The cyst may produce bulging of the floor of the nose or sometimes communication with the nasal cavity.

Usually patients complain of a small asymptomatic swelling just posterior to palatine papilla, as happened in above mentioned case. In rare cases, the swelling is associated with a burning sensation probably due to pressure on sphenopalatine nerve [23]. Pain is not a frequent complaint but it can be due to pressure on the nasopalatine nerves or if the cyst becomes secondarily infected [5]. Drainage may be mucoid, in which the patients describe a salty taste, or it may be purulent. Patients may complain of a foul taste, periodontally compromised tooth, nasal obstruction, or discharge into the nasal cavity or oral cavity [18-23]. The vitality of nearby teeth due to performed endodontic therapy as in above reported case all maxillary incisors were undergone through root canal treatment. Root resorption though uncommon has been reported [24].

Radiographically, nasopalatine ducts cysts are usually well-circumscribed round, ovoid, or heart-shaped radiolucency of the anterior maxilla, apical to the roots of the maxillary incisors. Heart shape due to the superimposition of the nasal spine [16, 18]. The clinician may have some difficulty in distinguishing between a large incisive foramen and a small asymptomatic incisive canal cyst on the basis of radiographic evidence alone. Some studies say that radiolucency of the incisive canal measuring less than 0.6 cm in diameter should not be considered cystic in the absence of other symptoms [5, 25]. Cysts range in size, with an average diameter of approximately 1.5 cm and incisive foramen is not expected to exceed 6 mm in diameter. The absence of the lamina dura and enlargement of the periodontal space around the apex of the central incisor indicates an inflammatory lesion. Resorption of bone is more common than expansion of bone. In above reported case, the cyst had completely eroded the buccal bone plate. Nasopalatine duct cyst should be differentiated from the normal nasopalatine fossa. Shear and Speight have reported that the mean size of the nasopalatine fossa was as high as 10.19 + 3.24 mm antero-posteriorly and 4.79 + 1.33 mm in width [24].

The differential diagnosis should be established with the following conditions such as lateral radicular cyst, lateral periodontal cyst, odontogenic keratocyst, ameloblastoma, odontogenic myxoma, central giant tumor, brown tumor of hyperparathyroidism, central hemangioma. A thorough differential diagnosis must be established in order to avoid unnecessary endodontic procedures in vital permanent upper central incisors [26, 27].

The treatment of choice is enucleation to avoid relapse and postoperative long term follow-up is essential. Marsupialization is considered in large lesions followed by second stage enucleation [16, 21, 22, 28-30]. According to some studies recurrence rate is low and ranges from 0% to 11%. When branches of nasopalatine nerve are removed during surgery, paraesthesia of anterior palate may occur [9, 18, 31, 32]. Palatal approach along with autogenous bone graft has also been done in reported literature [9, 33]. Post-operatively extensive radiological investigation shows complete bone regeneration in a high proportion of cases. The incisive canal had probably been eliminated or become so minute that it cannot be seen on the X-ray films [34]. Bodin, Isaacson, and Julin advised for surgical exploration if the size of the radiolucency exceeds 8 mm, or if it shows asymmetric bulging [18, 24]. Small considered that surgery should not be undertaken until the radiolucency of the suspected cyst has reached a diameter > 6 mm and/or until symptoms appear [2].

Different treatment modalities of anterior maxillary swelling have been recommended. Ficarra *et al.* proposed the treatment

as complete enucleation and fixation of the surrounding bone with Carnoy's solution. Bhatt *et al.* proposed conservative treatment [35, 36]. In our case we performed complete enucleation and packing of bony cavity with Ab-gel.

Absorbable gelatin sponge (Ab-gel) can be placed dry or after moistening it with saline or thrombin, conforms easily to wounds making and reported to induce a better quality clot than other cellulose products [37, 38].

Conclusion

Nasopalatine duct cysts are the most common nonodontogenic cyst of the oral cavity seen in the general population and must be distinguished from other maxillary anterior radiolucency on the basis of clinical and radiographic examinations. Vitality test of teeth adjacent to cyst-like lesion is mandatory and the final diagnosis could only be decided after histopathological analysis. The treatment of choice is surgical exeresis of the cyst, although some authors propose Marsupialization of large NPDCs followed by enucleation.

References

1. Meyer AW. A unique paranasal sinus directly above the superior incisors. *Journal of Anatomy*, 1914, 48.
2. Small EW. Cysts. *Dental Clinics of North America*. 1971; 15:369-398.
3. Abrams AM, Howell FV, Bullock WK. Nasopalatine cysts. *Oral Surgery, Oral Medicine, Oral Pathology*, 1963.
4. Robertson H, Palacios E. Nasopalatine duct cyst. *Ear Nose Throat J*. 2004; 83(5):313.
5. Soames JV, Southam JC. *Oral pathology*. 4th ed. New York: Oxford, 2005, 78-98
6. Berlove IJ. Anterior Median palatine cyst. *New York State Dental Journal*. 1956; 26:381-384.
7. Staretz L, Brian B. Well defined radiolucent lesion in the maxillary anterior region. *J Am Dent Assoc*. 1990; 120:335-6.
8. Vasconcelos RF, Ferrerira de Aguiar, Castro WH, Cavalcanti de Araujo V, Mesquita RA. Retrospective analysis of 31 cases of nasopalatine duct cyst. *Oral Disease*. 1999; 5:325-328.
9. Escoda Francolí J, Almendros Marqués N, Berini Aytés L, Gay Escoda C. Nasopalatine duct cyst: Report of 22 cases and review of the literature. *Med Oral Patol Oral Cir Bucal*. 2008; 13(7):E438-43.
10. Tanaka S, Iida S, Murakami S *et al.* Extensive nasopalatine duct cyst causing nasolabial protrusion. *Oral Surg Oral Med Oral Pathol Oral Radiol Endod*. 2008; 106:46Y50
11. Bone R. Cystic lesions of the maxilla. *Laryngoscope*. 1972; 82:308-320.
12. Das A, Koley DL. Fissural cysts of the palate. *J. Ind. Dent. Assoc*. 1970; 42:169-172.
13. Killey H, Kay LW. *Benign cystic lesions of the jaws*. 2nd ed. E. & S. Livingstone, Edinburgh and London, 1972.
14. Nortje CJ, Forman AG. Nasopalatine duct cyst: an aggressive condition in adolescent Negroes from South Africa? *Int J Oral Surg*. 1978; 7:65-72.
15. Allard RHB, Van Der Kwast WA, Van Der Waal I. Nasopalatine duct cyst: review of the literature and report of 22 cases. *International Journal of Oral surgery*. 1981; 10:447-461.
16. Anneroth G, Hall G, Sturge U. Nasopalatine duct cyst *Journal of Oral and Maxillofacial Surgery*. 1986; 15:527-580.

17. Vasconcelos RF, Aguiar MC, Castro WH, Araújo V, Mesquita RA. Retrospective analysis of 31 cases of nasopalatine ductcyst. *Oral Dis.* 1999; 5:325-8.
18. Bodin I, Isacson G, Julin P. Cysts of the nasopalatine duct. *Int J Oral Maxillofac Surg.* 1986; 15:696-706.
19. Krishna J, Kumar P, Aaisha S. Nasopalatine cyst: a rare entity. *Int J Dent Clin.* 2010; 2:34-6.
20. Chen A, Coelho P, Sousa D, Caramês J. Unusual growth of anasopalatine cyst. *Rev Port Estomatol Med Dent Cir Maxilofac.* 2011; 52:35-8.
21. Saunders LA, Wisniewski H, Soumerai S. Extensive incisivecanal cyst. *Oral Surg Oral Med Oral Pathol.* 1968; 26:284-90.
22. Schiff BS, Kringstein G, Stoopack JC. Na extremely large and facially distorting nasopalatine duct cyst. *Oral Surg Oral Med Oral Pathol.* 1969; 27:590-4.
23. Campbell JJ, Baden E, Williams AC. Nasopalatine cyst of unusual size. Report of a case. *J Oral Surg.* 1973; 31:776-9.
24. Shear M, Speight P. Cysts of the Oral and Maxillofacial Regions. 4th ed. Oxford, Blackwell Publishing Ltd, 2007, 108-18.
25. Cawson RA, Odell EW. Cawson's essentials of oral pathology and oral medicine. 7th ed. London: Churchill Livingstone, 2002, 116-7.
26. Francoli JS, Marques NA, Aytis LB, Escoda CG. Nasopalatine duct: report of 22 cases and review of literature. *Med Oral Patol Oral Cir Bucal.* 2008; 13(7):E438-E443
27. Gnanasekhar JD, Walvekar SV, Al-kandari AM, Al-Duwairi Y. Misdiagnosis and mismanagement of nasopalatine duct cyst and its corrective therapy. A case report. *Oral Surg Oral Med Oral Pathol Oral Radiol Endod.* 1995; 80(1):465-470
28. Regezi JA, Sciubba JJ, Jordan RCK. Oral pathology clinical pathologic correlations. 4th ed. Missouri: Saunders, 2003, 256-7
29. Curtin HD, Wolf P, Gallia L, May M. Unusually large nasopalatine cyst: CT findings. *J Comput Assist Tomogr.* 1984; 8:139-42.
30. Tainter JF, Fahid A. Case report: median palatine cyst. *Dent Surg.* 1977; 53:33-6
31. Swanson KS, Kaugars GE, Gunsolley JC. Nasopalatine duct cyst: an analysis of 334 cases. *J Oral Maxillofac Surg.* 1991; 49:268-71.
32. Elliot KA, Franzese CB, Pitman KT. Diagnosis and surgical management of nasopalatine duct cysts. *Laryngoscope.* 2004; 114:1336-40.
33. Tsuneki M, Maruyama S, Yamazaki M, Abé T, Adeola HA, Cheng J *et al.* Inflammatory histo-pathogenesis of nasopalatine duct cyst: A clinic-pathological study of 41 cases. *Oral Dis.* 2013; 19:415-24.
34. Borg, G, Persson G, Thllander H. A study of odontogenic cysts with special reference to comparisons between keratinizing and non-keratinizing cysts. *Swecl. Dent. J.* 1974; 67:311-325.
35. Ficarra G, Chou L, Panzoni E. Glandular odontogenic cyst (sialo-odontogenic cyst) *Int. J Oral Maxillofac. Surg.* 1990; 19(6):331-333.
36. Bhatt V, Monaghan A, Brown AM, Rippin JW. Does the glandular odontogenic cyst require aggressive management? *Oral Surg. Oral Med. Oral Pathol. Oral Radiol. Endod.* 2001; 92(3):249-251.
37. Spotnitz WD, Burks S. Hemostats, sealants, and adhesives: Components of the surgical toolbox. *Transfusion* 2008; 48(7):1502-16.
38. Szpalski M, Gunzburg R, Sztern B. An overview of blood-sparing techniques used in spine surgery during the perioperative period. *Eur Spine J* 2004; 13(1):S18-27.