



ISSN Print: 2394-7489
ISSN Online: 2394-7497
IJADS 2019; 5(1): 99-106
© 2019 IJADS
www.oraljournal.com
Received: 16-11-2018
Accepted: 20-12-2018

Dr. Renu Gupta
Professor and Head,
Department of Prosthodontics &
Crown and Bridge, H. P Govt.
Dental College, Shimla, Himachal
Pradesh, India

Dr. RP Luthra
Professor and Head,
Dept. of Dentistry, Dr Y.S. Parmar
Medical College and Hospital,
Nahan, Himachal Pradesh, India

Dr. Dapinder Kaur
Junior Resident,
Department of Prosthodontics &
Crown and Bridge, H. P Govt.
Dental College, Shimla, Himachal
Pradesh, India

Dr. Hardik Hitesh Sheth
Junior Resident,
Department of Prosthodontics &
Crown and Bridge, H. P Govt.
Dental College, Shimla, Himachal
Pradesh, India

Dr. Abhay Sharma
Junior Resident,
Department of Prosthodontics &
Crown and Bridge, H. P Govt.
Dental College, Shimla, Himachal
Pradesh, India

Dr. Palak Dudeja
MDS, Private Practitioner,
Sonapat, Haryana, India

Dr. Hitesh Shah
Private Practitioner,
Shah Dental Care, Kolkata,
West Bengal, India

Dr. Neha Sharma
B.D.S. (Bhojia Dental College and
Hospital, Nalagarh, Himachal
Pradesh, India

Correspondence

Dr. Dapinder Kaur
Junior Resident,
Department of Prosthodontics &
Crown and Bridge, H. P Govt.
Dental College, Shimla, Himachal
Pradesh, India

A novel way to place short implants using platelet-rich fibrin (PRF): An original research

Dr. Renu Gupta, Dr. RP Luthra, Dr. Dapinder Kaur, Dr. Hardik Hitesh Sheth, Dr. Abhay Sharma, Dr. Palak Dudeja, Dr. Hitesh Shah and Dr. Neha Sharma

Abstract

Aim: The purpose of this study was to evaluate the effects of PRF application on short implant both clinically and radiologically.

Methodology: A total of fifteen short implants coated with PRF were placed in periodontally healthy patients who were above 18 years of age. All the patients were informed about the purpose of study and consent was taken. They were followed up for a period of 6 months.

Results: Results showed gain in crestal bone levels along with no adverse complications.

Conclusion: It was concluded that the use of PRF along with short implants is an important adjunct in implantology as it accelerates the soft and hard tissue healing around the implant without performing any extensive surgery in deficient bone height and contributes to the overall success of implants.

Keywords: PRF, healing, short, implants

Introduction

Osseointegrated dental implants have been considered the most aesthetic and functional alternative to missing teeth. The success rate in patients treated with dental implants is high for all implant systems, varying according to prospective and retrospective studies from 85 to 100%^[1].

Over the years, various strategies have been proposed to overcome the dimensional limitations of the bone available for implant placement^[2]. Short implants (>6mm to <10mm)^[3] have been proposed as an alternative choice for the prosthetic treatment of atrophic alveolar ridges, which may provide surgical advantages including reducing morbidity, treatment time, and costs^[2,4].

The biomechanical rationale behind the use of short implants is that the crestal portion of the implant body is the most involved in load-bearing, whereas very little stress is transferred to the apical portion^[2]. The different biomechanical studies addressed that maximum bone stress is practically independent of implant length and that even implant width is more important than additional length.

Platelet-rich fibrin (PRF) is a second generation autologous platelet concentrate and is a fibrin mesh consisting of leukocytes and cytokines.^{5,6,7,8,9,10} It activates the vascular system and angiogenesis and releases high amounts of growth factors like transforming growth factor- β 1, platelet-derived growth factor AB (PDGF-AB), insulin like growth factor (IGF), vascular endothelial growth factor (VEGF), and matrix glycoprotein such as thrombospondin-1^[8,9] during at least 7 days in vitro, which are involved in soft tissue and hard tissue healing^[5,7,11,12] PDGF and IGF are well known osteogenic cytokines^[11].

This biomaterial presents a specific biology which offers several advantages including promoting wound healing, bone growth and maturation, graft stabilization, wound sealing and hemostasis, and improving the handling properties of graft materials. Since no previous study has been conducted with short implants and PRF application, therefore, the aim of the present *in vivo* study was to evaluate short implants coated with PRF both clinically and radiologically.

Materials and Methods

An *in vivo* study was conducted in the Department of Prosthodontics, Crown and Bridge and Oral Implantology, H. P. Government Dental College and Hospital, Shimla, Himachal Pradesh. A total of fifteen short implants coated with PRF were placed in periodontally healthy patients who were above 18 years of age. All the patients were informed about the purpose of study and consent was taken.

Presurgical Assessment

A detailed medical and dental history of each subject was obtained along with preoperative photographs and radiographs. All vital signs were checked and a complete hemogram was done to evaluate the fitness of the patient prior to implant placement. The surgical area selected for dental implant placement was evaluated clinically for width and to assess for any deep undercuts. CBCT was used to accurately evaluate the amount of bone and proximity from vital structures for each patient. A complete oral prophylaxis along with prescription of 0.2% chlorhexidine gluconate mouth rinse, twice daily for a period of 15 days before dental implant placement was advised. All subjects were motivated to maintain oral hygiene.

Fabrication of Study Models and Surgical Stent

Preliminary alginate impressions were made and study models fabricated prior to surgery. A diagnostic wax-up of the involved tooth was made and a surgical stent was fabricated based on the wax-up to facilitate implant placement.

Fabrication of the Vinyl Polysiloxane Jig

A Polysiloxane putty jig was fabricated to standardize the radiographic film holder (Rinn XCP) for each subject, in terms of, angulations and position of the film relative to the X-ray beam. Vinyl Polysiloxane Putty was mixed and attached to film holder. The film holder was seated into subject's mouth at a correct angulation and subject was instructed to bite on putty to get indentation of maxillary teeth. Then, this occlusal jig was used to take radiographs at subsequent visits during the follow-up visits to measure/assess bone level changes.

Procedure for taking IOPA Radiograph

The periapical radiographs were made with the long cone paralleling technique with radiographic film holders (Rinn XCP) using putty jig for the standardization of the projection & film placement to take radiographs at subsequent visits during the follow-up visits.

Preparation of Platelet Rich Fibrin ^[13-15]

10 ml of blood was withdrawn from venous peripheral vein and collected in sterile glass tube without any anticoagulant; immediately centrifuged at 3000 rpm for 10-12 minutes (without any delay).

Placement of Platelet Rich Fibrin

After preparation of PRF clot, it was transferred to PRF box; compressed with piston and serum was collected and transferred to syringe. After osteotomy site preparation, it was rinsed with serum and gelatinous PRF was placed inside it. Finally implant was placed in osteotomy site.

Implant Placement Procedure

Crestal incision was given for full thickness flap reflection, to expose the implant site.

Surgical stent was then placed over the crest to mark the implant site. The implant site was penetrated with the help of a pilot drill which was used to create a bleeding point and site of initial osteotomy when the surgical stent was still in place.

After marking the implant site by surgical stent, the surgical stent was removed and pilot drill was used to complete depth, followed by subsequent drills of increasing diameter to create an osteotomy site of required dimensions for each patient. A paralleling pin was used during osteotomy preparation to assess drill orientation. After the preparation of osteotomy site, it was rinsed with PRF serum obtained during compression of fibrin clot and finally PRF membrane was placed. Implants were then inserted into this osteotomy site with the help of a torque wrench.

Healing abutments were then screwed onto the implants and after thorough irrigation the implant site sutured with non-resorbable 3-0 silk sutures to achieve water-tight closure. The patients were prescribed with antibiotics and analgesics for 1 week, post-operatively. After 2 months, early loading of implant was carried out.

Impression Making and Prosthesis Fabrication

After abutment placement, the transfer cap was placed on the abutment and the impression was made by polyvinylsiloxane material using indirect impression technique. After applying gingival mask, Impression was then poured in die stone to fabricate the cast. After cast fabrication die preparation was done and wax pattern fabricated. A metal casting was then fabricated from investing and casting of this wax pattern. Metal try in was then made followed by shade selection. Final prosthesis was fabricated and then tried in patient's mouth and occlusion adjusted, after final trial the prosthesis was cemented with the help of Type I Glass Ionomer Cement (Luting).

Follow up

Any implant that was removed or failed to osseointegrate was designated as a failed implant. Prosthetic complications such as abutment screw loosening were noted. Patient's perception of pain was evaluated using a 0 to 10 numbered scale, 0 corresponding to no pain at all, and 10 as the maximum pain imaginable. Patient's entire experience with the procedure was also evaluated by a numbered scale after loading.

The patient was then recalled for follow up for radiographic evaluation which was made at 3 months and 6 months of implant placement for evaluation of crestal bone changes with help of radiographs.

The measurements were recorded at:

1. Immediate post-operative
2. 3 months following dental implant placement
3. 6 months following dental implant placement

The standardized periapical radiographs were obtained at immediate post-operative, 3 months and 6 months were digitized using Digimizer Image analysis.

The known implant length was used to calibrate the images in the computer software.

To measure radiologic changes in periimplant bone level, a fixed reference point had to be selected. The shoulder of the implant was taken as the reference point in the study. The distance from the point to the crest of the bone where it contacted the implant on mesial and distal sides was measured. The first point was selected on the shoulder of the implant. The second point was measured on the crest of the bone where it contacted the bone. The distance between the

points was displayed. On each recall the distance was measured and changes in crestal bone levels were analysed. Perimplant area was also checked for radiolucency, if any.

Results and Discussion

Peri-implant bone healing begins with the formation of a fibrin scaffold. Platelets adhere to this fibrin and are activated through the implant surface. Activated platelets release growth factors locally (eg, bone morphogenetic proteins, platelet-derived growth factor [PDGF], insulin like growth factor, vascular endothelial growth factor, transforming growth factor- β 1 [TGF- β 1], and TGF- β 2 that accelerate the healing process by attracting undifferentiated mesenchymal cells to the injured site Therapeutic applications of platelet-rich products have led to improved bone regeneration and faster titanium implant osseointegration, which improve the stability and maintenance of dental implants by increasing BIC.

Studies have shown that the application of growth factors via platelet-rich plasma (PRP), platelet-rich fibrin (PRF), or plasma rich in growth factors (PRGF) in the treatment of intrabony defects with or without bone grafts may lead to faster healing rates and enhanced bone formation.

Short dental implant placement is an alternative treatment modality to bone grafting procedures. Moreover, short implants may present results similar to those of longer implants. An implant is considered as short when presenting a length smaller than 10 mm. Accordingly, in clinical situations with little bone availability, short implants are a viable, simple, and predictable alternative [16].

Since PRF application reduces osseointegration time, early loading was preferred [5].

Thus, the purpose of this study was to evaluate the effects of PRF application on short implant both clinically and radiologically.

The first aim of this study was to clinically evaluate mobility of short implants.

Results showed zero mobility in all the subjects during the follow up periods which is an indication of the stability of the short implant coated with PRF.

This result can be attributed to the therapeutic applications of platelet-rich products had led to improved bone regeneration and faster titanium implant osseointegration, which improved the stability. These results are in accordance with the previously conducted studies [5, 17-23]

The second aim of this study was to evaluate clinical attachment level.

The results showed clinical attachment level 1.17 ± 0.36 mm over period of 3 months after the placement and 1.53 ± 0.48 mm at the end of 6 months. No loss in attachment was observed. There was no significant difference among different gender and implant width but clinical attachment level was found to be statistically significant ($p < 0.05$) in implant length 9.5 mm at the end of 3 months with value 1.36 ± 0.48 mm.

There is sufficient evidence from the literature which advocates this result.

The cytokines which are present in platelet concentrates play an important role in wound healing. PRF also favours the development of microvascularization leading to a more efficient cell migration [19, 20, 21].

The third aim of this study was to evaluate the clinically visible plaque accumulation.

The results showed mean plaque index 0.93 ± 0.59 at 3 months and 0.73 ± 0.59 at 6 months. The plaque index was statistically insignificant both at 3 and 6 months among different gender, implant length and implant width. But the overall mean decreased between 3 and 6 months, depicting the good oral hygiene status of the subjects.

The fourth aim was to radiologically evaluate crestal bone changes.

The mean values showed an increase in crestal bone level of -0.35 ± 0.43 and -0.25 ± 0.54 over a period of 6 months at mesial and distal sides of implants respectively. Irrespective of implant length and width, a statistically significant (p value < 0.05) crestal bone levels were observed among females at 3 and 6 months mesially and at 3 months distally in comparison to males. Although crestal bone changes were insignificant among all over different time intervals. All these results suggests optimum health of implant [17].

In this study the gain in crestal bone level was observed which may be result of the fact that PRF expressed many growth factors that promote and enhances both soft and hard tissue repair [5, 18-22].

Felipe Fredes *et al* (2017) [24] studied the potential effect of leukocyte-platelet rich fibrin in bone healing of skull base and suggested that L-PRF may induce bone healing and regeneration at the surgical site defect. Wang *et al* (2017) [25] also found platelet concentrate without the use of anti-coagulants (PRF) was able to more remarkably influence osteoblast behaviour by influencing the migration, proliferation and differentiation of human osteoblasts. All these studies support the present result.

The fifth aim of this study was to evaluate peri-implant area radiologically.

The results showed all the implants were osseointegrated without any radiolucency irrespective of gender, implant length and width, which indicated the success of the implant in all the stages and during all the follow ups. This result can be also be attributed to the therapeutic applications of platelet-rich products which had led to improved bone regeneration [5, 18-22]

The sixth aim of this study was to evaluate clinically persistent pain, dysesthesia or paraesthesia in implant region.

Since all the implants osseointegrated without any uneventful healing, the interviews conducted showed no such complain by the patient.

The seventh aim was to evaluate peri-implant infection with or without suppuration.

The results show that all the implants were properly healed without any incident of perimplantitis or suppuration. This indicates the optimum health of the implant [17].

This result is supported by fact that platelets promote wound healing and also have many features that indicate their role in the anti-infective host defense.

The eighth aim was to evaluate clinically bleeding on probing and sulcus probing depth.

The results showed mean probing depth 1.60 ± 0.51 mm and bleeding on probing 0.0 ± 0.00 at the end of six months. There was no significant difference between 3 and 6 months in all the subjects.

This can be attributed to the patient motivation for oral hygiene and also individual excellence at it [24, 25] Also, the cytokines which are present in platelet concentrates play an important role in wound healing. PRF also favors the development of microvascularization leading to more efficient cell migration [19, 20, 21].

The ninth aim was to find out immediate postoperative complication, if any.

The results show that there was no immediate postoperative complication. This can be attributed the proper surgical protocol followed for the technique. Also due to accelerated healing and anti- infectious properties of PRF [5, 18-22]

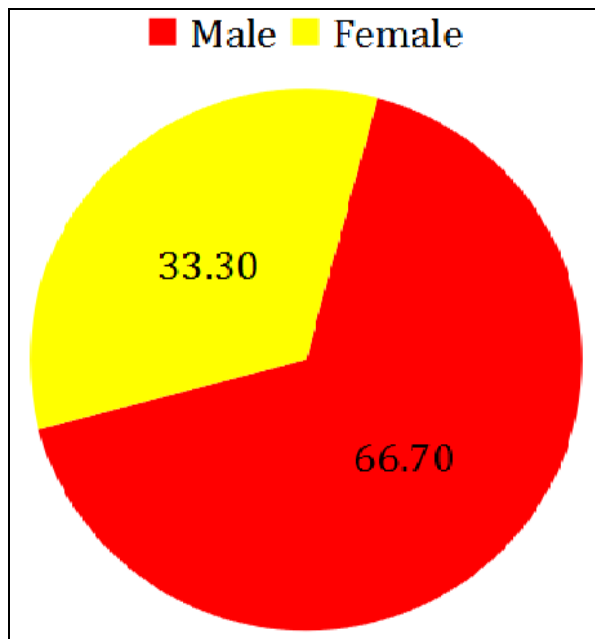
To the author’s knowledge, no study has been conducted with short implants and PRF. The various results show that this study fulfills the success criteria of implant [17].

All cases were successful; there were no intra-operative and post-operative complications. All implants achieved good osseointegration. These results were obtained by accurately managing the immediate and late postoperative period in all of the treated patients. All patients underwent uneventful implant surgery. All implants were placed according to the surgical protocol, manufacturer’s instructions and achieved primary stability. No intra-operative surgical complications were recorded. Particular attention was paid to oral hygiene.

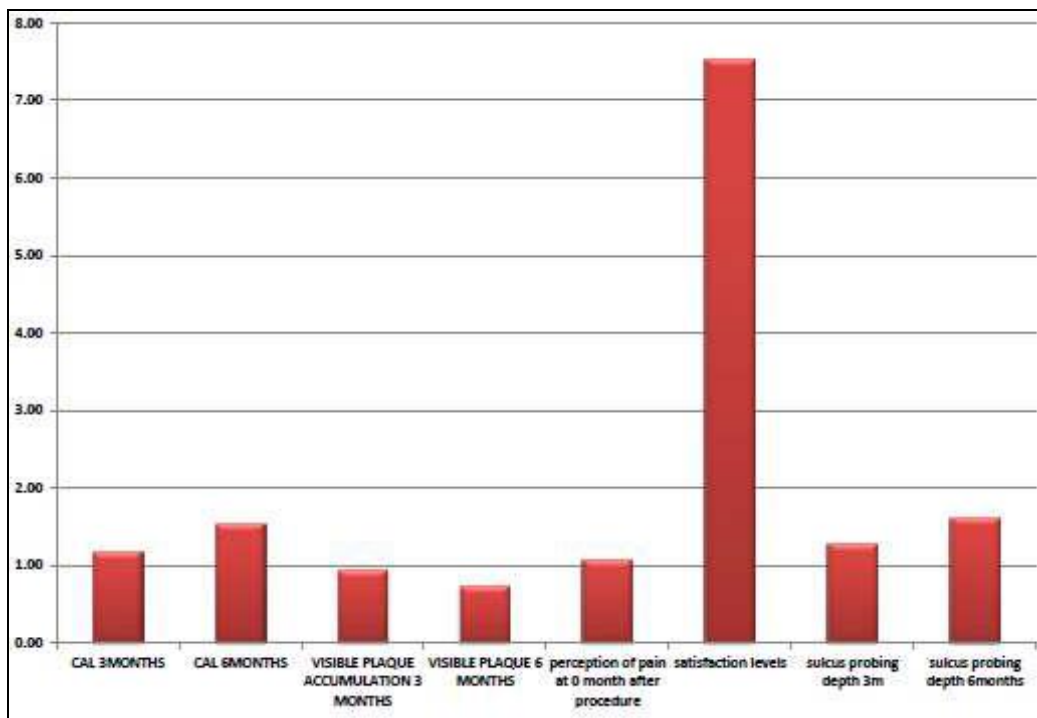
The drawbacks of this study included the fact that in this study, intra-oral radiography was used to evaluate the radiologic changes in peri-implant bone level, which is quite a sensitive method. However, it should be noted that this technique could only record bone level in two dimensions

(mesial and distal). Therefore, it is highly likely that some information (bone loss in the buccal and lingual dimensions) might be missing, although enough data can be recorded for clinical follow up and diagnostic procedures. Currently, new diagnostic radiographic methods such as cone beam computed tomography (CBCT) are more reliable for scientific studies and evaluations, but due to lack of patient co-operation and absence of relevant infrastructure we had to use intraoral radiography. Other limitations of the study were the small sample size.

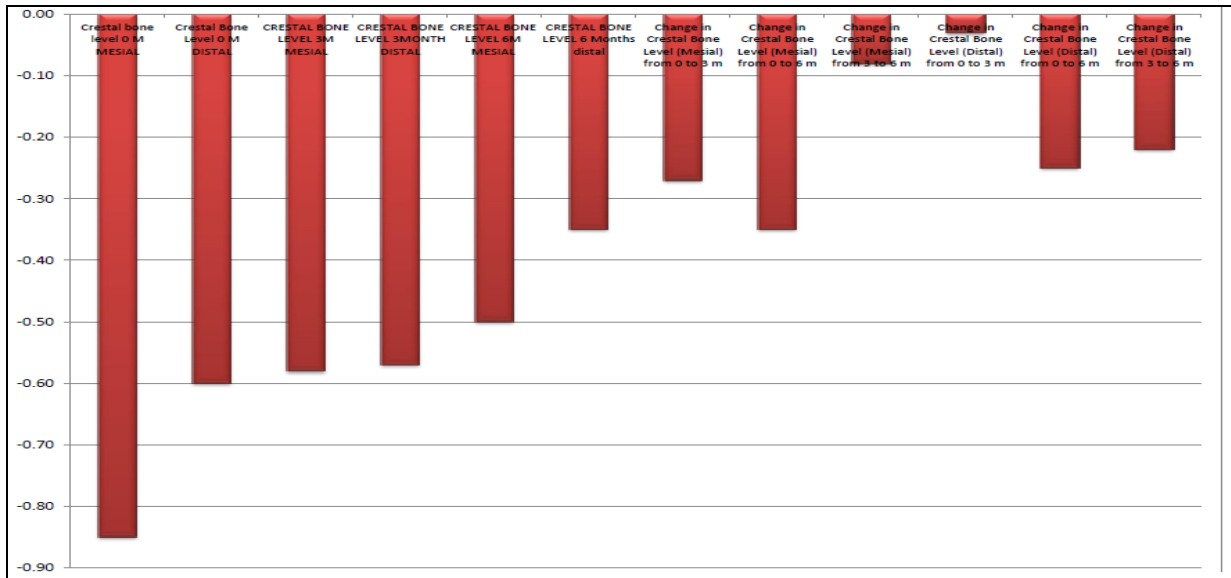
Although the initial results are promising, there is a further need to evaluate these implants for longer periods.



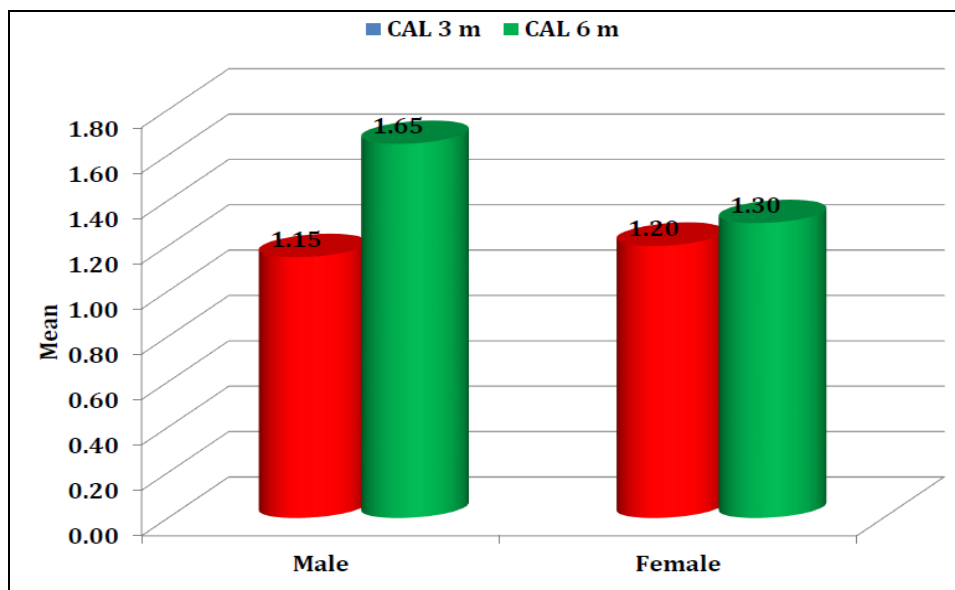
Graph 1: Gender distribution



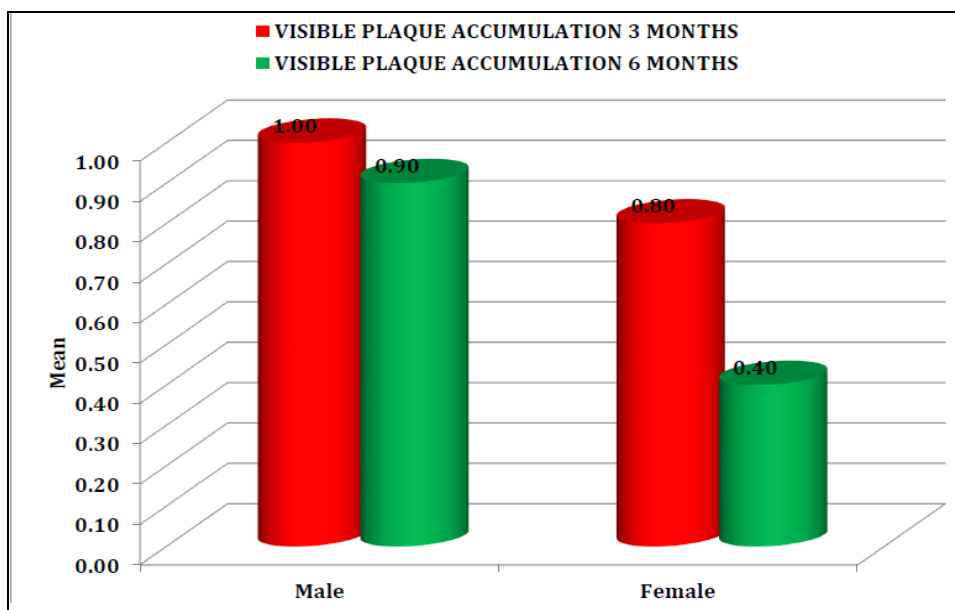
Graph 2: Descriptive table for all cases



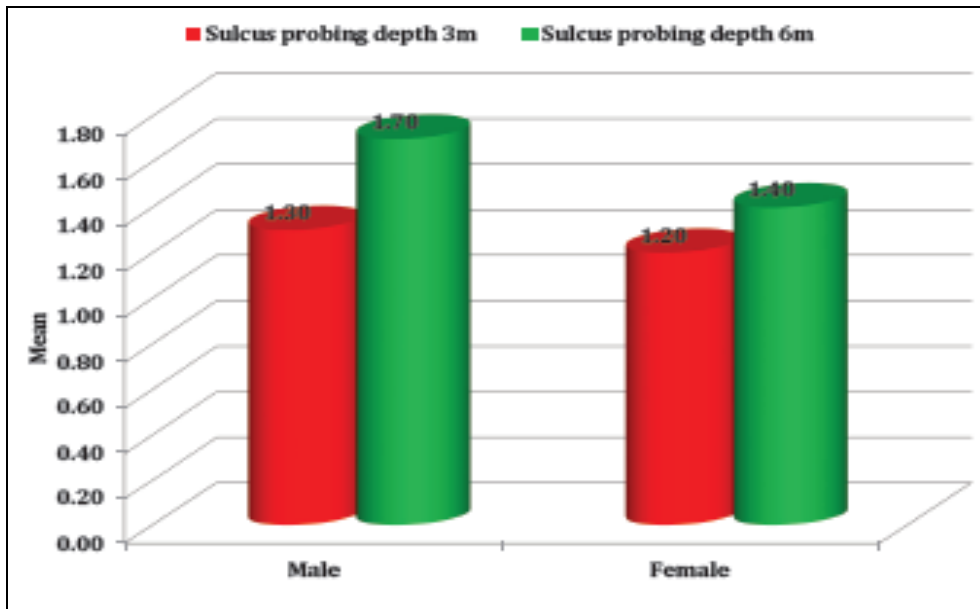
Graph 3: Descriptive table for all cases (n = 15)



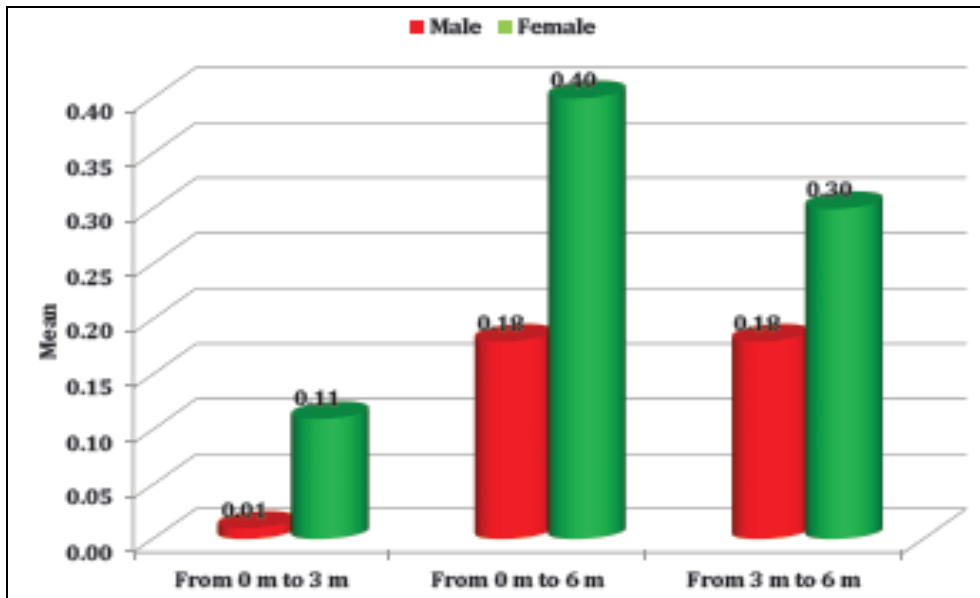
Graph 4: Clinical attachment at different time intervals



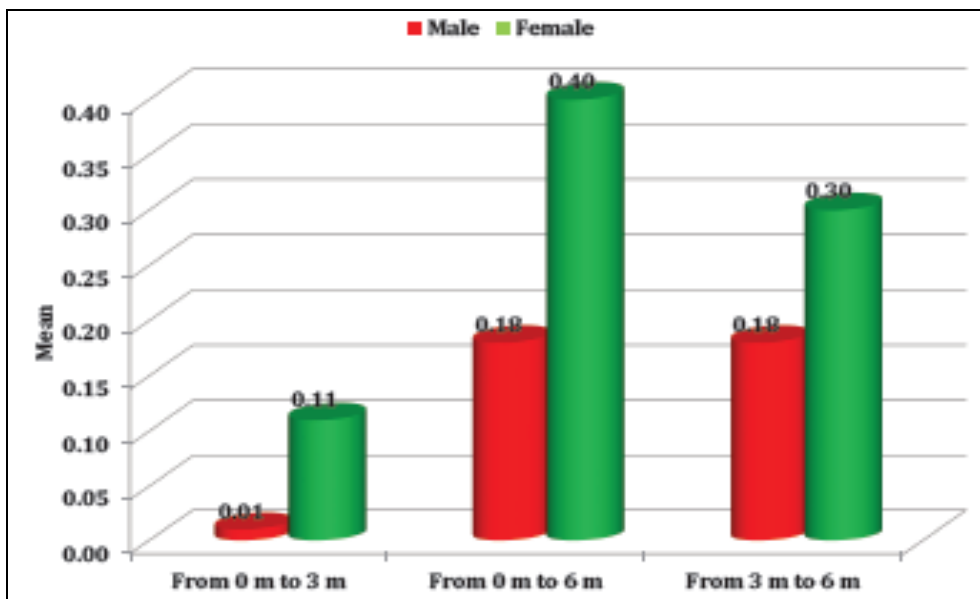
Graph 5: Visible plaque accumulation at different time intervals



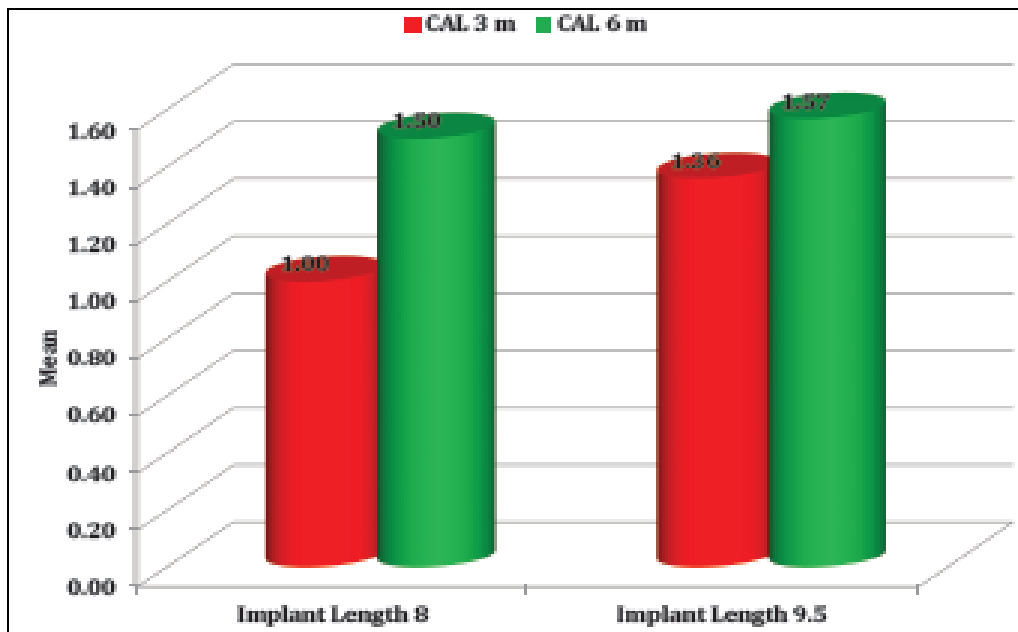
Graph 6: Comparison of sulcus probing depth at different time intervals



Graph 7. Comparison of change in crestal bone level (Mesial) at different time intervals



Graph 8. Comparison of change in crestal bone level (Distal) at different time intervals



Graph 9. Clinical attachment at different time intervals

Conclusion

Platelet rich fibrin is a matrix of autologous fibrin. Since its inception in 2001 by Choukron *et al.* It has been widely used to improve bone and soft tissue healing.

Today it is accepted and most extensively worked upon current biological material with immense regenerative potential. PRF has significantly reduced the loading time without any postoperative complication. Growth factors in PRF are the universal initiators of almost all wound healing. Enveloping the implant with platelet rich fibrin significantly speeds up the healing process and tissue regeneration. The soft tissue healing occurs at an accelerated rate. It also reduces and repair the small osseous defects. The best advantage of PRF is its cost effectiveness, prepared from patient's own blood. The use of short implants offer, in relation to the regenerative techniques, several advantages: low cost and treatment length, simplicity, and less risk of complications.

Thus it can be concluded that the use of PRF along with short implants is an important adjunct in implantology as it accelerates the soft and hard tissue healing around the implant without performing any extensive surgery in deficient bone height and contributes to the overall success of implants.

References

- Pigossi SC, Alvim-Pereira F, Montes CC, Finoti LS *et al.* Genetic association study between Interleukin 10 gene and dental implant loss. *Archi Oral Bio.* 2012; 57:1256-1263.
- Annibali S, Cristalli MP, Dell'Aquila D *et al.* Short dental implants: A systematic review. *J Dent Res.* 2012; 91(1):25-32.
- Al-Johany SS, Al Amri MD *et al.* Dental implant length and diameter: A proposed classification scheme. *J Prostho* 2016; 00:1-8.
- Anitua E, Orive G. Short implants in maxillae and mandibles: A retrospective study with 1 to 8 years of follow-up. *J Periodontol.* 2010; 81:819-826.
- Oncu E, Alaaddinoglu EE. The effects of Platelet-Rich Fibrin on implant stability. *Int J Oral Maxillofac Implants.* 2015; 30:578-582.
- Giannini S, Cielo A, Bonanome L, Rastelli C *et al.* Comparison between PRP, PRGF and PRF: lights and shadows in three similar but different protocols. *Europ Review for Med and Pharmacol Sciences.* 2015; 19:927-930.
- Ehrenfest DMD *et al.* Do the Fibrin Architecture and Leukocyte Content Influence the Growth Factor Release of Platelet Concentrates? An Evidence-based Answer Comparing a Pure Platelet-Rich Plasma (P-PRP) Gel and a Leukocyte- and Platelet-Rich Fibrin (L-PRF). *Current Pharmaceutical Biotechnology,* 2012; 13:1145-1152.
- Sunitha Raja V, Munirathnam. Platelet-rich fibrin: Evolution of a second-generation platelet concentrate. *Indian J Dent Res* 2008; 19(1).
- Joseph Choukroun, Antoine Diss, Alain Simonpieri *et al.* Platelet-rich fibrin (PRF): A second-generation platelet concentrate. Part IV: Clinical effects on tissue healing. *Oral Surg Oral Med Oral Pathol Oral Radiol Endod* 2006; 101:299-303.
- Marco Tatullo, Massimo Marrelli *et al.* Platelet Rich Fibrin (P.R.F.) in Reconstructive Surgery of Atrophied Maxillary Bones: Clinical and Histological Evaluations. *International Journal of Medical Sciences.* 2012; 9(10):872-880.
- Mohamed H, Kenawy EL, Una M. El Shinnawi, Ahmed M. Salem, Fakhrdin H Ahmed. Efficacy of Platelet Rich Fibrin (PRF) Membrane in Immediate Dental Implant. *Mansoura Journal of Dentistry.* 2014; 1(3):78-84.
- Dohan Ehrenfest DM. *et al.* Slow release of growth factors and thrombospondin-1 in Choukroun's platelet-rich fibrin (PRF): a gold standard to achieve for all surgical platelet concentrates technologies. *Growth Factors.* 2009; 27(1):63-69.
- Boora P, Rathee M, Bhorla M. Effect of Platelet Rich Fibrin (PRF) on peri-implant soft tissue and crestal bone in one-stage implant placement: a randomized controlled trial. *J Clin Diag Res.* 2015; 9(4):18-21.
- Kobayashi M *et al.* A proposed protocol for the standardized preparation of PRF membranes for clinical use. *Biologicals.* 2012; 40:323-329.
- Dohan MD. Platelet rich fibrin (PRF): A second generation platelet concentrate. Part I: Technological concepts and evolution. *Oral surg Oral Med Oral Pathol*

Oral Radiol Endod 2006; 101:37-44.

16. Muhamad HA, Georges C, Ameer S, Ayah J, Azzaldeen A. Short implants in clinical practice. IOSR-JDMS. 2017; 16(5)9:89-96.
17. Misch CE *et al.* Implant Success, Survival, and Failure: The International Congress of Oral Implantologists (ICOI) Pisa Consensus Conference. Implant Dentistry 2008, 17.
18. Peck MT, Marnewick J, Stephan LX, Singh A, Patel N, Majeed A. The use of leucocyte- and platelet-rich fibrin (L-PRF) to facilitate implant placement in bone-deficient sites: a report of two cases. SADJ. 2012; 67(2):54-49.
19. Vijayalakshmi R, Rajmohan CS, Deepalakshmi D, Sivakami G. Use of platelet rich fibrin in a fenestration defect around an implant. J Indian Soc Periodontol. 2012; 16(1):108-12.
20. Kundu R, Rathee M. Effect of Platelet-Rich-Plasma (PRP) and implant surface topography on implant stability and bone. J Clin Diagn Res. 2014; 8(6):26-30.
21. Anitua E. Plasma rich in growth factors: preliminary results of use in the preparation of future sites for implants. Int J Oral Maxillofac Implants. 1999; 14(4):529-35.
22. Faot F *et al.* The effect of L-PRF membranes on bone healing in rabbit tibiae bone defects: micro-CT and biomarker results. Sci Rep. 2017; 7:46452.
23. Tabrizi R, Arabion H, Karagah T. Does platelet-rich fibrin increase the stability of implants in the posterior of the maxilla? A split-mouth randomized clinical trial. Int J Oral Maxillofac Surg. 2018; 47(5):672-675.
24. Fredes F *et al.* Potential Effect of Leukocyte-Platelet-Rich Fibrin in Bone Healing of Skull Base. Int Journal of Otolaryngology, 2017.
25. Wang X, Zhang Y, Choukroun J, Ghanaati S, Miron RJ. Effects of an injectable platelet-rich fibrin on osteoblast behavior and bone tissue formation in comparison to platelet-rich plasma. Platelets. 2017; 29(1):48-55.