



ISSN Print: 2394-7489  
ISSN Online: 2394-7497  
IJADS 2019; 5(2): 100-104  
© 2019 IJADS  
www.oraljournal.com  
Received: 17-02-2019  
Accepted: 18-03-2019

**Dr. Shantipriya Reddy**  
Professor and Head, Department of  
Periodontics, Dr. Syamala Reddy  
Dental College, Hospital and  
Research Centre, Bengaluru,  
Karnataka, India

**Dr. Prasad MGS**  
Professor, Department of  
Periodontics, Dr. Syamala Reddy  
Dental College, Hospital and  
Research Centre, Bengaluru,  
Karnataka, India

**Dr. Nirjhar Bhowmik**  
Reader, Department of periodontics,  
Dr. Syamala Reddy Dental College,  
Hospital and Research Centre,  
Bengaluru, Karnataka, India

**Dr. Ankita Kumari**  
Post Graduate Student, Department of  
Periodontics, Dr. Syamala Reddy  
Dental College, Hospital and  
Research Centre, Bengaluru,  
Karnataka, India

**Dr. Vidya Hiranmayi K**  
Sr. Lecturer, Department of  
Periodontics, Dr. Syamala Reddy  
Dental College, Hospital and  
Research Centre, Bengaluru,  
Karnataka, India

**Dr. Dhulipala Manasa**  
Sr. Lecturer, Department of  
Periodontics, Dr. Syamala Reddy  
Dental College, Hospital and  
Research Centre, Bengaluru,  
Karnataka, India

**Dr. Shanmuga Priya**  
Post Graduate Student, Department of  
Periodontics, Dr. Syamala Reddy  
Dental College, Hospital and  
Research Centre, Bengaluru,  
Karnataka, India

**Correspondence**

**Dr. Ankita Kumari**  
Post Graduate Student, Department of  
Periodontics, Dr. Syamala Reddy  
Dental College, Hospital and  
Research Centre, Bengaluru,  
Karnataka, India

## Horizontal ridge augmentation using combination of xenograft and collagen membrane for implant site development- A case series

**Dr. Shantipriya Reddy, Dr. Prasad MGS, Dr. Nirjhar Bhowmik, Dr. Ankita Kumari, Dr. Vidya Hiranmayi, Dr. Dhulipala Manasa and Dr. Shanmuga Priya**

### Abstract

**Introduction:** Loss of alveolar bone following tooth extraction is a common phenomenon which occurs especially within the first 6 months leading to the development of a variety of ridge deformities. The quantity and quality of bone support not only influences implant osseointegration, but also affects the shape and contour of the soft tissue and, hence, the esthetic outcome. Therefore, bone augmentation is an essential procedure.

**Aim:** The aim of the present case series is to evaluate the efficacy of xenograft (Bio Oss) in combination with collagen membrane (Creos Xenoprotect) in the treatment of horizontal ridge augmentation.

**Material and Methods:** In this case series five patients with Seibert's class I ridge defect were selected and horizontal ridge augmentation was done using combination of xenograft and collagen membrane. Clinical and radiographic measurements were performed at baseline and 6 months postoperatively.

**Results:** Ridge width at baseline assessed by bone sounding, direct caliper and CBCT was  $2.90 \pm 1.07$  mm,  $3.00 \pm 1.11$  mm and  $3.00 \pm 1.16$  mm and at 6 months by bone sounding and CBCT was  $5.54 \pm 1.11$  mm and  $5.62 \pm 1.18$  mm respectively.

**Conclusion:** In all 5 augmented sites, ridge width increased from baseline to 6 months. Thus, the use of xenograft along with collagen membrane provides a good alternative for lateral ridge augmentation.

**Keywords:** Alveolar ridge augmentation, Xenograft, Collagen membrane

### Introduction

The use of osseointegrated implants, anchored in jaw bone with direct bone-implant contact, became an increasingly important treatment modality for the replacement of missing teeth in fully and partially edentulous patients. Alveolar ridge deficiency due to trauma, congenital disorders, pathologic conditions, infections, or periodontal diseases challenges implant therapy [1]. Alveolar ridge resorption following tooth loss seems to be inevitable and irreversible which occurs especially within the first 6 months leading to the development of variety of ridge deformities.

The horizontal and vertical ridge resorption occurs at differential rates that vary among individuals and at different sites in the same person. The surgical reconstruction of such hard and soft tissue anomalies may represent demanding clinical scenarios for both patients and clinicians. Therefore, bone augmentation is an essential procedure before implant placement in sites with insufficient bone support [2].

The current practice for ridge augmentation consists of a variety of techniques amongst which Guided bone regeneration technique (GBR) has become the most popular reconstructive procedures for GBR procedure different bioresorbable materials have been introduced. One such popular material used for biological barrier is collagen. Amongst collagen membrane, Creos xenoprotect is a resorbable, non-chemically cross linked collagen membrane which is composed of a network of interwoven, highly purified porcine collagen and elastin fibers, providing membrane with high mechanical strength. The fiber mesh holds the bone graft material securely in place, preventing undesired soft tissue from migrating into the bone augmentation site during bone healing.

Amongst bone grafts, autogenous bone grafts appear to be the ideal material, but there is a need for a second surgical site leading to increased postoperative morbidity, unpredictable graft resorption, and injury to the neurovascular bundle, limited graft size and shape. Xenografts with osteoconductive properties are used for periodontal augmentation. Amongst xenograft, Bio-oss is bovine derived organic bone matrix having osteoconductive effects, which is devoid of protein content of bone while retaining its three-dimensional mineralized network<sup>3</sup>. The highlight of this case series is to evaluate the efficacy of collagen membrane and xenograft in the treatment of horizontal ridge augmentation.

### Materials and Methods

5 patients diagnosed with Seibert's class I ridge defect were selected from the outpatient department (OPD) of Periodontics and Implantology, Dr. Syamala Reddy Dental College, Hospital and Research centre, Bengaluru.

Patients were considered for the study based on following inclusion criteria: 1. Age group 30-50 years. 2. Patients with horizontal ridge defects (Seibert's Class I) 3. Ridge width  $\leq$  5 mm on bone sounding. 4. Adequate ridge height. 5. Cooperative patients who are willing to comply with follow-up protocol for the regular follow up treatment. 6. Systemically healthy individuals. Exclusion criteria were: 1. Patients with any previous or known history of systemic diseases, bleeding disorders, osteoporosis or medications that contraindicate surgery. 2. Patients taking any drugs known to affect the number and function of platelets. 3. Pregnant women and lactating mothers. 4. Smokers, alcoholics or patients with tobacco chewing habits. 5. Patients presenting with atrophic maxilla. 6. Active intra oral infections. 7. Patients on immunosuppressive medications and radiation therapy.

### Presurgical treatment

Each patient underwent radiographic (Cone beam computed tomography) and routine blood investigations. Acrylic stents of autopolymerising resin were fabricated by- sprinkle-on method. The stent covered the entire ridge on buccal and lingual side. Two grooves were made 3 mm below the crest on buccal and lingual side of the acrylic stent so as to guide the position of bone caliper as well as to standardise the radiographic measurement of bone width at same reproducible position preoperatively and post-operatively. These stents were preserved on the study cast through-out the study period to avoid any distortion. Preoperative and postoperative photographs for ridge width measurement were taken.

Parameters assessed were: 1. Alveolar ridge width by Bone sounding measurements were recorded at baseline and 6 months using Endodontic files and caliper. 2. Analysis of bone width using Cone Beam Computed Tomography at baseline and at 6 months interval. 3. Direct Caliper measurements of ridge width after flap reflection at baseline. Ridge defects were classified as being class I (Bucco-lingual loss of tissue with normal apico coronal height), class II (Apico coronal loss of tissue with normal Bucco-lingual width) or as class III (combination) based on the ridge defect classification system<sup>[4]</sup>.

### Surgical procedure

A crestal incision with vertical releasing incisions was made at the treatment site to expose the bone, and periosteal release was performed to achieve tension free flaps. Acrylic surgical

stents were placed at the ridge and ridge width at crest and 3 mm apical to the crest was measured by caliper. Prior to placement of bone graft, the bone defect was decorticated with a low speed drill using a round bur with perforations made in the cortical plate. Xenograft (Bio oss) was dispensed on to the dappen dish and mixed with normal saline for 10-15 minutes. The graft was then placed in the ridge defect area and covered with a collagen membrane (Creos xenoprotect) followed by hidden-X suturing technique for primary closure of wound which then completed with simple interrupted suture in the area of crestal and releasing incision<sup>[5]</sup>.

### Postoperative care

Post-operative instructions were given to the patient. Patients were prescribed augmentin 625mg twice daily for 3 days and Diclofenac 100 mg twice daily for 3 days. Chlorhexidine rinse (0.2%) was prescribed twice daily for 10 days. After two weeks sutures were removed, and surgical site was examined. Patients were recalled after 6 months and bone sounding was performed following the baseline protocol. Existing removable dentures were not used for the first 2 weeks after surgery.

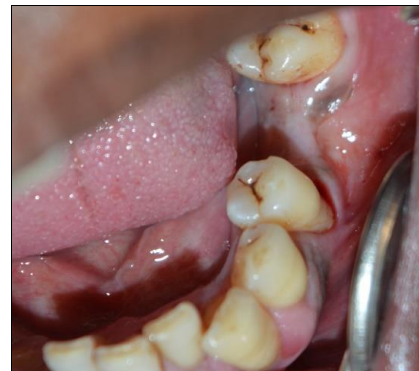

Fig 1: Pre-operative site wrt 36

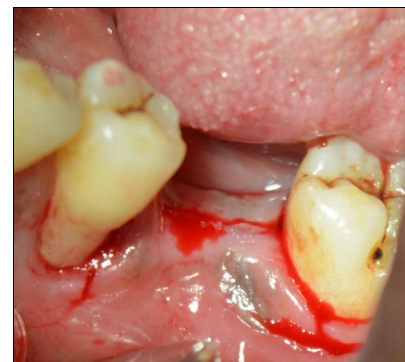

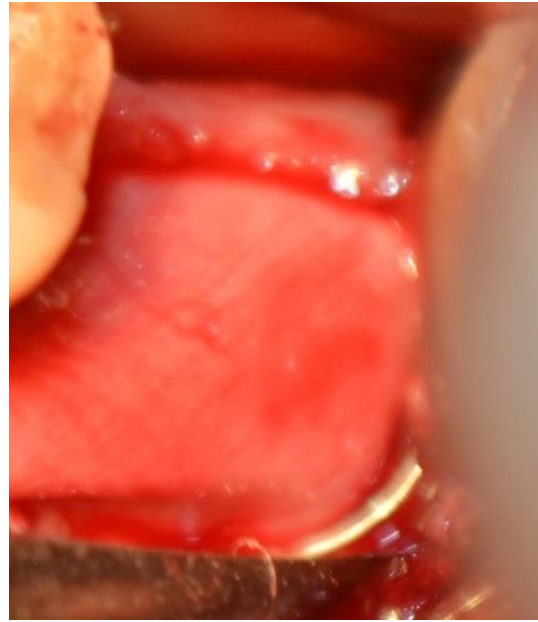
Fig 2: Crestal incision follow by releasing incision

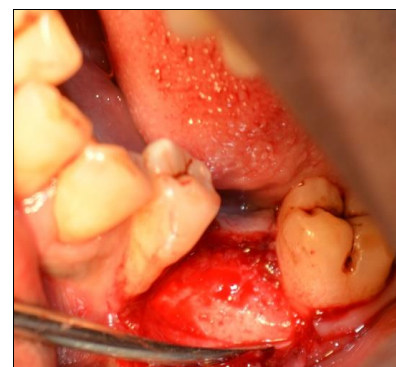

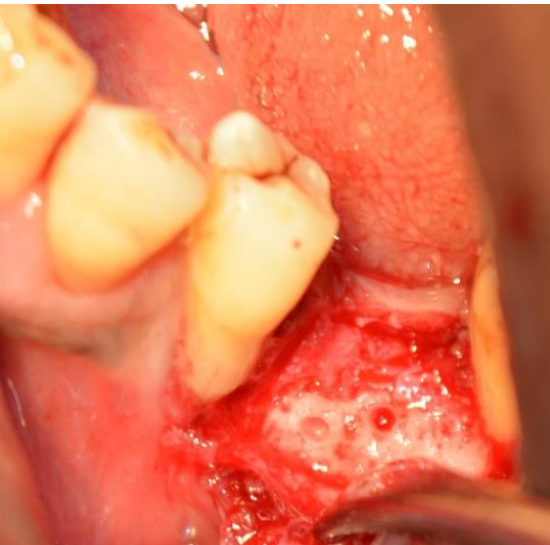
Fig 3: Reflection of mucoperiosteal flap



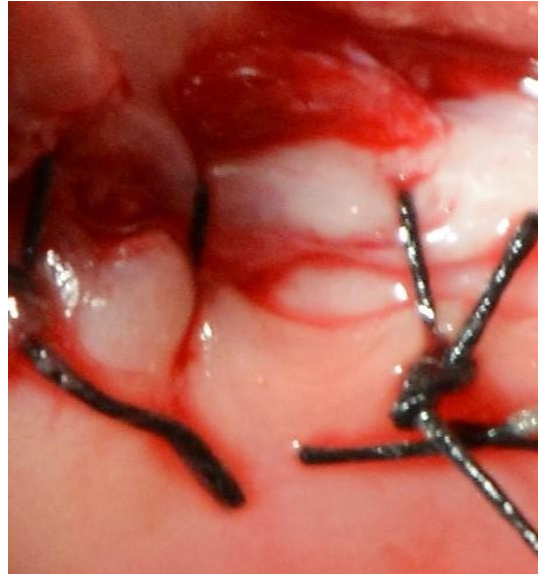**Fig 4:** Ridge width measurement by direct caliper



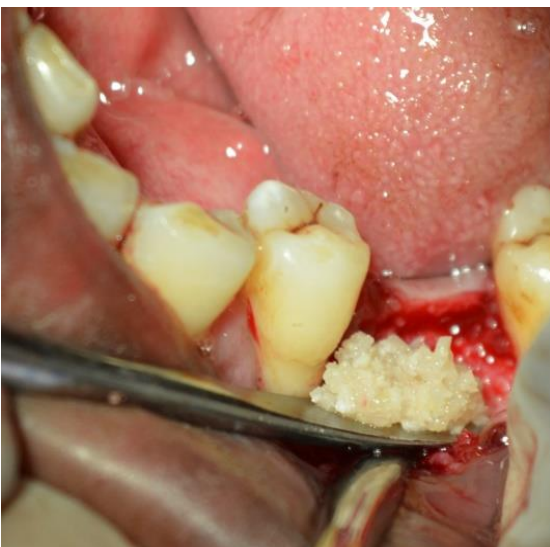
**Fig 7:** Adaptation of collagen membrane



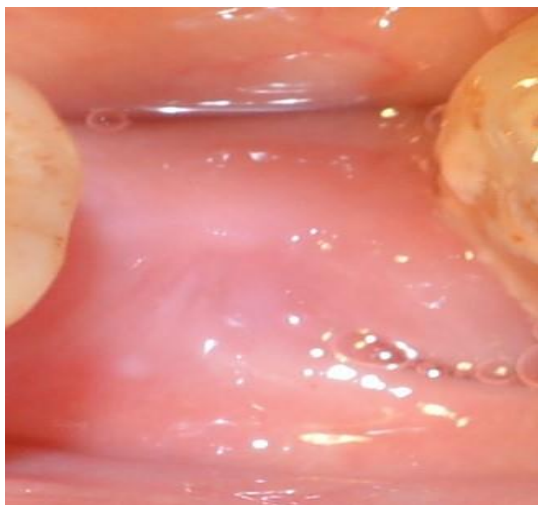
**Fig 5:** Decortication done using round bur



**Fig 8:** Suturing



**Fig 6:** Placement of bone graft



**Fig 9:** Post- operative site wrt 36

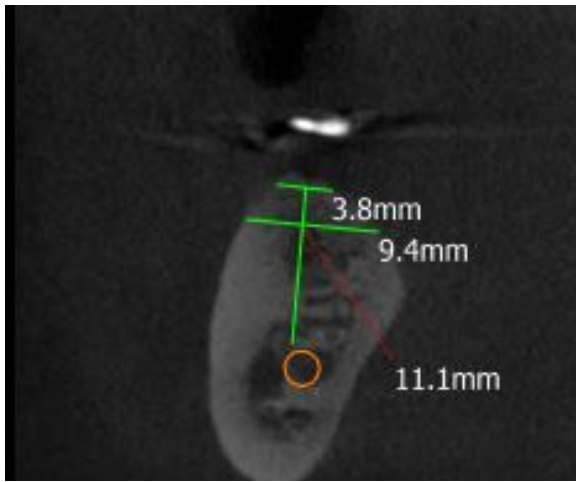


Fig 10: CBCT at the crest at baseline

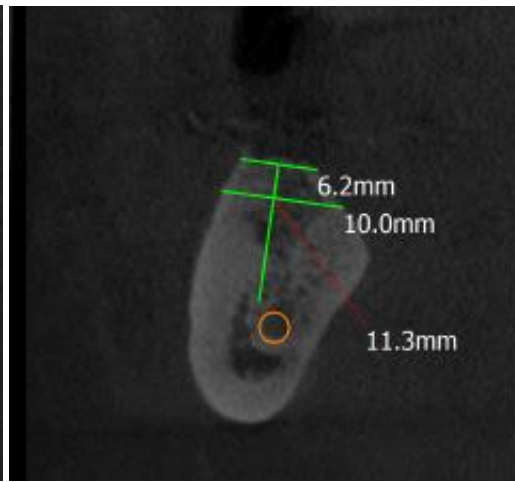


Fig 11: CBCT at the crest at 6 months

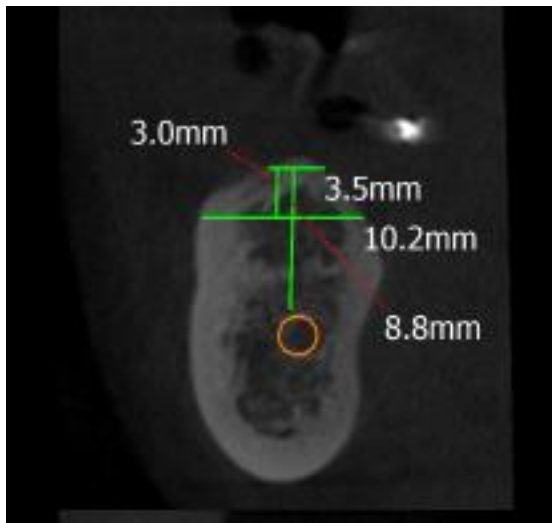


Fig 12: CBCT 3 mm below crest at baseline

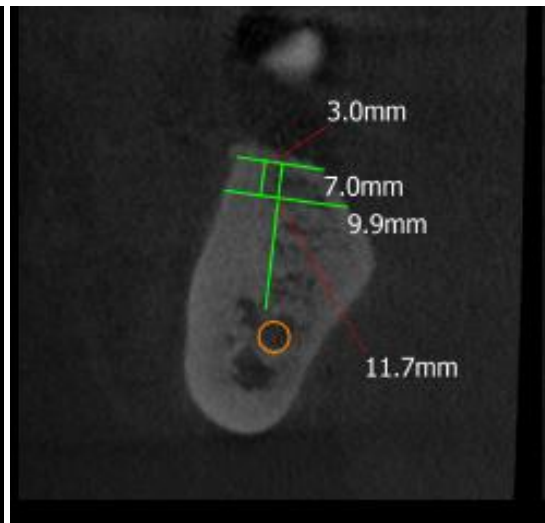


Fig 13: CBCT 3 mm below crest at 6 months

**Results**

Primary closure was obtained in all 5 augmented sites. Throughout the study in all the augmented sites, there was neither membrane exposure nor any other related complications. All 5 sites completed 6 months follow up. Data was collected and according to the procured data the results were formulated. Results showed that ridge width obtained by bone sounding was  $2.90 \pm 1.07$  mm at baseline and

$5.54 \pm 1.11$  mm at 6 months. A mean gain of 2.64 mm was recorded at 6 months. Ridge width obtained by CBCT at the crest was  $3.00 \pm 1.16$  mm at baseline and  $5.62 \pm 1.18$  mm at 6 months. A mean gain of 2.62 mm was recorded at 6 months. Ridge width obtained by CBCT at 3 mm below crest was  $4.54 \pm 0.69$  mm at baseline and  $5.64 \pm 1.11$  mm at 6 months. A mean gain of 1.10 mm was recorded at 6 months.

**Table 1:** Ridge width measurement at crestal region at baseline and at 6 months

Site/Site	Bone sounding at baseline at the crest	Direct caliper Method measurement at baseline at the crest	Dental CBCT scan value at baseline at the crest	Bone sounding at 6 months at the crest	Dental CBCT scan value at 6 months at the crest
46	4	4.2	4.1	5.7	5.9
36	2.8	2.8	3	6.5	6.5
36,37	1.5	1.8	1.7	4.1	4.2
45	2.3	2.1	2	4.4	4.6
46	3.9	4.1	4.2	6.7	6.9

**Table 2:** Ridge width measurement at 3 mm below crest at baseline and at 6 months

Site/sites	Dental cbct scan value at baseline, 3mm below crest level	Direct caliper Method measurement at baseline 3mm below crest	Dental CBCT scan value at 6 months, 3mm below crest
46	4.2	4.4	6.2
36	3.5	3.5	7.2
36,37	5.1	4.9	6.5
45	5.1	5.2	6.7
46	4.8	4.6	7

## Discussion

The present case series was aimed to evaluate efficacy of xenograft with collagen membrane in the treatment of Seibert's class I ridge defects. Xenograft used in the present case series is bovine derived bone graft (Geistlich Bio oss) which has been considered the most successful bone substitute worldwide and remains the best choice among different graft materials. The barrier membrane used in the present case series is non-cross linked collagen membrane (Creos Xenoprotect) of size 25×30 mm. In the present study, the combination of collagen membrane and xenograft resulted in a mean gain of 2.62mm. This result was in agreement with previous study done by Hammerle *et al.* who reported a mean gain of 3.7mm with xenograft and collagen membrane [6].

Alveolar ridge width measurements were recorded by 3 methods (bone sounding, CBCT and direct caliper) and there was no statistically significant difference between these 3 methods both at baseline and after 6 months. This was in agreement with the results reported by Lung-cheng Chen *et al.* in 2008 and Shreyansh *et al.* in 2011 where CBCT was compared to direct caliper method [7]. In present study, decortication was performed in all the defect sites as a part of GBR protocol. Drilling holes through the cortical bone into more vascular cancellous bone induces bleeding that immerses the GBR sites in the blood. As the clot organizes, it releases cytokines and growth factors to attract progenitor cells, osteoblast and blood vessels. Hence decortication of bone is frequently performed as a part of ridge augmentation procedures [8].

Although in the present study all the 5 sites exhibited increase in the ridge width, due to limited number of sites and short term follow up, predictability of this procedure could not be truly determined. None of the sites exhibited any premature exposure of the membrane or any associated complications throughout the postoperative period.

Future studies should incorporate more number of sites, long term follow-up and should perform histologic evaluation of augmented bone in order to ascertain the quality of bone.

## Conclusion

The results from current case series is in agreement with the existing data on horizontal ridge augmentation. The results encourage the use of xenograft in combination with collagen membrane as a suitable alternative for performing ridge augmentation. However, since the present study utilized only clinical and radiographic methods for all the measurements, histologic method should also be utilized to confirm the quality of bone.

## References

1. Amoian B, Moudi E, Majidi MS, Ali Tabatabaei SM. A histologic, histomorphometric, and radiographic comparison between two complexes of Ceno Boen /Ceno Membrane and Bio-Oss/Bio-Gide in lateral ridge augmentation: A clinical trial. *Dent Res J.* 2016; 13:446-53.
2. Windisch P, Martin A, Shahbazi A, Molnar B. Reconstruction of horizontovertical alveolar defects. Presentation of a novel split-thickness flap design for guided bone regeneration: A case report with 5-year follow-up. *Quintessence Int.* 2017; 48(7):535-547.
3. Gross JS. Bone grafting materials for dental applications: A practical guide. *Compend Contin Educ Dent.* 1997; 18:1013-8.
4. Seibert JS. Reconstruction of deformed, partially

edentulous ridges, using full thickness onlay grafts. Part I. Technique and wound healing. *Compend Contin Educ Dent.* 1983; 4:437-453.

5. Park JC, Koo KT, Lim HC. The hidden X suture: a technical note on a novel suture technique for alveolar ridge preservation. *J Periodontal Implant Sci.* 2016; 46(6):415-425.
6. Hämmerle CH, Jung RE, Yaman D, Lang NP. Ridge augmentation by applying bioresorbable membranes and deproteinized bovine bone mineral: a report of twelve consecutive cases. *Clin Oral Implants Res.* 2008; 19(1):19-25.
7. Chen LC, Lundgren T, Hallstro H, Cherel F. Comparison of Different Methods of Assessing Alveolar Ridge Dimensions Prior to Dental Implant Placement. *J Periodontol.* 2008; 79:401-405.
8. Greenstein G, Greenstein B, Cavallaro J, Tarnow D. The role of bone decortication in enhancing the results of guided bone regeneration: a literature review. *J Periodontol.* 2009; 80(2):175-89.