



International Journal of Applied Dental Sciences

ISSN Print: 2394-7489
ISSN Online: 2394-7497
IJADS 2019; 5(2): 173-176
© 2019 IJADS
www.oraljournal.com
Received: 24-02-2019
Accepted: 26-03-2019

Dr. Gautam Bagchi
Professor & Head, Department
of Prosthodontics, Chandra
Dental College & Hospital,
Barabanki, Uttar Pradesh, India

Dr. Ankita Trikha
PG, Student, Department of
Prosthodontics, Chandra Dental
College & Hospital, Barabanki,
Uttar Pradesh, India

Dr. Gauri Singh
PG, Student, Department of
Prosthodontics, Chandra Dental
College & Hospital, Barabanki,
Uttar Pradesh, India

Dr. Gaurav Chandra
Reader, Department of
Prosthodontics, Chandra Dental
College & Hospital, Barabanki,
Uttar Pradesh, India

Dr. Shruti Sharma Grover
Senior Lecturer, Department of
Prosthodontics, Chandra Dental
College & Hospital, Barabanki,
Uttar Pradesh, India

Correspondence

Dr. Gautam Bagchi
Professor & Head, Department
of Prosthodontics, Chandra
Dental College & Hospital,
Barabanki, Uttar Pradesh, India

Management of complex esthetic situation in mandibular anterior region using implant supported prosthesis with customized cast abutment: A case report

**Dr. Gautam Bagchi, Dr. Ankita Trikha, Dr. Gauri Singh, Dr. Gaurav
Chandra and Dr. Shruti Sharma Grover**

Abstract

Aim: To rehabilitate a patient with missing mandibular central incisors exhibiting limited mesio-distal space and unfavourable root angulation of adjacent teeth using implants to achieve optimal esthetics, emergence profile and function, along with preservation of surrounding hard and soft tissue.

Keywords: Missing mandibular anteriors, limited mesio-distal space, high esthetic requirement, small diameter implants, customized abutments

Introduction

The role of osseointegrated, dental implants as an extension of the conventional dental treatment spectrum is becoming increasingly common. Apart from the purely functional side of the implant restorations aesthetic aspects are also very important for the patients specially in the anterior region.

The design of the prosthesis and soft tissue drape plays an important role in aesthetics.

The challenges associated with replacing missing tooth at anterior mandible include limited mesial to distal alveolar ridge length, lack of adequate facial-lingual bone, challenging surrounding anatomy, and potentially high esthetic requirements^[1,2].

Several treatment options currently exist for patients to replace a mandibular-incisors. Three main categories exist: Removable Prosthesis, Fixed Partial Prosthesis, and Implant Retained Prosthesis.

These days patients are increasingly opting for implant supported prosthesis as opposed to other treatment options such as Fixed partial dentures (FPD) and Removable partial dentures (RPD) as these dictate performing tooth preparation to neighboring sound teeth structure and increased residual ridge resorption rate in case of removable prosthesis^[3].

Small diameter implants are often chosen for cases where there is a reduced availability of alveolar ridge width or interdental space.

Deficient bone volume, anatomical limitations, lack of available mesiodistal space, adjacent teeth angulations, make placement difficult of even narrow diameter implants. In such a scenario, achieving a functional and esthetic—yet sustainable—replacement of more than one missing tooth becomes quite challenging. This article describes the successful restoration of missing both mandibular central incisors on one 3.75-mm two-stage implant. Despite being a biomechanically complex presentation, the objectives of optimal outcome were achieved in the patient by means of innovative design, fine control of occlusal factors, and correct choice of restorative materials.

Case Report

A 25-year-old female patient reported to Department of Prosthodontics, Chandra Dental College and Hospital, Barabanki with the chief complaint of congenitally missing lower central incisors. On clinical examination it was observed that the mesio-distal space available was 6.5 mm and the width facio-lingually was 4.5 mm, cervico-incisal length of adjacent lateral

incisors were normal length. For evaluation of availability of bone the OPG was done, it showed mesial angulation of the roots both lateral incisors towards the midline (Fig.1), and generalised horizontal bone loss at the alveolar crest region Division B-w. Alginate impressions (Algitek Dental Products of India, Mumbai, India) of upper and lower arch were made and poured to get diagnostic casts. The treatment options given to the patient included fixed partial denture, removable partial denture and implant supported prosthesis. The patient wanted fixed replacement of the tooth without involving her adjacent teeth and desired an implant prosthesis. On evaluation of radiographs and diagnostic cast a single regular diameter implant in the midline was planned as there was insufficient mesio-distal space for two narrow diameter implants and also due to mesial angulation of the roots of the adjacent lateral incisors. A two-stage surgery was planned, an implant of diameter 3.75 mm and length 10 mm (Adin, Dental Implant Systems Limited, Israel) was selected. Accordingly, a clear acrylic resin surgical template was made on the diagnostic cast which allowed the proper access to the osteotomy site in terms of position, mesiodistally and angulation labiolingually. The ideal angulation for implant insertion was determined on the diagnostic wax up, and the template was made to relate to this position during surgery. A hole was drilled into the planned implant site and a 2mm wide tube was placed around the bur and stabilized with wax and surgical template of clear acrylic was fabricated.

The patient was educated to use aqueous 0.2% chlorhexidine mouth rinse, 3 times daily for 2 weeks for oral disinfection before implant placement. One hour before surgery, the patient was given antibiotics (amoxicillin 500 mg, 2 tablets). Strict protocols of sterilization and disinfection were followed. After the administration of local anesthesia an incision was given crestally and the mucoperiosteal flap was elevated to expose the alveolar crest. The surgical template was placed for initial osteotomy with 2mm pilot drill. The implant of diameter 3.75 mm/ length 10 mm was placed using strict protocol of drill sequence as given by manufacturer. An IOPA X ray was done to confirm the position of the implant. Cover screw was placed and the surgical site was closed with sutures (Vicryl 3-0). Patient was given instructions for chlorhexidine gluconate and salt water rinses and other postoperative instructions such as adequate rest, application of cold pack (ice) and precautions to be taken to prevent bleeding, suture line opening and pain. After 2 weeks the patient was recalled and the sutures were removed. After 4 months the second stage surgery was performed and cover screw was removed and healing cap was placed to develop the required emergence profile. Three weeks later healing cap was removed which showed healed gingival cuff. To get the implant level impression closed tray technique was followed and the impression coping was placed. The fit of the impression coping was verified with the IOPA radiograph. Addition silicone impression material (Aquasil Ultra-Dentsply, USA) was used for making the impression. The impression coping was retrieved from the implant and joined together with implant analog and seated back in the impression. The impression was poured in die stone and the cast was made using esthetic gingival mask in the implant area. Custom UCLA abutment was planned as abutment option considering the increased mesio-distal space available with respect to missing teeth and angulation of the implant. The abutment shape was waxed up around the plastic pattern of the UCLA abutment as two crowns geminating from single implant. Wax was added to get emergence profile and desired

contour. Customized abutment was placed on the implant analog and twin metal ceramic crowns were made with the screw access hole on the labial side due to lingual angulation of the implant. The healing cap was removed and customized abutment was placed with 20 Ncm using a torque device and a large hex driver tip. The precise fit between the individualized abutment and the implant was verified radiographically. The occlusal contacts were carefully evaluated and implant protected occlusion was given. The screw access hole was covered with flowable composite of same shade. To date, the restoration has been in service for 18 months without complications.

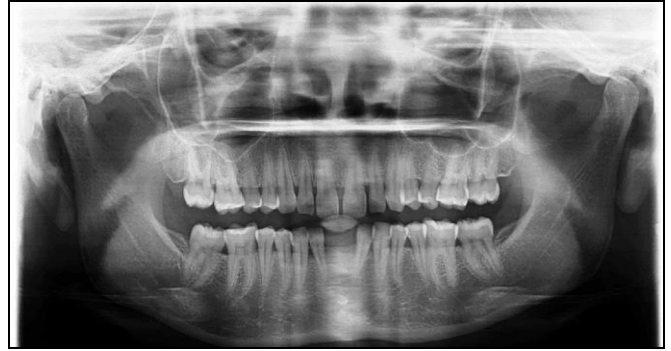

Fig 1: Pre-operative OPG

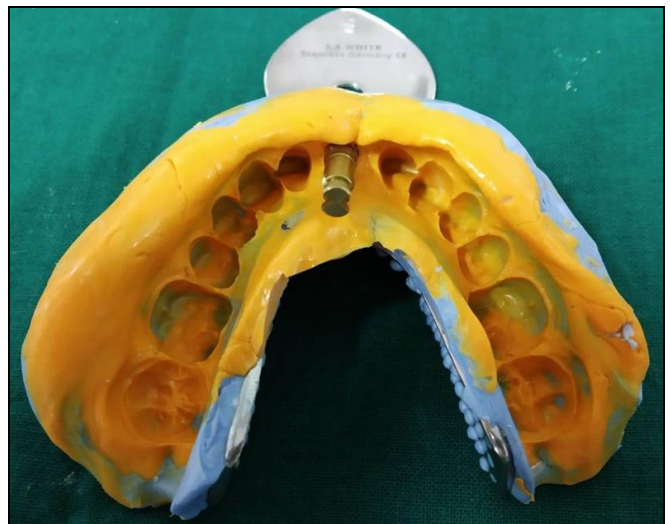


Fig 2: Final impression

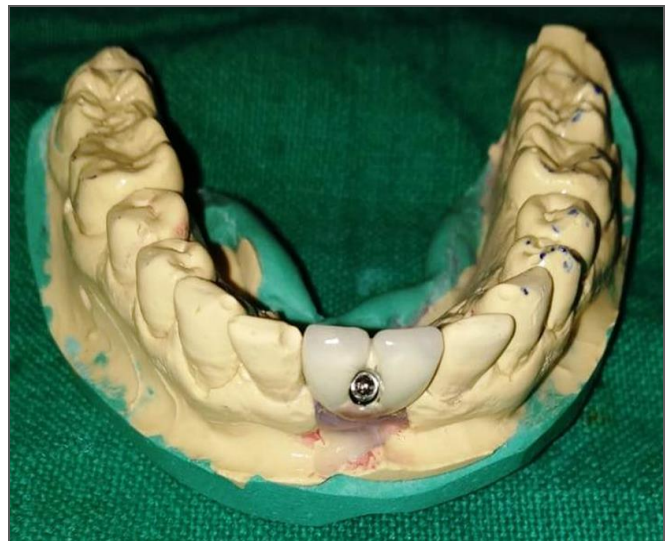

Fig 3: Prosthesis with access hole placed labially

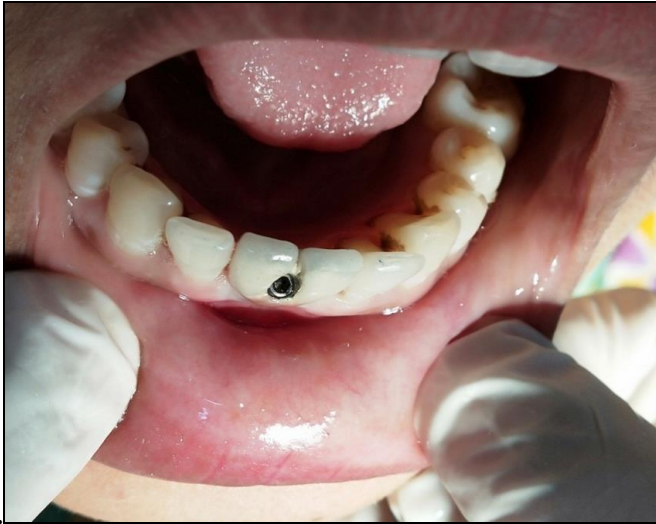

Fig 4: Prosthesis in mouth

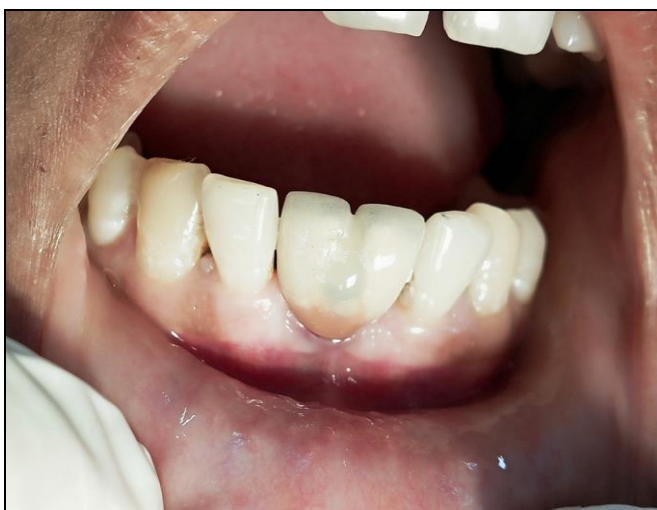

Fig 5: Access hole covered with composite

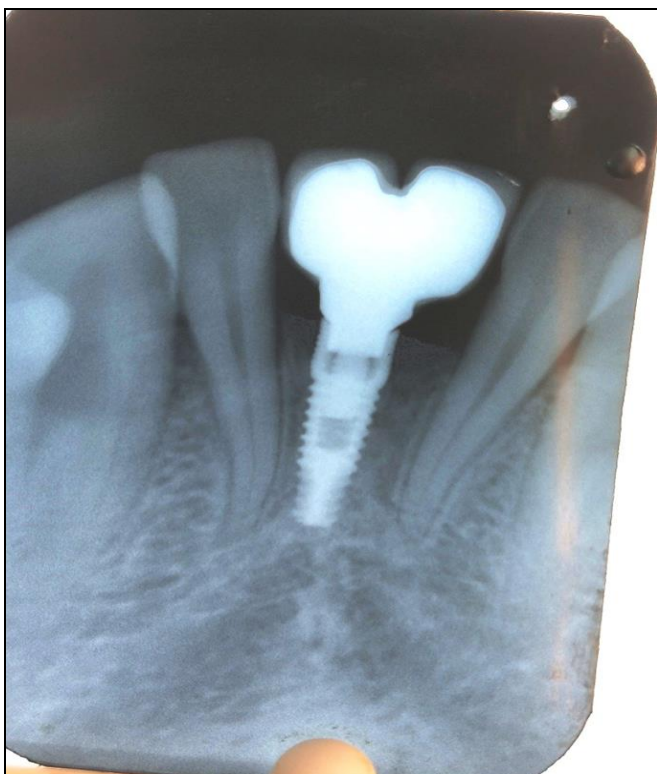


Fig 6: Radiograph of implant with prosthesis

Discussion

A requirement for successful implant placement is the presence of adequate bone volume to insure minimum of 2 mm of bone thickness facial to the implant especially in esthetic zone, a minimum of 1 mm lingual and sufficient interdental space to allow a standard-diameter implant to be inserted.

There are many procedures to increase facial-lingual bone volume, including guided bone regeneration [4, 5] and block grafting [6]. However, grafting cannot solve a mesial-distal space problem. Many authors have suggested that a minimum distance of 1.5 mm must be maintained between the adjacent tooth and implant to preserve the bone and interdental papilla in the area, thereby improving the success rate of the implant and the esthetic outcome. To adhere to this requirement, implant manufacturers have introduced smaller-diameter implants (3.0 to 3.5 mm). Nevertheless, these implants still require a minimum mesio-distal space of 6.0 to 6.5 mm to allow adequate implant-to-tooth distance. In some cases, obtaining this space is difficult, if not impossible. For example, in a patient with loss of one lower incisor, oftentimes the edentulous space is less than 6 mm. Therefore, it's impossible to place an implant, which has a diameter of more than 3 mm and maintain a 1.5 mm distance on each side from natural adjacent teeth.

To solve this mesial-distal space problem, the following 3 options have been suggested.

1. Extract a neighboring lower incisor and make a cantilever crown (2-unit fixed restoration). With this option, a 3.75 - 4.75 mm diameter implant can be placed which has adequate implant-to-bone surface area and reduce the risk of implant fracture.
2. Use of a transitional implant of 1.8-2.8 mm diameter,
3. Placing a 3.0-3.7 mm diameter implant to achieve an appropriate implant-to-bone surface area.

Klein in a systematic review of the literature categorizes narrow diameter implants into three categories, implant diameter < 3 mm (category 1), and implant diameter 3 to 3.25 mm (category 2) and implant diameter 3.3 to 3.5 mm (category 3). Small diameter implants are often chosen for cases where there is a reduced availability of alveolar ridge width or interdental space. However, the reduced surface area for osseointegration [7, 8] and the increased risk for implant fracture [9, 10] in such cases may contradict the use of small diameter implants.

Inadequate facial bone is a common problem that can present itself at any time following extraction and often leads to a more unfavorable lingual angulation during implant placement and challenges during the restorative phase in achieving optimal aesthetics [11].

Three treatment options using implants for patients with limited mesial-distal distance between implant and adjacent teeth (< 6 mm).

- Cantilever crown from 3.75-4.75 mm diameter implant;
- Use of transitional implant of 1.8-2.8 mm diameter; or
- Placing a 3.0-3.7 mm diameter implant to achieve an appropriate implant-to-bone surface area.

Moderate to severe bone loss in anterior region presents a challenging situation to the dentists. Therefore, success is not only defined by osseointegration of the implant, but a harmonious and natural blending of the restoration with the surrounding tissues and dentition. Biological, functional and biomechanical parameters must be examined and potential

problems have to be identified preoperatively^[12].

The esthetic zone of the anterior maxilla/mandible often requires both hard (bone and teeth) and soft tissue restoration. In compromised situations where bone height or width is deficient at the osteotomy site, implant has to be placed more apically and/or palatally/lingually, various treatment options are available to rehabilitate such cases. The most common approach is to modify the narrower division B ridge into another bone division by crestal osteoplasty. Bone augmentation in Division B bone can be done by narrow osteotomy made between the bony plates and bone spreader tapped into edentulous site with subsequent placement of bone graft material (e.g autogenous or demineralized freeze dried bone, synthetic bone substitutes). In the severe cases on lay particulate autogenous graft covered with a membrane for guided tissue regeneration may be required.

All these procedures require additional surgical intervention, are expensive as well as time consuming. Narrow diameter root form implants with sufficient length may be used but they transfer greater stress to the crestal bone. Thus to avoid additional surgical procedures angulated/Customised abutments may be used. Proper examination, diagnosis and treatment planning, are necessary for esthetic and functional success of anterior single-tooth implants. To achieve prosthetically desired parallelism between implants or teeth, the clinician can place an angled abutment. Angulations of as much as 15 degree are easy to correct with pre angled components. Greater angulation correction may be possible with either pre angled parts or custom-made components, which may be fabricated at any length or angulations, though more than 30-degree angulation is not recommended^[13].

Thus the clinician has the choice of either prefabricated or customized abutments. While standard sizes and dimension abutments are sufficient for use in posterior restorations, their application in the anterior regions may not lead to an optimal esthetic final result thus making use of customized abutments necessary.

Conclusion

The anterior implant is successful only if the final restoration is fully integrated within the adjacent dentition. Abutments serve as an important link between implants and the prosthetic superstructure.

Angled abutments no doubt result in increased stress on implants and adjacent bones but they are within physiologic limits. Customized UCLA implant abutments may be treated like natural abutment teeth and provide excellent esthetic and functional properties for long-term clinical success. These abutment options allowed esthetic restorations to be finished in close proximity to the implant head, overcoming many esthetic dilemmas.

While survival rates of end osseous titanium implants are no longer a relevant problem^[14], the aesthetic requirements of patients have risen further in recent years. This applies not only to the so-called "white aesthetics", which can be optimally solved using modern veneering or full-ceramic systems, but also to the so-called "red aesthetics", which is determined by the health and contour of the gingival tissue^[14]. In addition to its function, aesthetics is an essential success criterion, which must be foreseeable to be solved by the implant dentist.

References

1. Fleigl J, Salmon C, Piper M. Treatment options for the replacement of missing mandibular incisors. J

Prosthodont. 2011; 20:414-420.

2. Alodadi A, Kreingsak T, Hazlina B, Ghani A, Angie MML *et al.* Various Treatment Options for the Single Implant in the Mandibular Anterior Region. J Oral Bio. 2016; 3(1):37-42.
3. Vyas A, Khare E, Desai P, Dhiman Y. Management of malpositioned anterior implant by using patient specific abutments:A clinical case series. Int J Oral Implantol Clin Res. 2014; 5(2):79-82.
4. Simion M, Dahlin C, Trisi P, Piattelli A. Qualitative and quantitative comparative study on different filling materials used in bone tissue regeneration: a controlled clinical study. Int J Periodontics Restorative Dent.1994; 14(3):198-215.
5. Simion M, Scarano A, Gionso L, Piattelli A. Guided bone regeneration using resorbable and nonresorbable membranes: a comparative histologic study in humans. Int J Oral Maxillofac Implants.1996; 11:735-742.
6. Pikos MA. Block autografts for localized ridge augmentation: Part I. The posterior maxilla. Implant Dent.1999; 8:279-285.
7. Ivanhoff CJ, Sennerby L, Johansson C, Rangert B, Lekholm U. Influence of implant diameters on the integration of screw implants. An experimental study in rabbits. Int J Oral and Maxillofac Surg. 1997; 26:141-148.
8. Winkler S, Morris HF, Ochi S. Implant survival to 36 months as related to length and diameter. Ann of Periodontol. 2000; 5:22-31.
9. Quek CE, Tan KB, Nicholls JI. Load fatigue performance on a single-tooth implant abutment system: effect of diameter. Int J Oral Maxillofac Implants. 2006; 21:929-936.
10. Allum SR, Tomlinson RA, Joshi R. The impact of loads on standard diameter, small diameter and mini implants: a comparative laboratory study. Clinical Oral Implants Res. 2008; 19:553-559.
11. Leblebicioglu B, Rawal S, Mariotti A. A review of the functional and esthetic requirements for dental implants. J Am Dent Assoc. 2007; 138:321-329.
12. Chatterjee A, Ragher M, Patil S, Chatterjee D, Dandekeri S, Prabhu V. Prosthetic management of malpositioned implant using custom cast abutment. J Pharm Bioallied Sci. 2015; 7(2):740-745.
13. Gupta A, Jain D, Sangwan A, Chhabra A. Abutment Options for Compromised situation in Esthetic Zone: Case Reports. IOSR Journal of Dental and Medical Sciences. 2015; 14(8):30-37.
14. Ketabi A, Ketabi S, Lauer H, Brandt S. Rehabilitation of Two Patients with Individual Abutments: Case Report. Research & Reviews: Journal of Dental Sciences: 2017; 5(2):17-22.