



ISSN Print: 2394-7489
ISSN Online: 2394-7497
IJADS 2019; 5(2): 215-217
© 2019 IJADS
www.oraljournal.com
Received: 07-02-2019
Accepted: 09-03-2019

Anil K Tomer
Professor and Head,
Department of Conservative
Dentistry & Endodontics, D.J.
College of Dental Sciences and
Research, Modinagar, Ghaziabad,
Uttar Pradesh, India

Anila Krishna Saxena
Post Graduate Student,
Department of Conservative
Dentistry & Endodontics, D.J.
College of Dental Sciences and
Research, Modinagar, Ghaziabad,
Uttar Pradesh, India

Artika Gupta
Post Graduate Student,
Department of Conservative
Dentistry & Endodontics, D.J.
College of Dental Sciences and
Research, Modinagar, Ghaziabad,
Uttar Pradesh, India

Akankshita Behera
Post Graduate Student,
Department of Conservative
Dentistry & Endodontics, D.J.
College of Dental Sciences and
Research, Modinagar, Ghaziabad,
Uttar Pradesh, India

Nitish Mittal
Post Graduate Student,
Department of Conservative
Dentistry & Endodontics, D.J.
College of Dental Sciences and
Research, Modinagar,
Ghaziabad, Uttar Pradesh, India

Lungdin Leima Cecilia
Post Graduate Student,
Department of Conservative
Dentistry & Endodontics, D.J.
College of Dental Sciences and
Research, Modinagar, Ghaziabad,
Uttar Pradesh, India

Correspondence
Anil K Tomer
Professor and Head,
Department of Conservative
Dentistry & Endodontics, D.J.
College of Dental Sciences and
Research, Modinagar, Ghaziabad,
Uttar Pradesh, India

Post and core management of maxillary lateral incisor with type III Vertucci root canal configuration: A case report

Anil K Tomer, Anila Krishna Saxena, Artika Gupta, Akankshita Behera, Nitish Mittal and Lungdin Leima Cecilia

Abstract

This case report describes the post and core treatment of a type III Vertucci canal configuration in maxillary lateral incisor. A 28-year-old female patient reported to the Department of Conservative Dentistry and Endodontics with the chief complaint of pain in upper front tooth region. On clinical examination, there was presence of faulty restoration which on removal showed loss of significant tooth structure necessitating post and core treatment. The tooth showed unusual canal anatomy with a single canal splitting to divide in two which joined again short of the apex. Such a canal configuration is classified as Vertucci Type III. Treatment was initiated with removal of old restoration, scouting was done to locate the two c followed by chemo mechanical preparation and obturation. Post space preparation was done in the palatal canal followed by post cementation and core build up.

Keywords: Type III Vertucci canal, Post and core

1. Introduction

Endodontic treatment is the gold standard for treating teeth with necrotic and non-vital pulps. However, in some cases root canal treatment doesn't suffice to obtain the desired results. This is specially challenging in cases of trauma that not only render the pulp non-vital but may also lead to fracture of the coronal tooth structure. In such cases, reinforcement of the tooth mandates the use of post and is an indication for post and core treatment. The use of post provides strength to the root structure and also helps in proper build-up of the coronal tooth structure.

In addition, the root canal system has a complex anatomy. Its form and configuration varies in each tooth. The root canal configuration has been classified into various types by different researchers. Vertucci classified root canal configurations into eight types which are as follows

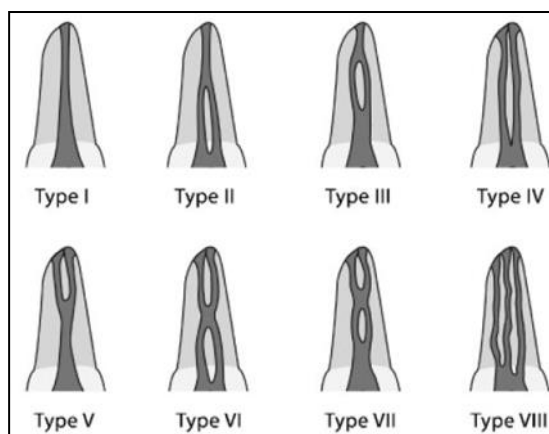


Fig 1: Diagrammatic representation of Vertucci's canal configurations.

These canal configurations present a major challenge to the clinician as it is difficult to locate all the canal orifices and often one or more canals are missed. Missed canals can lead to endodontic failure. It is thus, imperative that all the canals and their ramifications are located and adequately obturated after cleaning and shaping.

2. Case Report

A 28-year-old female patient reported to the Department of Conservative Dentistry and Endodontics with the chief complaint of faulty restoration and pain in upper front tooth region. On radiographic examination, the tooth shows faulty restoration extending till the pulp space. On vitality testing using cold test and electric pulp tester, the tooth tested non-vital. The patient was advised root canal treatment followed by post and core build up. After administration of local anaesthesia, access cavity was prepared and canal orifices located. Working length was determined and canal was prepared up to 25/0.04. The canal was obturated with mono cone technique using AH Plus sealer. After this, post space preparation was done in the palatal canal using peeso reamers size 1 and 2 leaving 4-5mm apical gutta percha intact. Prefabricated post was cemented in the post space and the core build up was subsequently done. Follow up was done one month postoperatively.

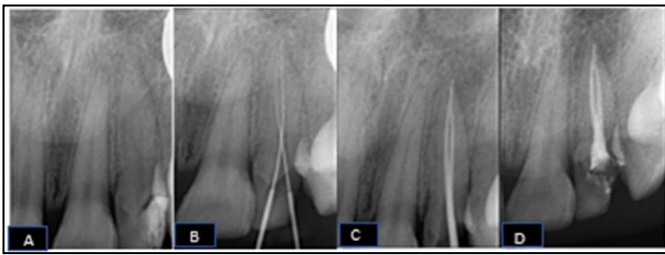


Fig 2: (A) Preoperative radiograph (B) working length determination (C) Master cone radiograph (D) Obturation radiograph

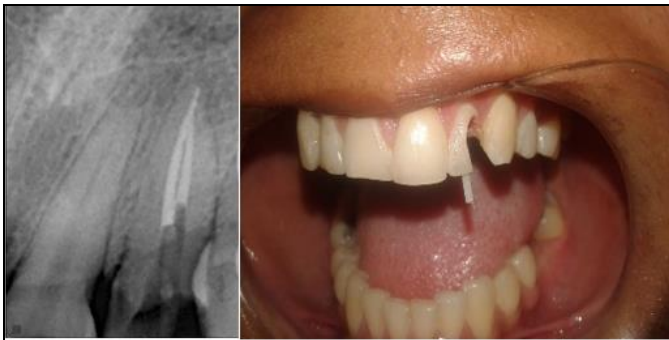

Fig 3: Post placement (radiograph and clinical photograph)

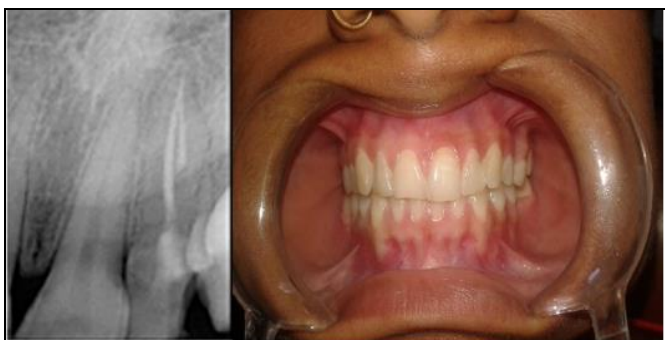

Fig 4: Postoperative after 1month (Radiograph and clinical photograph)

3. Discussion

This case report emphasizes on the importance of various canal morphologies. It is necessary to have a sound knowledge about the different canal aberrations that may exist so as to ensure a proper root canal treatment. In case of any missed canals the chances of failure of endodontic treatment become more likely. Vertucci divided the canal configuration into eight types according to the canal variations. Type III Vertucci canal system refers to a canal morphology wherein the single divides into two which again join to form one short of the apex. Such a morphology if missed will decrease the chances of successful endodontic treatment (also known 1-2-1).

Mulla *et al.* emphasized that the poor prognosis of the periapical pathology in mandibular incisors following an endodontic treatment is mostly because of the presence of unnoticed second and/or lateral canals. Knowledge of the variations in the root canal anatomy is important to carry out a successful root canal shaping^[1].

Saati *et al.* concluded that most failures in endodontic treatment of incisors are due to the presence of a missed canal specifically the lingual. If only one of the existing two canals is treated, pulp tissue of the second canal becomes necrotic and produces toxic agents, which can reach the periodontal ligament via an accessory or lateral canal^[2].

Freedman stated that the main function of the post is to anchor the post-and-core complex within the radicular portion of the remaining tooth. A post that can be bonded to tooth structure improves its ability to retain the entire foundation^[3]. The use of post enabled us to reinforce the strength of the lost tooth structure. Posts placed in the canal subsequent to endodontic treatment increases the strength of the tooth and helps it to withstand the masticatory forces directed along the tooth.

4. Conclusion

Root canal morphology has a wide range of anatomical complexities. To ensure a successful treatment, it is mandatory to identify all the canals and properly clean and shape them. Vertucci classification helps in identifying such canal deviations and properly treating them. This case report highlights the importance of identifying the canal aberrations for proper endodontic management and restoring the esthetics.

5. References

1. Mulla MK, Kulkarni G, Mangala TM, Kidiyoor KH. Endodontic management of mandibular incisors with Vertucci Type III canal configuration. *International Journal of Dental Clinics*, 2012, 4(3).
2. Saati S, Shokri A, Foroozandeh M, Poorolajal J, Mosleh N. Root morphology and number of canals in mandibular central and lateral incisors using cone beam computed tomography. *Brazilian dental journal*. 2018; 29(3):239-44.
3. Freedman G. A look at post and cores. *Dent Today*. 2002; 7:118-119.
4. Vertucci FJ. Root canal morphology and its relationship to endodontic procedures. *Endodontic topics*. 2005; 10(1):3-29.
5. Vertucci FJ. Root canal anatomy of the human permanent teeth. *Oral surgery, oral medicine, oral pathology*. 1984; 58(5):589-99.
6. Sahoo HS, Kurinji Amalavathy R, Pavani D. A Case Report on Endodontic Management of a Rare Vertucci Type III Maxillary Canine. *Case reports in dentistry*.

2019.

7. Aakrati Raina, Saurav Paul, Asheesh Sawhny, Sridevi Nandamuri. The curious case of Vertucci's type III root canals: A case series. 2019; 5(2):01-03.
8. Lee MH, Ha JH, Jin MU, Kim YK, Kim SK. Endodontic treatment of maxillary lateral incisors with anatomical variations. Restorative dentistry & endodontics. 2013; 38(4):253-7.
9. Thompson BH, Portell FR, Hartwell GR. Two root canals in a maxillary lateral incisor. Journal of endodontics. 1985; 11(8):353-5.
10. Boruah LC, Bhuyan AC. Morphologic characteristics of root canal of mandibular incisors in North-East Indian population: An *in vitro* study. J Conserv Dent. 2011; 14(4):346.
11. Amano R, Katsuumi I. evaluation of Root Canal Morphology in Maxillary Lateral Incisor Using a Micro-focus X-ray Ct Device: pr 05. Journal of Endodontics. 2013; 39(3):21.