



ISSN Print: 2394-7489  
ISSN Online: 2394-7497  
IJADS 2019; 5(3): 84-86  
© 2019 IJADS  
www.oraljournal.com  
Received: 10-05-2019  
Accepted: 12-06-2019

**Dr. SR Rane**

Associate Professor,  
Department of Pathology,  
BJGMC, Pune, Maharashtra,  
India

**Dr. AP Bhandari**

Assistant Professor,  
Department of Pathology,  
BJGMC, Pune, Maharashtra,  
India

**Dr. DP Dangmali**

Assistant Professor,  
Department of Pathology,  
BJGMC, Pune, Maharashtra,  
India

**Correspondence**

**Dr. AP Bhandari**

Assistant Professor,  
Department of Pathology,  
BJGMC, Pune, Maharashtra,  
India

## **Adenomatoid odontogenic tumor with cystic change: A rare neoplasm with unusual presentation**

**Dr. SR Rane, Dr. AP Bhandari and Dr. DP Dangmali**

### **Abstract**

Adenomatoid odontogenic tumor is an uncommon tumor of odontogenic origin with relatively low frequency of 3%. We report a case of young female presenting with large globular cystic mass on nose that mimics dentigerous cyst on clinical and radiological findings but turned out to be adenomatoid odontogenic tumor, true neoplastic lesion presenting as cystic mass. Treatment of this tumor is complete enucleation with no recurrence. This case was reported for its rarity and unusual features.

**Keywords:** Adenomatoid odontogenic tumor, dentigerous tumor, enucleation

### **Introduction**

Adenomatoid odontogenic tumor (AOT) was first documented in literature by Steensl and as epithelioma adamantium and variety of terminologies have been used to designate this entity. Adenomatoid odontogenic tumor with its simple abbreviation AOT is the most widely accepted terminology Philipsen and Birn, 1969. The WHO histological typing of odontogenic tumors, jaw cyst and allied lesions (2005) has defined AOT as a tumor of odontogenic epithelium with duct-like structures and with varying degree of inductive changes in the connective tissue [2]. The tumor may be solid or solid cystic or areas in some lesions may present as nodules in the capsule of a large cyst. While AOT is reported as a tumor in the histological sign out, the notion that it represents a hamartomatous malformation adds a new dimension to its assorted histological architecture. This unique report with a special emphasis on its histoarchitectural feature and ability to recur may want us to include AOT in differential diagnosis of all cystic swelling of jaw.

### **Case History**

26 years female patient was presented in our surgical OPD with swelling on right nose since 2 years which was slow progressive. On examination, large globular, 10x10x8cm, firm, non-tender, fluctuant swelling noted which was pushing right nostril skin. Overlying skin was distended and darkened. Clinically it was diagnosed as large dentigerous cyst was referred for CT scan for confirmation. CT scan report revealed well defined, expansile, cystic mass with central hypodensity occupying right maxilla arising from alveolar margin which further suggested it to be dentigerous cyst [Figure 1].

Surgeon decided to perform cystectomy instead of marsupialisation because of large size. Cystectomy specimen was sent for histopathology for confirmation.

On gross specimen was measuring 10x 8x 7cm in size with well defined, encapsulated and entirely cystic mass. Cystic wall was thickened at places but no solid areas seen [Figure 2 & 3]. Intralesional unerupted tooth was also noted. Random sections were studied under light microscope. Lesion showed throughout fibrous capsule with complete cystic mass showing multiple nests of epithelial cells with round to oval uniform basal nuclei and eosinophilic cytoplasm. Few areas reveal tubule formation or adenomatoid change. These nests were surrounded by pools of eosinophilic fibrillar material- amyloid like areas and Liesegang ring formations (calcifications). All these features were consistent with adenomatoid odontogenic tumor- intraosseous variant [Figure 4-7]. Due to complete cystic nature of tumor it was misdiagnosed clinically as dentigerous cyst. Therefore, final diagnosis of cystic adenomatoid odontogenic tumor was made and patient was followed up for one year for any recurrence.

Till date patient did not complain any recurrence.

### Discussion

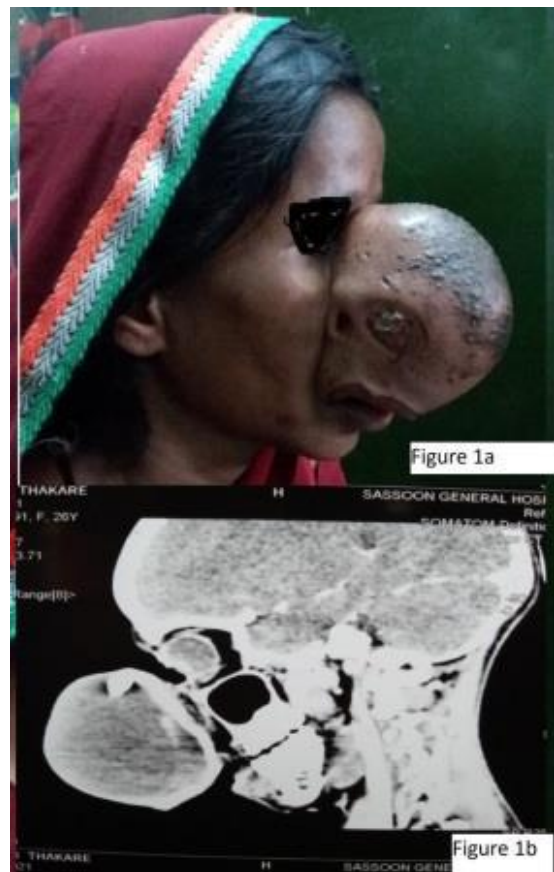Adenomatoid odontogenic tumor is a rare tumor that comprises only 0.1% of tumors and cysts of the jaw and 3% of all odontogenic tumors [1]. It is an uncommon cause of jaw swelling. Common causes of cystic jaw swelling are apical cyst, dentigerous cyst, calcifying epithelial odontogenic cyst and odontogenic keratocyst all of which are non neoplastic in nature.

There are three clinicopathologic variants of AOT, namely intraosseus follicular, intraosseous extrafollicular and peripheral, all with identical histology. The follicular type is a central intraosseus lesion associated with an impacted tooth, while extrafollicular intraosseous AOT has no relation with an unerupted tooth. In spite of this, it is often located between, above or superimposed upon the roots of adjacent erupted teeth. The peripheral variant appears as a gingival fibroma or epulis attached to the labial gingival mucosa [3]. The follicular and extrafollicular variants account for 96% of all AOT cases (of which 71% are follicular). Follicular and extrafollicular variants together are more commonly found in the maxilla than in the mandible (2.1:1 ratio). More than two thirds are diagnosed in the second decade, mostly in the 13-19 year age group. The female: male ratio is 1.9:1 [3]. Even higher ratios are found in Asian populations, the highest incidence being observed in Sri Lanka (3.2:1) [4] and Japan (3:1) [5]. The tumor is usually associated with unerupted teeth, frequently canines or lateral incisors. Irregular root resorption is seldom reported [1, 6]. The patient we describe in this report also presented resorption of the upper left lateral incisor. Radiologically, it should be differentiated from dentigerous cyst, which most frequently occurs as a pericoronal radiolucency in the jaws with complete radiolucency [8].

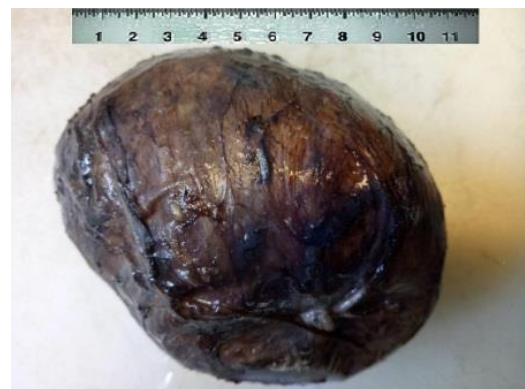Common neoplastic causes, such as ameloblastoma, calcifying epithelial odontogenic tumor (CEOT), ameloblastic fibroma and ameloblastic fibro odontoma are easily differentiated on histology. CEOT shows larger and more numerous calcifying spherules within eosinophilic cytoplasm of large cells along with smaller cells with hyperchromatic nuclei. Amyloid-like eosinophilic material is also present. Ameloblastoma has characteristic lining and arrangement with stellate reticulum besides usual location in mandible and posterior maxilla in contrast to AOT that is located in anterior maxilla [8]. Areas of CEOT-like tissues have been described in classic AOT. Dentigerous cyst does not show odontogenic epithelial lining while AOT consists of nests of odontogenic epithelium with adenoid pattern.

Immunohistochemical and ultrastructural findings have shown that the eosinophilic deposits (amyloid-like material) have origin from enamel matrix. The histogenesis of AOT is still uncertain, although recent findings strongly indicate that AOT is derived from a complex system of dental laminae or its remnants. It is often considered as a hamartomatous lesion rather than a true neoplasm [9]. All variants of AOT are well encapsulated and show an identical benign behavior. Complete cystic nature of tumor is very rare which is seen our case. Conservative surgical enucleation or curettage is the treatment of choice with only rare recurrence [3]. The patient we described in this case report is healthy without recurrence and is under follow-up after local excision.

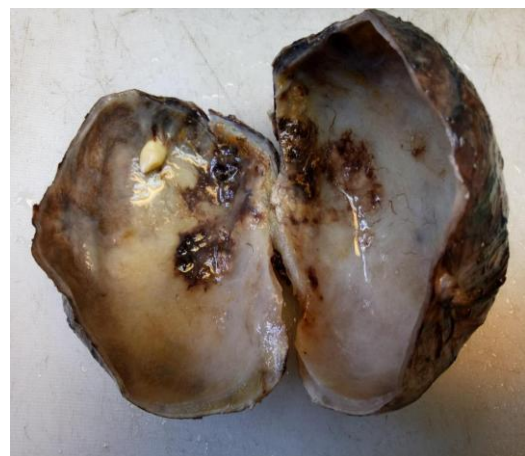We conclude that AOT should also be considered in the differential diagnosis of radiolucent jaw swellings, although its incidence is low.



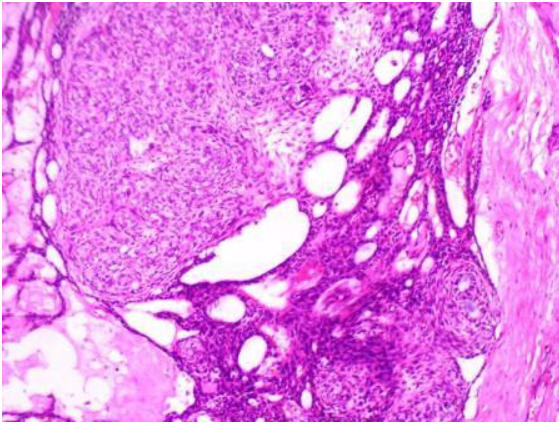
**Fig 1:** a) Clinical photograph of patient b) CT scan image of swelling



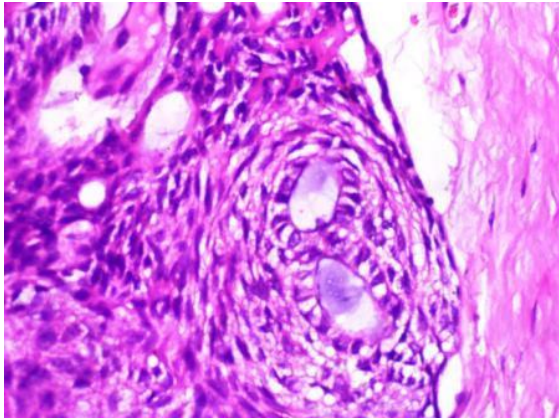
**Fig 2:** Gross image of external surface.



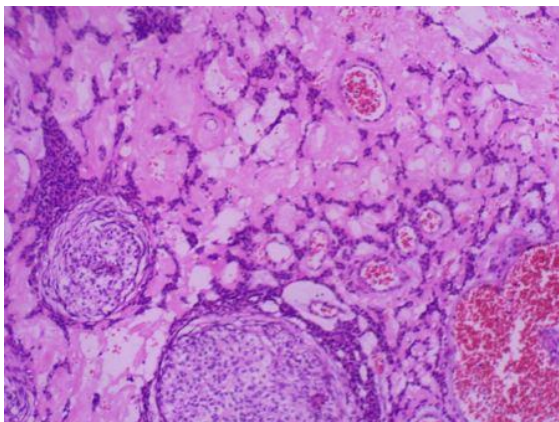
**Fig 3:** Gross image of cut surface.



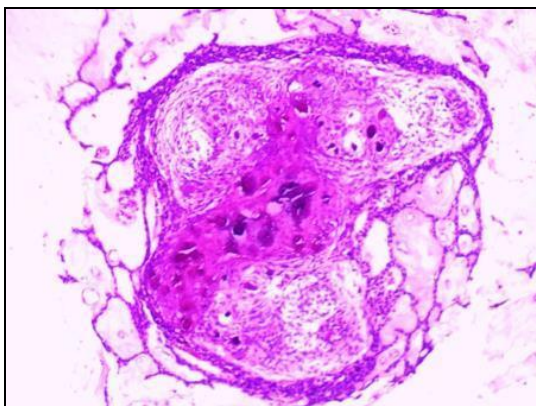
**Fig 4:** Microscopy H&E 100X



**Fig 5:** Microscopy H&E 400X



**Fig 6:** Microscopy H&E 40X



**Fig 7:** Microscopy H&E 40X

## References

1. Dayi E, Gurbuz G, Bilge OM, Ciftcioglu MA. Adenomatoid odontogenic tumour (Adenoameloblastoma). Case report and review of the literature. *Aust Dent J* 1997; 42:315-318.
2. Mutalik VS, Shreshtha A, Mutalik SS, Radhakrishnan R. Adenomatoid odontogenic tumor: A unique report with histological diversity. *J Oral Maxillofac Pathol.* 2012; 16(1):118-21.
3. Philipsen HP, Reichart PA. Adenomatoid odontogenic tumour: facts and figures. *Oral Oncol.* 1998; 35:125-131.
4. Mendis BRRN, MacDonald DG. Adenomatoid odontogenic tumour: A survey of 21 cases from Sri Lanka. *Int J Oral Maxillofac Surg.* 1990; 19:141-143.
5. Toida M, Hyodo I, Okuda T, Tatematsu N. Adenomatoid odontogenic tumor: report of two cases and survey of 126 cases in Japan. *J Oral Maxillofac Surg.* 1990; 48:404-408.
6. Nomura M, Tanimoto K, Takata T, Shimosato T. Mandibular adenomatoid odontogenic tumor with unusual clinicopathologic features. *J Oral Maxillofac Surg* 1992; 50:282-285.
7. Lee JK, Lee KB, Hwang BN. Adenomatoid odontogenic tumor: A case report. *J Oral Maxillofac Surg* 2000; 58:1161-1164.
8. Rosai J. Mandible and Maxilla. In: Ackerman's Surgical Pathology. Rosai J (Editor). 8th ed. St. Louis: Mosby; 1996, 257-288.
9. Philipsen HP, Samman N, Ormiston IW, Wu PC, Reichart PA. Variants of the adenomatoid odontogenic tumor with a note on tumor origin. *J Oral Pathol Med* 1992; 21:348-352.