



International Journal of Applied Dental Sciences

ISSN Print: 2394-7489
ISSN Online: 2394-7497
IJADS 2019; 5(3): 282-283
© 2019 IJADS
www.oraljournal.com
Received: 01-05-2019
Accepted: 03-06-2019

Dr. Amit Kumar Singh
Assistant Professor,
Oral Medicine and Radiology
Department Buddha Institute of
Dental Science, Patna, Bihar,
India

Dr. Rashi Chauhan
Assistant Professor,
Orthodontic Department
Buddha Institute of Dental
Science, Patna, Bihar, India

Dr. Khushbu Rani
Post Graduate Student Oral
Medicine and Radiology
Department Buddha Institute of
Dental Science, Patna, Bihar,
India

Dr. Kriti Singh
Post Graduate Student Oral
Medicine and Radiology
Department Buddha Institute of
Dental Science, Patna, Bihar,
India

Correspondence
Dr. Khushbu Rani
Post Graduate Student Oral
Medicine and Radiology
Department Buddha Institute of
Dental Science, Patna, Bihar,
India

Stafne bone cyst: A case report

**Dr. Amit Kumar Singh, Dr. Rashi Chauhan, Dr. Khushbu Rani and
Dr. Kriti Singh**

Abstract

Stafne's cyst defined as static lesions located in the angle of mandible. Range from 0.10 to 0.48%. Male to female ratio 4:1. Asymptomatic lesion occurs in the 5th and 6th decade of life. Lesions of size vary between 0.5cm to 2.0 cm in diameter. This lesion is diagnosed from radiograph at the typical site and shape and clearly differentiate from the surroundings structures. CBCT, OPG scans are important tools for confirmation of these lesions.

Keywords: Stafne bone cyst, case report

Introduction

Stafne bone cyst was first described by stafne in 1942. he reported 35 asymptomatic unilateral radiolucent lesion in the posterior region of mandible located between the mandibular angle and third molar, below the inferior alveolar canal and above the base of mandible. The etiology of stafne bone cyst was unknown. Radio graphically, stafne cyst shape are unilocular round or ovoid. Corticated border are thick and vary in diameter 1-2cm.

Case - Report

71 year old male patient Ramadhar Prasad came to the department of Oral Medicine and Radiology Department. With chief complain of sensitivity in both upper and lower jaw since 15 days. Patient also gave history of pain in lower right back region of jaw. Nature of pain was dull and intermitted in nature and relief by medication. Patient gave no history of trauma. On Extra-oral Examination and Intra-oral Examination no changes were seen in that region. Impacted tooth seen wrt 48.

Discussion

Stafne bony defect was first described by stafne in 1942. the exact etiology of stafne cyst was unknown. Stafne propose that the cavity could be result from a failure of normal bone deposition in that region previously occupied by cartilage. The most widely obtain perspective is that the cavities develop as a result of a localized pressure lead to atrophy of the lingual surface of the mandible and adjacent to salivary gland. The exact pathogenesis is still unknown and some author suggested that a part of the salivary gland becomes trap during the growth of the mandible but in our case we unable to recuperate any bony expansion along with cortical thinning. A incidence rate of SBD of 0.08% was determined in different studies.

Conclusion

Stafne bone defect was an incidental finding, presenting no developmental changes, and conservative treatment based on regular controls was indicated. OPG & CBCT are sufficient for diagnosis.



Fig 1: Extra-Oral Profile Photo of Patient

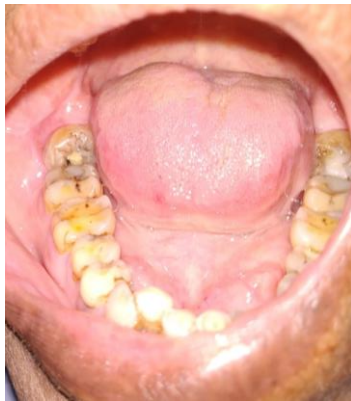

Fig 2: Intra-Oral Photograph

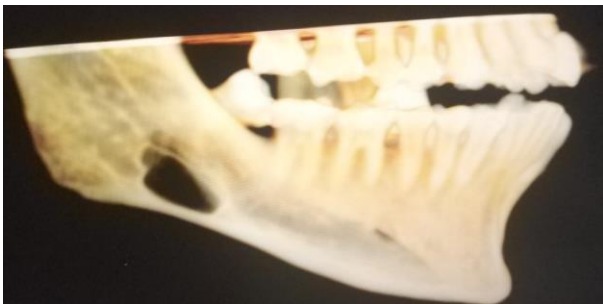

Fig 3: 3D CBCT Showing Defect In Right Posterior Mandibular Body Ramus Region.

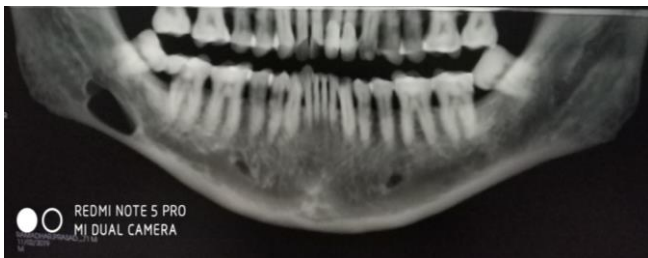


Fig 4: OPG Showing Radiolucency in Right Posterior Mandibular Body Ramus Region

References

1. Stafne EC. Bone cavities situated near the angle of the mandible Am Dent Assoc 1942; 29:1969-1972.
2. Branstetter BF, Weissman JL, Kaplan SB. 'Imaging of a Stafne bone cavity; what MR adds and why a new name is needed, American Journal of Neuroradiology. 1999; 20(4):587-589.