



ISSN Print: 2394-7489  
ISSN Online: 2394-7497  
IJADS 2019; 5(3): 299-302  
© 2019 IJADS  
www.oraljournal.com  
Received: 13-05-2019  
Accepted: 15-06-2019

**Dr. Amruta AG**

Post Graduate, Department of  
Prosthodontics, Final Year,  
D Y Patil University, D Y Patil  
School of Dentistry, Nerul, Navi  
Mumbai, Maharashtra, India

**Dr. Rajeev S**

Professor, Department of  
Prosthodontics, Final Year,  
D Y Patil University, D Y Patil  
School of Dentistry, Nerul, Navi  
Mumbai, Maharashtra, India

**Dr. Gaurang M**

HOD and Professor, Department  
of Prosthodontics, Final Year,  
D Y Patil University, D Y Patil  
School of Dentistry, Nerul, Navi  
Mumbai, Maharashtra, India

**Dr. Omkar S**

Dean and Professor, Department  
of Prosthodontics, Final Year,  
D Y Patil University, D Y Patil  
School of Dentistry, Nerul, Navi  
Mumbai, Maharashtra, India

**Correspondence**

**Dr. Amruta AG**

Post graduate, Final Year,  
D Y Patil University, D Y Patil  
School of Dentistry, Nerul, Navi  
Mumbai, Maharashtra, India

## Tooth supported overdenture: A case report

**Dr. Amruta AG, Dr. Rajeev S, Dr. Gaurang M and Dr. Omkar S**

### Abstract

Preventive prosthodontics emphasizes the importance of any procedure that can delay or eliminate future prosthodontic problems. The overdenture is defined as a removable partial denture or complete denture that covers and rests on one or more remaining natural teeth, the roots of natural teeth and / or dental implants. The overdenture is a scientifically sound treatment option when preventive prosthodontics is concerned. This article represents a case report in which maxillary overdenture is fabricated using prefabricated titanium posts and clear retentive caps whereas mandibular overdenture is fabricated using a hader bar and positioning clips. All the attachments provided in the denture helps in better retention and stability of the denture.

**Keywords:** Trial denture, prefabricated titanium posts, ball attachment, clear nylon caps, hader bar, positioning clip, metal housing

### Introduction

#### Tooth Supported Overdenture- A Case Report

An overdenture defined as a removable prosthesis that covers the entire occlusal surface of a root or implant (GPT 9). According to De Van dictum "preservation of what is there is more important than meticulous replacement of what is missing." According to a study conducted by Crum and Rooney (1973-1978), an average of 0.6 mm of bone resorption happened in anterior part of mandible for patients with overdentures whereas patients with complete dentures lost an average of 5.2 mm bone loss <sup>[1]</sup>.

### Advantages of Overdentures

1. Psychological benefits to the patient
2. Effect upon edentulous ridge- Decreased bone resorption
3. Tactile discrimination – improved proprioception
4. Improved stability and retention of the denture <sup>[3]</sup>

### Planning of the next stages of therapy can be divided into situations where

1. The patient is already wearing a partial denture
2. The patient has no partial denture

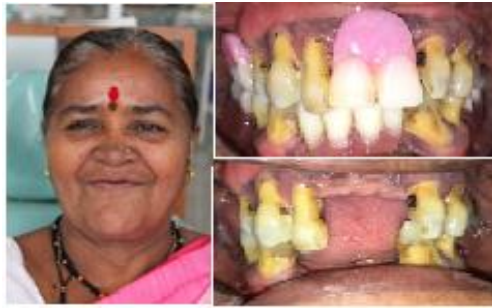The treatment is considerably simplified when the patient already wears a partial denture. Adaptation to wearing a prosthesis will have occurred and this will be a great help in transition to an overdenture <sup>[3]</sup>.

### A Case Report

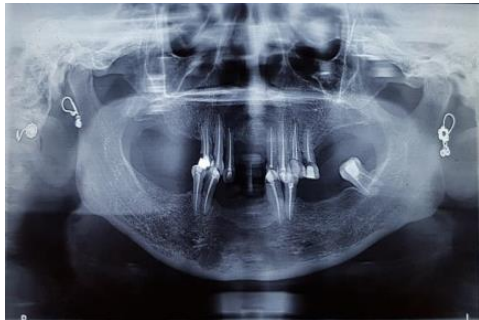
A 60 years old female patient reported with chief complaint partially edentulous upper and lower arches with already existing ill fitting removable partial dentures and requested for a complete denture.

Picture (1.1) shows extraoral picture of the patient, intraoral picture with previous denture whereas shows without the previous denture. Preoperative OPG shows all present teeth endodontically treated, healthy but periodontally poor (1.2)

As the patient was complaining of previous ill fitting denture, to improve the retention and longevity of prosthesis by retaining teeth present and providing support to the periodontium instead of extracting them. Then these teeth were planned to use for placing attachments. There were multiple options available like mangets, ball and socket attachment and bar.



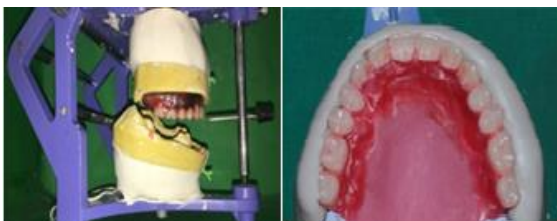
**Fig 1.1:** Extraoral and intraoral preoperative pictures



**Fig 1.2:** Preoperative OPG

Diagnostic impression was made using alginate. A diagnostic jaw relation was recorded and a trial denture was made by chopping off teeth on the models on three point articulator to check for the space available for the attachments as overdentures are space sensitive. (Picture 1.3)

In overdenture, there should be minimum 6 mm space available coronal to the attachments to accommodate for the counterpart of the attachment, acrylic and teeth. After evaluating the periodontal and endodontic status of all teeth as well as with the reference of trial denture, the space available was obtained as 9 mm in mandible on an average after measuring at all the locations from the alveolar ridge to maxillary occlusal plane. And it was evaluated that there was 7 mm of space on an average from maxillary ridge to mandibular occlusal plane. Then depending on the financial availability of the patient prefabricated titanium ball and socket attachments with intra-radicular posts for maxillary selected abutments and hader bar for the mandible was chosen.

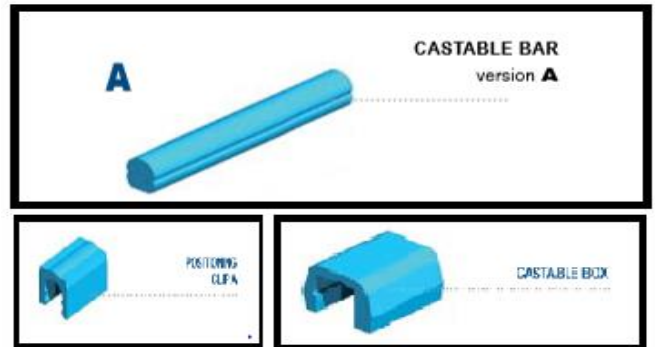


**Fig 1.3:** Maxillary Trial denture in a place showing the space available and the putty index made for the reference

According to the space available and periodontal and endodontic status of all the present teeth, ball and socket attachment for maxillary teeth for 13, 23 and 24 as these teeth had good bone support, favourable crown to root ratio. (1.4) For mandible, a hader bar with 33,34 and 43,44 as abutments (1.5) and a protective metal coping on 38 were planned. All potential abutment teeth should be evaluated carefully from the viewpoints of: (i) periodontal status; (ii) caries activity; (iii) potential for endodontic treatment and (iv) positional considerations [2].

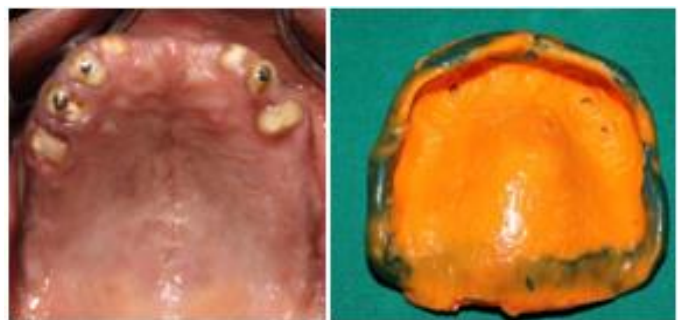

**Fig 1.4:** Maxillary Rhein 83 attachments- first picture shows prefabricated titanium posts with micro ball attachment with diameter of 1.8 mm available in 3 different lengths, then Mooser burs for canal preparation and clear retentive caps in normal(with retention of 1200 to 1300 gms) and micro size(with retention of 1000 to 1100 gms) [4]



**Fig 1.5:** Mandibular Rhein 83 Attachments- first picture shows a castable hader bar which will be connecting the abutments then a blue positioning clip with standard retention and a castable box which will be holding the positioning clip into the denture [4]

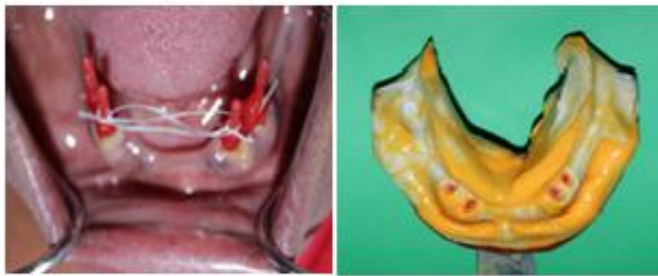Then teeth were trimmed by using trial denture index (1.3) and previous denture (picture a) as a reference for the vertical dimension followed by post space preparation was done and attachments were tried after the adjustments<sup>3</sup> (1.6) and remaining teeth were trimmed to the level of gingiva in the dome shape as they did not have good bone support and sealed with glass inomer cement and composite (1.6) followed by primary impression with irreversible hydrocolloid. Then a custom tray was fabricated on a primary cast and a pickup final impression was made with attachments in place (1.6).



**Fig 1.6:** ball attachments tried in 13,14 and 23 and final impression was made picking the attachment in impression

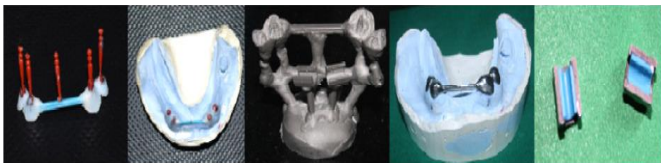For mandibular attachments, teeth were prepared for the bar by using trial denture index and previous denture as a reference for the vertical dimension and 4-5mm of gutta percha was removed from the root canals and parallel preparation was done for intraradicular extensions. Here it was needed to keep minimum 6 mm space over the coping which was assured using the index and a dome shape

preparation was done. To verify the parallelism and make impression, all 4 abutments were splinted using pattern resin (1.7) and a pickup impression was made using addition silicon (picture 1.7) to make a wax pattern for the bar and copings on abutment teeth.



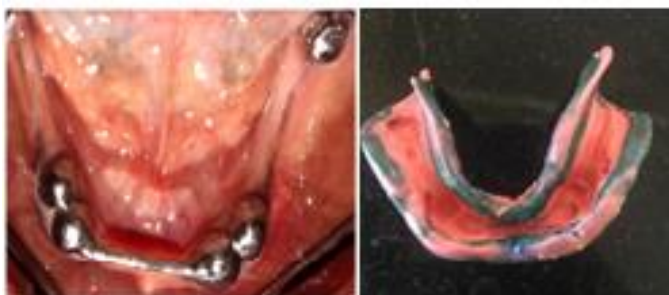
**Fig 1.7:** pickup impression was made using addition silicon (putty) after splinting of intra-radicular patterns with resin.

Wax pattern was made using prefabricated bar wax pattern keeping 2-3 mm of space beneath the bar for self cleansing, again verified for the parallelism using parallelogram, and then casting was done, the bar with parallel copings was then finished polished and tried in patient's mouth. (1.8)



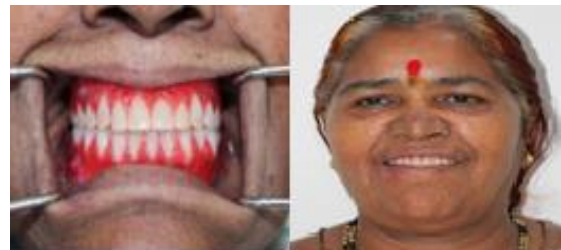**Fig 1.8:** From left- Wax pattern was made, casted along with the metal housing for positioning clips, trimmed and polished, tried on the cast along with positioning clips with metal

After trial of the bar with splinted copings and the coping on 38 in patient's mouth (1.9). Attachment was not planned on 38 as there was no enough space available according to the requirements and 38 was tilted tooth so to correct the tilt space requirement is even more using telescopic copings. A pickup impression was made using irreversible hydrocolloid, a cast was poured and a custom tray was fabricated. Then mandibular border moulding was done with low fusing green stick compound and a final impression was made by using light body. (1.9)



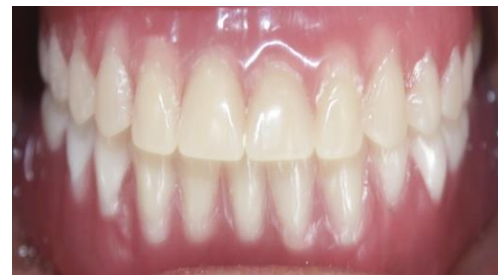**Fig 1.9:** The Hader bar was tried and cemented with temporary cement along with the metal coping on 38 and final impression was made following the border moulding using light body.

Then both maxillary and mandibular record bases were made and jaw relation was recorded using check bite method. Then facebow was recorded and transferred to the semi-adjustable articulator. Denture try in was done to check aesthetics, function and speech. (1.10)



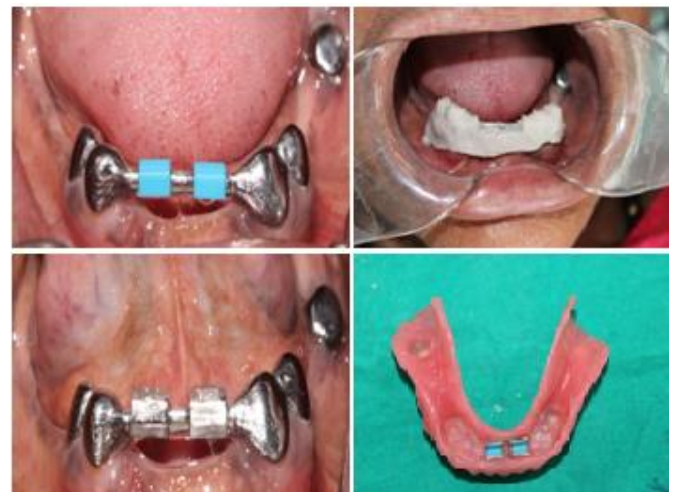**Fig 1.10:** intraoral and extraoral pictures showing denture try-in.

Final denture was fabricated using heat cure acrylic. All the attachments were cemented using resin modified glass ionomer cement. The denture was relieved around the attachments to avoid gingival impingement, minor occlusal adjustments were done and delivered. (1.11) Then the patient was appointed after 3-4 days for the pickup of nylon caps on ball attachments in maxilla and the positioning clips on bar in mandible.



**Fig 1.11:** intraoral picture showing denture delivery.

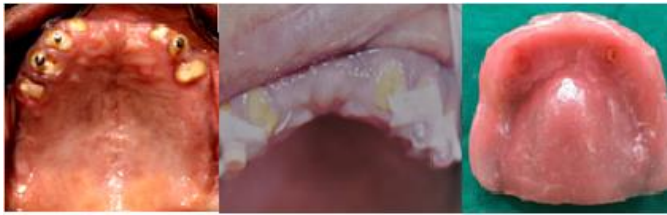The positioning clips were placed verifying correct position over the grooves in the bar, over which the metal housing was placed which will be picked up in the relieved denture. Then under surface of the bar and undercuts around were blocked out using addition silicone (putty). (1.12)



**Fig 1.12:** intraoral pictures showing positioning clip and metal housing in place and the the blockout using addition silicone putty. Then the next picture shows pickup of the metal housing along with positioning clips in mandibular denture

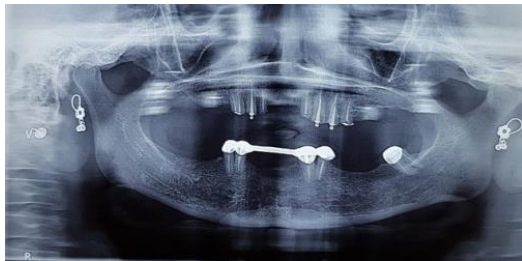And the metal housings along with positioning clips were picked in the denture using cold cure acrylic. (1.13) For maxillary attachments, the nylon caps were placed over the ball attachments and the denture was relieved in the same areas followed by the undercuts block out using rubber dam small pieces, wax and petroleum jelly as a separating medium. The pickup of nylon caps in denture by putting

required amount of cold cure acrylic in the denture. (1.13)  
 During both maxillary and mandibular pickups, its is made sure that both upper and lowe dentures are closing in centric relation.



**Fig 1.13:** intraoral picture showing attachments in place followed by nylon caps in place with blockout done using rubberdam sheet and the denture showing pickup of nylon caps.

Picture (1.14) shows postoperative OPG showing titanium posts with ball attachments with 13, 23 and 24; hader bar in the mandible connecting 33, 34 to 43, 44 and a protective metal coping on 38.



**Fig 1.14:** Postoperative

Following picture shows extra oral postoperative pictures of the patient.



**Fig 1.15:** Extraoral post-operative

### Discussion

Overdenture is a space sensitive treatment modality so correct diagnosis and attachments selection is of major importance. In maxilla, depending on the periodontal and endodontic status of teeth abutments were selected after evaluating the crown to root ratio which would be achieved after preparing teeth for attachments (minimum 1:1 ratio was targeted to achieve). Accordingly 13, 23 and 24 were selected. Then we had an option of doing thimble shaped or dome shaped preparation but thimble shaped preparation is done when greatest amount of vertical and bucco-lingual space is available [3] (in telescopic coping). This vertical preparation was done using the index of trial denture as the reference. So all the maxillary abutments were prepared in dome shape and gutta percha in the root canal was removed to fit the

attachement. Remaining teeth were trimmed to the gingival level, sealed with Glass Inomer Cement and composite.

In mandible, 33, 34 and 43, 44 were splinted to aid for additional retention and splinting increases the longevity as the forces are well distributed on all the abutments. Here all the 4 teeth were prepared in dome shape using the trial denture index as the reference as mentioned earlier and then intraradicular extentions of around 4-5 mm were prepared in all teeth for additional retention. The preparation was done parallel. If abutments cannot be made parallel then telescopic copings is the solution. 2-3 mm of space was left beneath the bar for keeping it self cleansing for the patient. A protective coping was made on 38. When only single coping is given usually it does not help in retention but if the telescopic copings are used then it improves the retention as well. Here 38 being a vital tooth, only a protective coping is given.38 being a tilted tooth,to correct the tilt, a telescopic coping was supposed to be given but it was not possible because of inadequate space availability in that area.

During pickup of the female components of the attachment, correct blockout of the undercuts is very important for the easy retrieval of prosthesis after the pickup. (1.12 & 1.13) As well as it is made sure that patient is closing into centric relation till the cold cure acrylic sets. If this is not assured then the pickup needs to be repeated when the patient is closing in centric relation.

After the prosthesis has been worn for a period of time, retention may decrease as a result of wear, in that situation the female attachment can be easily replaced and the retention can be improved. Patient is recalled for the follow-up after every 3-4 months.

### Conclusion

In cases of partially edentulous patients, giving a traditional removable partial denture further degrade the prognosis of present teeth. Whereas planning the overdenture improves the crown root ratio of present teeth, improves proprioception, decreases the bone resorption and increases the retention as well. But this treatment option has some disadvantages if the treatment is not planned properly like loosening of the abutment teeth,etc.

### References

1. Robert J, Crum DDS, George E, Rooney Jr DDS. The Journal of Prosthetic Dentistry, December Alveolar bone loss in overdentures: A 5-year study Author links open overlay panel, 1978; 40(6):610-613
2. Juliana PA, Henking. BSc, BDS School of Dentistry (Queen's University of Belfast), Royal Victoria Hospital, Belfast Journal of Dentistry, Printed in Great Britain, Overdentures 1982; 10(3):217-225
3. Harold W. Preiskel,Overdenture made easy- A guide to implant and root supported prostheses
4. RHEIN 83-Technical Manual - prefabricated castable attachments and implant components