



# International Journal of Applied Dental Sciences

ISSN Print: 2394-7489  
ISSN Online: 2394-7497  
IJADS 2019; 5(3): 370-378  
© 2019 IJADS  
www.oraljournal.com  
Received: 09-05-2019  
Accepted: 13-06-2019

**Abu-Hussein Muhamad**  
Universitätsklinikum Würzburg,  
Klinik und Polikliniken für  
Zahn-, Mund- und  
Kieferkrankheiten der Julius-  
Maximilians-Universität  
Würzburg, Germany, University  
of Debrecen/ Hungary, Faculty  
of Dentistry of the University of  
Sevilla/Spain, Arab American  
University/ Jenin, Palestine

**Nezar Watted**  
Universitätsklinikum Würzburg,  
Klinik und Polikliniken für  
Zahn-, Mund- und  
Kieferkrankheiten der Julius-  
Maximilians-Universität  
Würzburg, Germany, University  
of Debrecen/ Hungary, Faculty  
of Dentistry of the University of  
Sevilla/Spain, Arab American  
University/ Jenin, Palestine

#### Correspondence

**Abu-Hussein Muhamad**  
Universitätsklinikum Würzburg,  
Klinik und Polikliniken für  
Zahn-, Mund- und  
Kieferkrankheiten der Julius-  
Maximilians-Universität  
Würzburg, Germany, University  
of Debrecen/ Hungary, Faculty  
of Dentistry of the University of  
Sevilla/Spain, Arab American  
University/ Jenin, Palestine

## Serial extraction in orthodontics

**Abu-Hussein Muhamad and Nezar Watted**

#### Abstract

Serial Extraction or the guidance of eruption is an age old procedure to correct crowded arches and is still used in routine dental practice. But the efficacy of this procedure has always been controversial and it requires very precise clinical skill for a favorable outcome. This article presents a review regarding the proper selection of cases for serial extraction, its limitations and various adjuncts that are required to get good results.

**Keywords:** Serial Extraction, primary teeth, mixed dentition, developing malocclusion

#### Introduction

Therapeutic extraction can be defined as the removal of the teeth for the purpose of orthodontic treatment. Certain sound healthy teeth may have to be extracted to facilitate proper alignment of other teeth in case of severe arch length-tooth material discrepancy or correction of sagittal relationship. Before planning extraction of any permanent teeth, it is essential to ensure that all permanent teeth are present and developing appropriately<sup>[1]</sup>.

Balancing extraction can be defined as the removal of the contralateral tooth on the opposite side of the same arch (although not necessarily the same) in order to prevent midline shift and preserve the symmetry<sup>[2]</sup>. If a tooth is removed from one side of the dental arch which is crowded or which has complete contact of teeth all around, there is a tendency for the remaining teeth to move toward the extraction space, this in form of forward movement of teeth behind the space and movement of anterior teeth across the center of the arch resulting in asymmetry. It is usual to balance extractions in order to prevent such asymmetry<sup>[2,3]</sup>.

If the dental arch is spaced, there is no need for balancing extraction since there is no tendency for remaining teeth to move toward the extraction space<sup>[4]</sup>.

Compensating extraction can be defined as the removal of the equivalent tooth from the opposing arch on the same side to maintain the occlusal relationship (buccal occlusion) between upper and lower arches<sup>[3]</sup>. In some cl I crowding cases, it is necessary to extract in both arches to maintain occlusal relationship (lateral symmetry). Compensating extractions preserve inter-arch relationship by allowing the posterior teeth to drift forward together<sup>[5]</sup>.

Serial extraction can be defined as sequential removal of some of the deciduous teeth followed by permanent teeth to guide the teeth in to normal position. This procedure is usually done at mixed dentition period<sup>[6]</sup>.

Serial extraction is defined as the planned and sequential extraction of certain deciduous teeth followed by removal of specific permanent teeth in order to encourage the spontaneous correction of irregularities<sup>[7]</sup>. This article presents a review regarding the proper selection of cases for serial extraction, its limitations and various adjuncts that are required to get good results.

#### Historical development

Serial extraction is not new. It has been of interest to dentist for many years. Throughout the history of dentistry it has been recognized that the removal of one or more irregular teeth would improve the appearance of the remainder<sup>[8,9]</sup>.

Paisson was the first person who pointed the extraction procedure in order to improve the irregular alignment and crowding of teeth. Bunon in 1743<sup>[10]</sup>, in his "Essay on the Diseases of the teeth" proposed the removal of deciduous teeth to achieve a better alignment of permanent teeth. The interest on serial extraction increased following World War II.

The names that stand out particularly for the modern development of the serial extraction concept are Kjellgren of Sweden Hotz of Switzerland, Heath of Australia and Nance, Hoyd, Dowel and Mayne of the United States [11, 12, 13].

Nance presented clinics on his technique of „progressive extraction“ in 1940 and has been called as the father of „serial extraction“ philosophy in the United States. Kjellgren in 1940 termed this extraction procedure as „planned“ or „progressive“ extraction procedure of teeth [11, 12].

Hotz named the same procedure on “Guidance of eruption”. According to him the term guidance of eruption is comprehensive and encompasses all measures available for influencing tooth eruption [13]. Widespread adoption of serial extraction as a corrective treatment procedure continues to be a source of concern to all Pedodontists who are aware of its limitations as well as of its possibilities. The principle reason is that its application involves growth prediction. Every serial extraction diagnosis is based on the promise that future growth will be inadequate to accommodate all of the teeth in a normal alignment [1, 3, 5].

Serial Extraction should be diagnosed in the early mixed dentition period. It is most effective in Class I malocclusions. Especially where we find marked irregularity of anterior teeth, premature loss of one deciduous canine, mid line deviation, displaced lateral incisors, gingival recession and alveolar destruction of labial surface of anterior teeth. In such cases decrease in tooth mass improves the alignment of anterior teeth and the gingival tissues [6-9].

### Overview of dental development

- **Incisor liability:** The four maxillary permanent incisors are, on the average, 7.6 mm larger than the primary predecessors. For the mandibular incisor segment, the permanent successors are 6.0 mm larger. This difference was termed the Incisor Liability by Warren Mayne and it varies greatly from person to person [4].
- **Interdental spacing:** One of the first observation to be made on young patient. Interdental spacing may range from 0 to 10.0 mm in the maxillary arch, but averages about 5.0 mm. In the mandibular arch interdental spacing can range from 0 to 6.0 mm, averaging 3.0 mm. Lack of interdental spacing must be considered a serious handicap in achieving normal alignment [5, 5].
- **Inter canine width changes:** Between the primary and mixed dentitions there is an increase in arch width between the primary canines. For the maxillary arch, Inter canine widths correlate with the timing of the late mixed to early permanent dentition exchange. After 10 years of age there is little mandibular inter canine width change to be expected in either boys or girls [6] Figure 1
- **Arch length changes:** Distance around the arch from the mesial surface of one first permanent molar to the counterpart on the other side. Arch length may and generally does, change during the growth period. Changes vary considerably between individuals and between the maxillary and mandibular arches. In most cases, arch length actually decreases in the mandibular arch during the growth period [7].

### Review of literature

Dewel suggests that serial extraction can be applied in certain Class II and Class III irregularities but almost invariably only as a part of treatment already in progress. In class I serial cases active orthodontic treatment more often is postponed until a later date and frequently it can be omitted entirely. He

stated that mandibular arch is the final diagnostic guide, with particular emphasis on the harmonious relation of the mandibular incisor to the basal bone. Slight irregularity or moderate crowding are not abnormal but extreme crowding, gingival recession and premature loss of deciduous mandibular canines are not acceptable deviations from the normal [14, 15].

According to Lloyd (1956) patients with short arch lengths or very short intercuspid width would be suitable cases for serial extraction. He advised serial extraction to be done in all types of class I malocclusion and class II div I malocclusion that show a severe lack of arch length or severe lack of intercanine space in both jaws to accommodate the incisor teeth in non rotated position. They are further characterised by a good facial profile, the overbite ranges from slight to severe and age of patient is somewhere between 6 and 9 years [16].

Malocclusions that have lingually locked maxillary incisors i.e. anterior crossbite or buccal teeth in crossbite or that lack occlusion but show deficient arch length or lack of intercanine space are mechanically treated for a short period until the cross bite is changed and serial extraction is continued.

Bimaxillary protrusions show beneficial results from serial extraction procedure. A lip retracting exercise in these cases is helpful in the uprighting and lingual positioning of the incisors. It is suggested that a headplate be used to supplement the diagnosis.

Another type of malocclusion where serial extraction can be helpful is that in which mandibular arch has sufficient arch length with excellently aligned incisors but in which the maxillary arch shows a decided lack of space for the erupting lateral incisors due to forward eruption of buccal teeth rather than to lack of intercanine space. Early removal of maxillary deciduous canines will prevent the lingual locking of the maxillary permanent lateral incisors [16].

Maj and Luzi (1960) suggested that serial extraction should not be prescribed in those cases in which alveolar growth increments can be successfully stimulated and a good long lasting correction can be achieved with a full complement of teeth [17].

According to Mayne (1968), if the crowding is extremely severe, with irreparable insults occurring to the investing tissues, then logic demands the early removal of deciduous cuspids, permitting the most rapid unravelling of the crowded teeth and their greatest lingual adjustment, both these accomplishments will improve investing tissue health [18].

Proffit writes that only when there is extreme severe crowding of 10mm or more is there a chance that a reasonably satisfactory result can be achieved by serial extraction alone [2].

Dewel (1969) concluded that an authentic serial extraction case has markedly irregular anterior teeth, premature loss of one or more of the deciduous canines, various median line deviations, impacted or displaced lateral incisors, a gross reduction in arch length and frequently, gingival recession and alveolar destruction along the labial surfaces of one or both the central incisors.

Cephalometrically, the typical class I extraction case presents a flat or straight facial pattern and the incisors are vertical and in a more acceptable relation to the N-Pogonion facial plane [19].

Giorgio Maj (1970) advocated the removal of deciduous canines when lack of space for mandibular incisor is greater than 2.5 mm. This would allow better alignment of incisors and prevent any tissue damage in the region of malposed teeth [20].

Ruff (1976) concluded that in class I mixed dentition cases, decision for serial extraction should be made only after the size of unerupted teeth is determined and after at least one year of growth observations verified by cephalometric analysis. Cases with a discrepancy of 4 mm or more still have a chance, if the growth potential is good. Cases showing a greater arch length discrepancy will generally become extraction cases [21].

Odenrick and Troeme (1985) proposed when cephalometric evaluation indicates an orthognathic or retrognathic profile, slightly hyper divergent, with facial skeletal dimensions less than average, in a patient whose dental casts indicate above average incisor width, serial or early extraction therapy is one of the treatment modalities that may be considered [22].

Jacquelin and Berthet (1991) proposed that serial extraction has limited indications which need to be respected in order to preserve the child's future dental health. It is indicated for class I malocclusion with severe crowding or moderate crowding associated with bimaxillary protrusion [23].

### Borderline cases

According to Dewel (1969), borderline cases generally have good facial patterns, moderate loss of arch length, a good muscular environment and a satisfactory direction of skeletal growth. Drastic procedures should be avoided, all possible diagnostic records be secured and then place the patient under observation to determine whether his individual growth trend will make it possible for him to retain all of the teeth [19].

According to Maj (1970), a favorable element in the borderline cases is the presence of a space of 1-2 mm between unerupted second molar and the distal surface of the first molar [24].

Jacob Harris (1972) feels that lower arch presents the more difficult problem in determining whether or not a case will require extraction. Maxillary arch is often amenable to treatment with various types of headgear and/or palatal splitting devices in order to increase arch length [25].

Dewel (1976) suggests that if the dental arches are fairly well developed and if there is only a moderate discrepancy between tooth mass and supporting bone it may still be possible to retain all the teeth. If incisor alignment is also acceptable than the patient should only be placed under preliminary serial supervision in order to determine future growth trends. It will also help to avoid all extraction errors until a time arises when growth prediction can be established on a more rational basis [26].

Lieberman (1984) claimed that these borderline cases can be started without tooth extraction with a specific time limit set for reevaluation. The initial response to treatment may guide the orthodontist to continue on non extraction basis or to revert to tooth extraction. The term 'therapeutic diagnosis' has aptly been applied to describe this procedure [27].

### Limitations

Dewel (1954) commented that even when serial extraction is necessary, premature removal of teeth involves the risk of retarding future development in arches that are already deficient [28].

Bjork (1951) believes extraction of deciduous teeth for correction of crowding not justified as it retards the basal mandibular growth [29].

Dewel (1957) found that even when authentic serial extraction is indicated, premature removal of teeth involves the danger of retarding future development in arches that already are deficient. Also, prolonged absence of teeth in the premolar

region permits the tongue to flow into the space which results in a major problem in habit correction during the active stages of treatment [15].

Lloyd (1956) found that disadvantage of serial extraction is some lingual inclination of the incisor teeth particularly the mandibular incisors which cause their elongation and increased incisal overbite. Use of a lingual appliance may minimize lingual inclination [16].

Moorrees (1965) research showed that as the mandibular permanent incisors erupt the primary mandibular canines move laterally. When these teeth come into occlusion with the primary maxillary canines, they in turn are moved laterally (secondary spacing) and the space created enables the permanent maxillary lateral incisors to emerge into a favourable alignment. If the primary canines are extracted, when this natural phenomenon is occurring secondary spacing may not occur [30].

Salzmann (1966) wrote that since it is not possible to predict the exact time of tooth emergence on the basis of the root length of the teeth or the chronologic or skeletal age of the patient, extraction of deciduous molars actually can initiate malocclusion [31].

Ringenberg (1967) listed the disadvantages of serial extraction as increased overbite, lingual tipping of incisors, scar tissue in the extraction space, diastema and alteration of tongue function [32].

Mayne (1968) pointed out that inadequate attention has been paid to those situations which accounts for many cases of serial extraction resulting in 3-5 mm of spacing remaining in the extraction site. Space which must be closed through anterior movement of remaining posterior teeth [18].

Dewel (1969) concluded that active mechanotherapy has to be instituted to close the remaining spaces, to open the bite, upright teeth on either side of extraction sites and realign rotated and malposed incisors and canines. It has been disillusioning to learn that serial extraction, in itself rarely creates acceptable occlusal relation and that certain adverse reaction will result if procedure is not followed by comprehensive orthodontic treatment [19].

Freeman (1977) reported in a study of 1455 patients that only 1% of the patients treated with serial extraction would not need orthodontic treatment. 81% will need full banded orthodontic treatment [33].

Dewel (1976) reported that extraction decisions are much more difficult and demanding in the early mixed dentition than in the later permanent dentition [26].

Persson (1989) performed a longitudinal study on serial extraction cases and found that despite earlier tooth removal on average crowding developed to about the same degree as that of a non extraction normal occlusion sample [34].

Little, Riedel and Eugst (1990) evaluated the long term serial records of patients who had undergone serial extraction plus comprehensive treatment and retention and found that the anticipating future stability, the primary rationale for serial extraction, was not confirmed in their study. They realized that postretention irregularity is an inevitable response in cases with inadequate pre treatment arch length [35].

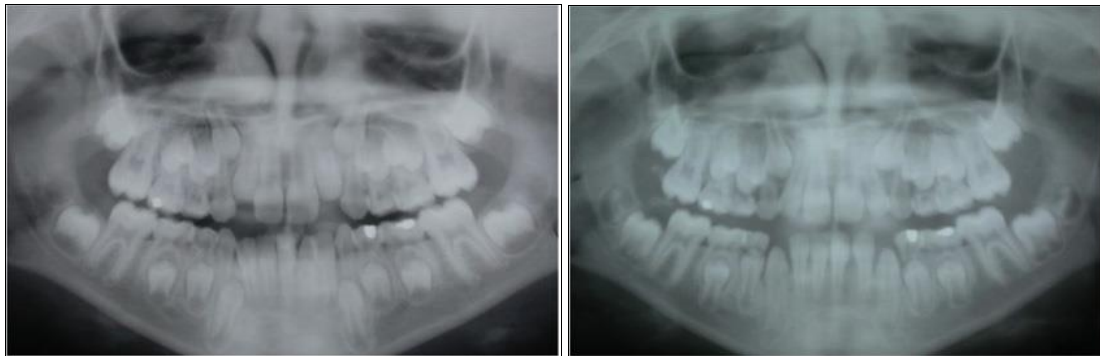
Grabner writes that the removal of the first premolar allows the tipping together of the crowns accentuating the "V" or "ditch". Seldom does the distance between the apex of canine and mandibular second premolar decrease on its own [3].

Hollander (1992) reported that although extraction of canine on the opposite side is advocated following unilateral loss of canine and has been taught for many years, no data exists to confirm that the midline will resolve automatically with

extraction of antimere leaving the stability of incisor symmetry in question. He says it would be more beneficial to leave the antimere intact<sup>[36]</sup>.

Wagner and Berg (2000) in a study found that the number of appointments was significantly higher and the total duration

of treatment/observation time was significantly longer for serial extraction cases than for extraction and orthodontic treatment done in permanent dentition. However the results and outcome of treatment was similar in both the groups<sup>[37]</sup>.

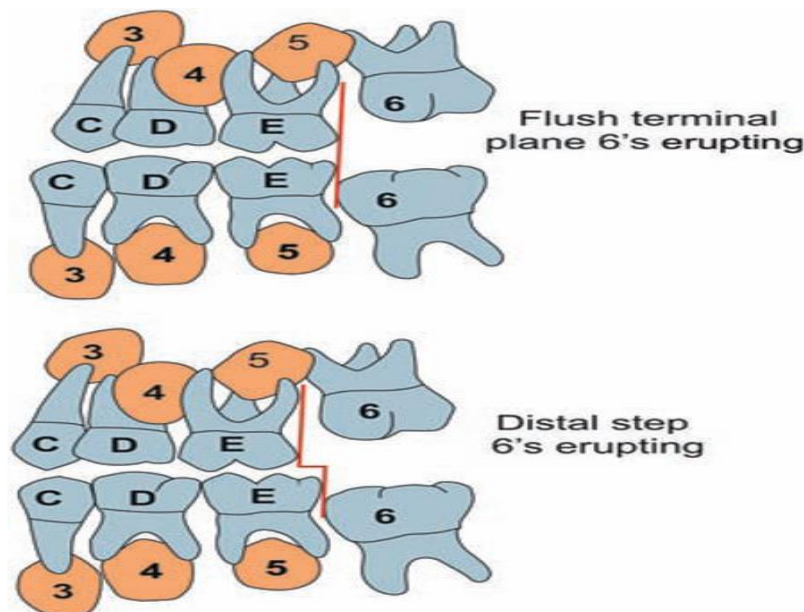


**Fig 1:** An example of a case where the upper arch was expanded, using a removable appliance (Shown), to correct a posterior crossbite, associated with a mandibular displacement, and to create space for the relief of mild maxillary crowding.

### Rationale of serial extraction

**1. Growth of jaws:** It is in Class I cases that serial extraction finds its most successful application. If there is a Class I malocclusion with generalized crowding in a normally growing child, the clinician would be most unwise to resort to

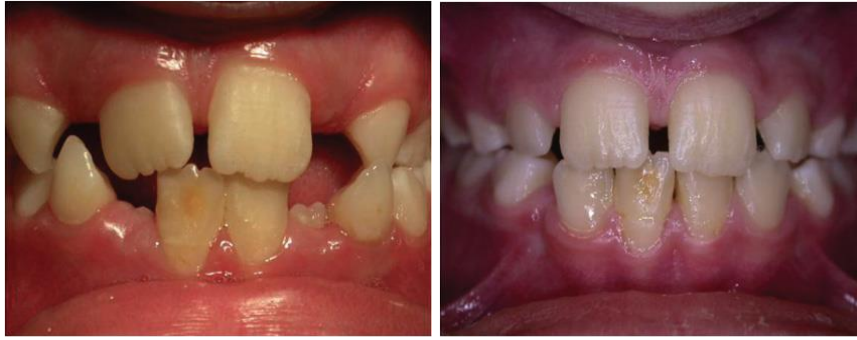expansion of the maxillary and mandibular arches with fixed or removable appliances. The normal growth of dental, skeletal and soft tissue influences the result of serial extraction<sup>[38]</sup>. Figure 2



**Fig 2:** Moyers has reported that at least 50% of normal developing dentitions have a flush terminal plane relationship that corrects itself only with the loss of the deciduous molars at the end of the mixed dentition period with the utilization of the leeway space. This Class II tendency may be accentuated with a distal step, if there is a morphogenetic Class II pattern or an excessively deep overbite and resultant functional retrusion.

**2. Dentitional adjustment in the anterior segment during first transitional period:** The fact that the permanent incisors are larger than the deciduous counterparts is quite obvious, even to the patient. Direct measurement of this incisor liability, as it is termed by Mayne, is possible and recommended. The deciduous-permanent tooth size differential averages 6–7 mm, even when there is no crowding. Any appreciable incisor liability, which would not get adjusted despite the contributions by the adjustment mechanisms, and strongly point to a program of guided extraction in the mixed dentition period<sup>[3]</sup>.

**3. Dentitional adjustment in the posterior segment during second transitional period:** The combined widths of the mandibular deciduous canine, first molar and second molar averages to 1.7 mm, that is, more than the combined widths of the three permanent successors. As Nance indicated, there is less width differential in the maxillary arch (average width difference 1 mm). This 'leeway space' exists on both sides, so it would average 3.4 mm in the mandibular arch and about 2 mm in the maxillary arch. 7 Can it be used for incisor crowding? This leeway space is required to correct the flush terminal plane relationship which is a normal, transient developmental phenomenon and is seen in a large percentage of cases<sup>[39]</sup>.

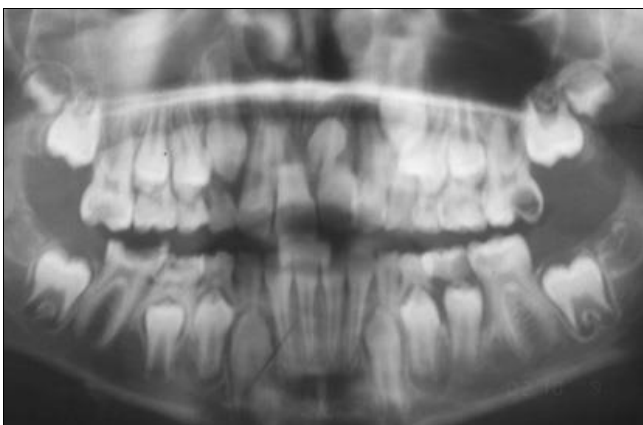


**Fig 3:** (a) There is a potential lack of space for eruption of the maxillary lateral incisors. (b) Early loss of the maxillary

When the permanent teeth replaces primary teeth, there is mesial shift of the mandibular first molar utilizing the leeway space and mesiobuccal cusp of the maxillary first molar locks into the mesiobuccal groove of the mandibular first permanent molar. The 'leeway space', then, is usually a reserved bit of arch length to allow for the adjustment of maxillary and mandibular dental arches during the critical tooth exchange period.<sup>7</sup> When this space is used, holding back the permanent mandibular molars to gain anterior arch length, it may very well have a Class II tendency and result in full Class II division 1 malocclusion. When the settling in the cusps and grooves is prevented, it may create premature contacts that intensify bruxism and functional problems<sup>[2]</sup>. Figure 3

**4.** Dental crowding is the result of inadequate arch size. Serial extraction aims to correct this discrepancy by reducing the tooth material. Why not intercept the developing malocclusion in the early mixed dentition by relieving crowding to provide a chance for nature to adapt with adequate space, instead of waiting for all permanent dentition to emerge into a full-blown malocclusion? The answer is conditionally corroborative. But, before commencing on this 'robbing Peter to pay Paul' technique, the orthodontists must question themselves<sup>[3]</sup>.

**5.** Physiological tooth movement or drifting occurs at the time and site of extraction. Teeth move both mesially and drift distally. This principle is being utilized in serial<sup>[1,2]</sup>.



**Fig 4:** Upper and lower first molars are grossly carious. Inter radicular crescent of the second molars is just forming. This would be an appropriate stage to extract the upper and lower first permanent molars as an interceptive measure.

#### Indications for serial extraction procedure

- Class I malocclusion with an arch size-tooth size deficiency of 5 mm or more per quadrant (10 mm or more for arch), normal eruption sequence as assessed

radiographically and a skeletal pattern within normal limits<sup>[1, 2, 3]</sup>.

- Tooth size- jaw size discrepancy with severe arch length deficiency which could be:
- True (hereditary) (non-pathologic) which is indicated by: unilateral or bilateral premature loss of deciduous canine, midline shift of mandibular incisors due to displaced lateral incisors, localized gingival recession in the labial aspect of lower anterior region, ectopic eruption of teeth, crowding of the anterior segment of arch, canine being blocked out labially<sup>[1,2]</sup>.
- Environmental (pathologic) which is indicated by: tooth ankylosis, mesial migration of permanent 1st molar following premature loss of deciduous molar or due to severe interproximal caries or improper filling that does not restore the ideal contour mesiodistally<sup>[3]</sup>.
- CI I malocclusion cases with maxillary mandibular alveolodental protrusion (bimaxillary alveolodental protrusion)<sup>[2]</sup>.
- In mesial step terminal plane in mixed dentition developed in to CI I permanent relationship with malocclusion<sup>[4]</sup>.
- CI II malocclusion cases if there is maxillary alveolodental protrusion while the mandibular dentition is normal, the serial extraction is indicated in upper arch only. extraction for self-correction<sup>[6]</sup> Figure 4.

#### Contraindications for serial extraction include

1. Congenital absence of teeth providing space
2. Mild to moderate crowding
3. Deep or open bites
4. Severe Class II, III of dental/Skeletal origin
5. Cleft lip and palate
6. Spaced dentition
7. Anodontia / oligodontia
8. Midline diastema
9. Dilacerations<sup>[1-7]</sup>

#### Advantages of serial extraction procedure

- More physiologic treatment as teeth are guided into normal positions using physiologic eruptive forces.
- Serial extraction allows the teeth to erupt over the alveolus and through -keratinized tissue, rather than being displaced buccally or lingually.
- Reduce the duration & cost of active orthodontic treatment at later stage.
- Health of investing tissues is preserved with less potential for iatrogenic orthodontic damage like root resorption, enamel decalcification.
- More stable result
- Less retention period is required.

- Better oral hygiene [1-6]

### Disadvantages of serial extraction procedure

- Long-term procedure that requires thorough knowledge of growth, development, eruption sequence and calcification of permanent teeth. No single approach can be universally applied.
- It is done as inter-canine growth is occurring and hence it is difficult to assess accurately how crowded the dentition will be.
- Prolonged treatment time with multiple visits (2-3 years).
- Patient cooperation is very important.
- Most cases treated by serial extraction need to be followed by active orthodontic treatment (fixed appliance) to achieve ideal leveling & alignment, root parallelism, closure of residual spaces, correction of deep bite
- Tendency to develop tongue thrust.
- Tendency to increase over bite (deepening of the bite).
- Residual spaces can remain between the canine and 2<sup>nd</sup> premolar.
- Subjecting the child to multiple progressive extraction visits [1-6].

### Tweed's method/Nance method

- Method involves the extraction of deciduous 1<sup>st</sup> molar around 8 year of age.
- Followed by the extraction of the 1<sup>st</sup> premolar & the deciduous canines.

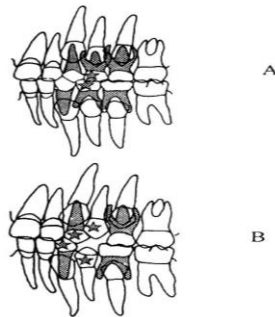


Fig 5: Serial extraction

### Diagnosis and treatment planning

Extraction of any tooth is a critical step in orthodontic management. Thus the decision of resorting to serial extraction should always be based on comprehensive assessment of dental, skeletal and soft tissues. Serial extraction is not a single-decision but a multi-decisional, time-lined process where factors such as the amount of crowding, arch length requirements, whether to extract the next set of teeth or not, and when to extract are reevaluated each visit by the patient. Thus serial extraction is a continuum of decision making process rather than a single-time diagnosis [36, 37, 38, 39].

The following investigations are recommended after a thorough clinical examination:

### Orthodontic study models

Moderate to severe arch length-tooth material discrepancy of not less than 5–7 mm should exist to undertake the serial extraction procedure.

Study models are required for:

- Assessing the morphology of teeth
- Assessing the dental arch form
- Evaluation of occlusion
- To perform model analyses—Carey's analysis in the lower arch and Arch perimeter analysis in the upper arch.

Mixed dentition analysis helps in determining the space requirement for erupting posterior teeth [1, 3, 39, 40].

### Radiographs

Various radiographic views recommended are:

- Intraoral periapical view
- Lateral cephalogram—to analyse the skeletal relation and direction of growth using cephalometric analysis. Orthopantomograph (OPG)
- To detect congenitally missing teeth and supernumerary teeth
- To carry out radiographic mixed dentition analysis
- To assess dental age
- To assess the amount of root development and possible eruption pattern
- To detect any bony pathologies [1, 3].

### Photographs

Pre, mid and post-treatment intra- and extra-oral photographs are taken. They act as permanent records of pre-treatment state, improvements during the procedure and also help in patient motivation [15].

### Procedure

A number of extraction sequences are in use and the choice of a particular method depends on individual case. No single extraction sequence applies to all patients. Some of the commonly used methods are described here.

- Dewel's method
- Nance method
- Tweed's method Figure 5
- Grewe's method.
- Moyers Method

### Dewel's Method (1978) (Extraction of CD4)

Dewel proposed a three-step serial extraction procedure in 1978. This is the most satisfactory order in most patients even today [14, 15, 19, 26, 28].

#### Step 1: Extraction of deciduous canines

In this step, the deciduous canines are extracted at around 8-9 years to create space for the alignment of the incisors. The main objective of extracting primary canines is to establish the integrity of upper and lower incisors. This prevents the development of lingual crossbite of maxillary laterals and resultant mesial migration of maxillary canines.

#### Step 2: Extraction of deciduous first molars

In this step, deciduous first molars are extracted when first premolars reach half of the root length as evidenced by radiographs. This would be some 12 months after the extraction of deciduous canines at around 9-10 years of age. The objective of deciduous first molar extraction is to accelerate the eruption of first premolars. This ensures that the first premolars emerge into oral cavity, before the eruption of permanent canines.

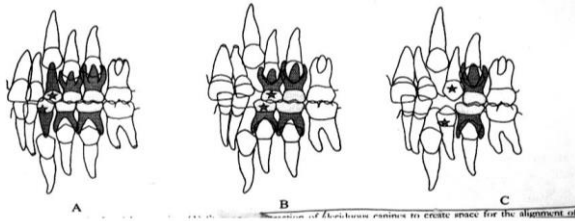
#### Step 3: Extraction of first premolars

In this step, first premolars are extracted as they are emerging into oral cavity and when the permanent canines have developed beyond half of the root length.

Extraction of first premolars facilitates proper eruption and alignment of permanent canines after serial extraction procedure, the teeth are fairly aligned. However, the

establishment of proper intercuspatation usually requires orthodontic mechanotherapy of minimal duration, although it may not be necessary in some cases. Figure 6

### Dewel's method



- 3 step serial extraction procedure.
- 1<sup>st</sup> deciduous canines are extracted.
- Deciduous 1<sup>st</sup> molar extracted a year later.
- Followed by extraction of erupting 1<sup>st</sup> premolar.

Fig 6: Serial extraction

### Nance method

Nance method of serial extraction is the modification of Tweed's method, which involves the extraction of the deciduous first molars, followed by the extraction of the first premolars and the deciduous canines [1, 3, 41, 42].

### Grewe's method

Grewe's method of serial extraction is based on the planning of extraction sequence for different clinical conditions [1, 3, 43, 44].

### Moyers method

#### Indications

When crowding seen in central incisor region. Fairly eruption of lateral incisors.

**Stage I:** (Extraction of all deciduous lateral incisors). It helps in alignment of central incisors [1, 44, 45].

**Stage II:** (Extraction of all deciduous canines after 7-8 months). It helps in alignment of lateral incisors and provides space for lateral incisors.

**Stage III:** (Extraction of all deciduous first molars). It stimulates eruption of all first premolars.

**Stage IV:** (Extraction of all first premolars after 7-8 months). It provides space for canines and stimulates eruption of canines.

#### In short

Step I ----- □ II ----- □ III ----- □ IV

Points to be considered when handling a case in mixed dentition: (Warren Mayne's four principles)

Incisor liability on an average is 7.6mm in maxillary. 6mm in mandibular.

Interdental spacing of 0.10mm in maxilla – avg 4mm 0.6mm in mandible – avg 3mm.

Intercanine width increased in mandible upto 9 years for male and female it increases by average 3mm. In maxilla it increases upto 12 years in female and 16 years in male. It amounts to 4.5mm.

Permanent incisors erupt labial to primary incisors by 2.2mm in maxilla and by 1.3mm in mandible.

Thus, to overcome problems associated with unfavourable eruption sequences and to counteract varying degrees of dentoalveolar disproportions many extraction sequences have been suggested:

a) C----- D ---- 4

b) C + D ----- 4

c) D ----- C + 4

d) C ---- D + Enucleation of 4

e) C ---- D ---- E ---- 4

f) C ----- D ----- No permanent tooth extraction

g) Occasionally some or all the permanent 2<sup>nd</sup> premolars are substituted for first premolar.

Where, C is the deciduous canine.

D is the deciduous 1<sup>st</sup> molar

E is the deciduous 2<sup>nd</sup> molar 4 is the first premolar

The list indicates that there is no ideal extraction sequence and that serial extraction treatment, is not an uncomplicated procedure [44, 45, 46, 47].

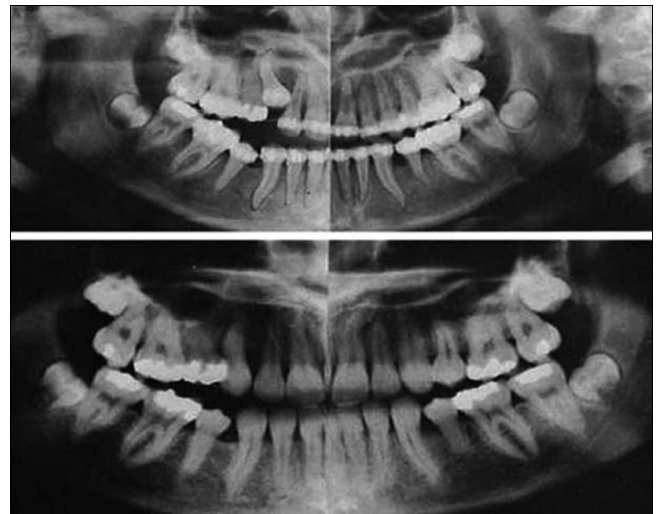

Fig 7: Canine on upper left is impacted, despite serial extraction procedures. Stringent and protracted mechanotherapy was required to achieve results shown in bottom view.

### Precautions

**Operator must always check that the permanent successors**

Are present. Of good quality. Of adequate morphology i.e. size and shape. At proper position. Have a sound, well-formed premolar when removed [1, 2, 7, 44].

### Enucleation

There are times when there is unilateral loss of deciduous canine, in such cases the other deciduous canine is extracted and the 1<sup>st</sup> premolar is enucleated. Enucleation has been defined as surgical removal of unerupted teeth usually premolar to minimize crowding. Most common disadvantage are loss of buccal or lingual cortical plates of bone or clefting associated with incomplete closure of extracted site [1, 3, 44].

### Advantages of enucleation

Fewer visits to the orthodontics therefore decrease in trauma and emotional disturbance. Fewer followup visits. In mandibular arch 3 usually erupts before 4. So if it is found that the 3 is erupting labially then premolar may be enucleated. (Diagnosis for 3 erupting labially-gingival recession of anterior and canine bulge on labial surface). In severe maxillary anterior crowding and excessive protrusion, enucleation provides space for retraction of 1 and 2 proper eruption of 3.

Retraction of 3 easier in crowded high angle cases, enucleation especially of 5 causes mesial migration of posterior segment [46, 47, 48]. Figure 7

**Class I: Malocclusion with premature loss of a mandibular deciduous canine**

Class I malocclusion with premature loss of a mandibular deciduous canine will result in midline shift, when the arch length discrepancy is 5-10 mm/arch, then the remaining deciduous canines should be extracted as the deciduous first molars are extracted next, if the first premolar have their roots more than half formed. If the roots of the first premolars are not developed more than half, then extractions of the deciduous first molar is delayed. The first premolars should be extracted as they emerge<sup>[49]</sup>.

**Class I: Malocclusion with severe mandibular anterior crowding**

Deciduous canines are extracted, when there is arch length deficiency and more than 5 mm per quadrant. The deciduous first molars are extracted next on completion of at least half of first premolar root formation and the extraction of first premolars follow as they erupt into the oral cavity<sup>[50]</sup>.

**Class I: Malocclusion where minimal mandibular anterior crowding is 6-10 mm arch deficiency**

In such conditions, the first premolars are extracted. The deciduous first molars are extracted when the roots of the premolars are more than half formed, as this would in turn result in premature loss or eruption of the first premolar as soon as the first premolars erupt into the oral cavity; these are extracted followed by deciduous canines. If this is bound to be the eruption of permanent canines before that of first premolar, then the deciduous canine is extracted first followed by the extraction of the deciduous first molar and enucleation of the first premolar<sup>[44, 45, 48, 49]</sup>.

**Advantages**

- It brings about early self-induced alignment of the permanent teeth
- There is improved overall oral health.

**Disadvantages**

- Not indicated for class II and class III malocclusions, if at all, extraction is carried only in class II in upper arch
- It can have psychological impact on the child, if total 12 teeth have to be extracted
- Deepening of bite can occur
- Requires prolonged patient follow-up
- The procedure alone is not sufficient to bring impacted canine into proper position
- Early extraction can lead to the loss of space and delayed the eruption of permanent teeth<sup>[44, 49]</sup>.

**Complications**

It can result in flat face with prominent chin. Patient may look aged\_ It can result in lingual inclination of incisors<sup>[50]</sup>.

**Conclusion**

Serial extraction is an interceptive orthodontic procedure undertaken in the (early) mixed dentition period that involves planned removal of certain primary and permanent teeth in a programmed sequence, so as to relieve crowding in the arches and to guide the remaining erupting permanent teeth into a more favorable position.

A thorough understanding of the dynamics of orofacial growth and development and that of the stomatognathic system is essential for the success of serial extraction procedures.

Rationale of serial extraction procedure is to intercept the

malocclusion at early mixed dentition period by extracting certain primary and permanent teeth, and then guiding the eruption of remaining permanent teeth into the best possible occlusion by using the physiologic eruptive forces and the existing normal neuromuscular balance. By doing so, the extent and the need of corrective orthodontic treatment at a later stage can be minimized.

**References**

1. Moyers RE. Development of occlusion. Dent Clin North Am. Philadelphia: WB Saunders Co. 1969; 13:523-36.
2. Proffit WR, Fields HW, Sarver DM. Contemporary Orthodontics. (4<sup>th</sup> ed). St. Louis, Elsevier, 2007.
3. Graber Vanarsdall. Vig. Orthodontics: Current Principles and Technique. (4<sup>th</sup> ed). St. Louis, Elsevier. 2007, 405-489.
4. Andlaw RJ, Rock WPA. A manual of pedodontics. Churchill Livingstone Newyork Second Edition, 1987.
5. Braham RL, Morris ME. Textbook of Pediatric Dentistry. C.B.S. Publishers Delhi, Second Edition, 1990.
6. Enlow H, Mark Hans G. Essentials of facial growth. W.B. Saunder Company, Philadelphia, 1996.
7. Finn SB. Clinical pedodontics. Saunders Company, 4th Edition, 19.
8. Houston W.J.B. A textbook of orthodontics. Wright, London, 1986.
9. Ralph McDonald E. Dentistry for child and adolescent. Mosby and Company, 5<sup>th</sup> edition, 1993.
10. Bunon R. Essay sur les maladies des dents; ou l'on propose les moyens de leur procurer une bonne confirmation des la plus tendre enfance, et d'en assurer la conservation pendant tout le cours de la vie. Paris, 1743.
11. Kjellgren B. Serial extraction as a corrective procedure in dental orthopedic therapy. Eur Orthod Soc Trans. 1947-1948, 134.
12. Kjellgren B. Serial extraction as a corrective procedure in dental orthopaedic therapy. Eur J Orthod. 2007; 29(1):37-50.
13. Hotz R. Guidance of eruption versus serial extraction. Am J Orthod. 1970; 58:1.
14. Dewel BF. A critical analysis of Serial Extraction in orthodontic treatment. Am J Orthod. 1959; 45(6):424-55.
15. Dewel BF. Serial Extraction procedures and limitation. AJO. 1957; 43(9):685-87.
16. Lloyd Bernard Z. Serial Extraction as a treatment procedure. AJO. 1956; 42(10):728-39.
17. Maj Luzi. Treatment of class I malocclusion in the mixed dentition. Am JO. 1960; 46(3):207-19.
18. Mayne Warien R. Serial extraction orthodontics at the cross roads. DCNA, 1968, 341-62.
19. Dewel BF. Pre-requisite in Serial Extraction Am J Orthod. 1969; 55(6):633-39.
20. Maj Giorgio. Serial Extraction in class I mixed dentition cases. AJO. 1970; 57(4):393-99.
21. Ruff. Orthodontic treatment in mixed dentin. AJO. 1976; 57(5):502-18.
22. Odenrick L, Trocmé M. Facial, dentoalveolar and dental morphology in serial or early extraction Angle Orthod. 1985; 55(3):206-14.
23. Jacquelin LF, Berthet A. From the mixed dentition to the permanent dentition: how to manage space while guiding eruption. Rev Odontostomatol (Paris). 1991; 20(4):321-9.
24. Maj Giorgio. Serial Extraction in class I mixed dentition cases. AJO. 1970; 57(4):393-99.
25. Jacop Haris. Restoring mandibular arch length. Am J



- Ortho. 1972; 62(6):606-22.
26. Dewel BF. Serial Extraction: Precaution, limitation and alternatives. *Am J Orthod.* 1976; 69(1):95-97.
  27. Lieberman Myeen A. Factors influencing tooth extraction in orthodontic borderline cases. *ASDC JDC*, 1984, 194-195.
  28. Dewel BF. Serial extraction in Orthodontics. *Am J Orthod.* 1954; 40:923-926.
  29. Mayne Warien R. Serial extraction orthodontics at the cross roads. *DCNA*, 1968, 341-62.
  30. Moorrees CF, Chadha JM. Available space for the incisors during dental development-a growth study based on physiologic age. *Angle Orthod.* 1965; 35:12-22.
  31. Salzmann JA. Serial extraction in general dental practice. *Am J Orthod.* 1966; 52(2):145-6.
  32. Ringenberg. Influence of Serial Extraction an growth and development of the maxilla and mandible. *Am J O.* 1967; 53(1):19-26.
  33. Freeman JD. Preventive and interceptive orthodontics: a critical review and the results of a clinical study. *J Prev Dent.* 1977; 4(5):7-14, 20-3.
  34. Persson M, Persson EC, Skagius S. Long term spontaneous changes following removal of all first premolars in class I cases with crowding. *Eur J Orthod.* 1989; 11(3):271-82.
  35. Little Robert M *et al.* Serial Extraction of first premolar post retention evaluation of stability and relapse. *The Angle Orthodontist.* 1990; 60(4):255-62.
  36. Hollander. Full. Midline correction by extraction of the remaining mandibular C: myth or reality. *ASDC*, 1992, 207-211.
  37. Wagner M, Berg R. Serial Extraction or premolar extraction in the permanent dentition, comparison of duration and outcome of ortho Treatment. *J Orofac Orthop.* 2000; 61(3):207-16.
  38. Kanellis MJ. Orthodontic treatment in the primary dentition. In: Bishara SE, ed. *Textbook of Orthodontics.* Philadelphia, Pa.: WB Saunders Co. 2001, 248-56.
  39. Bell RA, Dean JA, McDonald RE, Avery DR. Management of the developing occlusion. In: Dean JA, Avery DR, McDonald RE. eds. *McDonald and Avery's Dentistry for the Child and Adolescent.* 9th ed. Maryland Heights, Mo.: Mosby Elsevier, 2011, 550-613.
  40. Van Der Linden F. Theoretical and practical aspects of crowding in the human dentition. *J Am Dent Assoc.* 1974; 89:139-53.
  41. Wagner M, Berg R. Serial extraction or premolar extraction in the permanent dentition? Comparison of duration and outcome of orthodontic treatment. *J Orofac Orthop.* 2000; 61:207-216.
  42. Dale JG. Serial extraction. Nobody does that anymore! *Am J Orthod Dentofacial Orthop.* 2000; 117:564-566.
  43. Yoshihara T, Matsumoto Y, Suzuki J, Sato N, Oguchi H. Effect of serial extraction alone on crowding: Spontaneous changes in dentition after serial extraction. *Am J Ortho Dentofacial Orthop.* 2000; 118(6):611-6.
  44. Proffit WR. Timing of early treatment. *Am J Orthod Dentofacial Orthop.* 2006; 129:S47-9.
  45. Lopes Filho H, Maia LH, Lau TC, de Souza MM, Maia LC. Early vs late orthodontic treatment of tooth crowding by first premolar extraction: A systematic review. *Angle Orthod.* 2015; 83: 510-517.
  46. Travess H, Roberts-Harry D, Sandy J. Orthodontics. Part 8: Extractions in orthodontics. *Br Dent J.* 2004; 196:195-203.
  47. Yoshihara T, Matsumoto Y, Suzuki J, Ogura T. Effect of serial extraction alone on crowding: relationship between closure of residual extraction space and changes in dentition. *J Clin Pediatr Dent.* 2002; 26:147-153.
  48. Haruki T, Little RM. Early versus late treatment of crowded first premolar extraction cases: postretention evaluation of stability and relapse. *Angle Orthod.* 1998; 68:61-68.
  49. Wagner M, Berg R. Serial extraction or premolar extraction in the permanent dentition? Comparison of duration and outcome of orthodontic treatment. *J Orofac Orthop.* 2000; 61:207-216.
  50. Wilson JR, Little RM, Joondeph DR, Doppel DM. Comparison of soft tissue profile changes in serial extraction and late premolar extraction. *Angle Orthod discussion.* 1999; 69:165-173, 173-164.