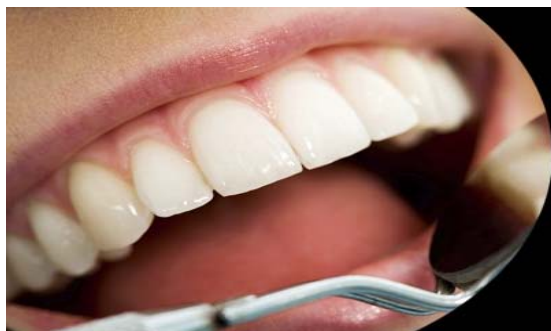



International Journal of Applied Dental Sciences

ISSN Print: 2394-7489
ISSN Online: 2394-7497
IJADS 2020; 6(1): 74-89
© 2020 IJADS
www.oraljournal.com
Received: 10-11-2019
Accepted: 13-12-2019

Dujana Rastanawi
PhD Student in Endodontic and
Operative Dentistry, Faculty of
Dentistry, Hama University,
Hama, Syria

Hassan Al-halabiah
Assistant Professor, PhD in
Endodontic and Operative
Dentistry, Head of Endodontic
and Operative Dentistry
Department and Dean of Faculty
of Dentistry, Faculty of
Dentistry, Hama University,
Hama, Syria

Corresponding Author:
Dujana Rastanawi
PhD Student in Endodontic and
Operative Dentistry, Faculty of
Dentistry, Hama University,
Hama, Syria

Clinical and radiographic study to investigate the effect of platelet-rich fibrin membranes (PRF) application as partial pulpotomy agent

Dujana Rastanawi and Hassan Al-halabiah

Abstract

Purpose: The aim of this study was to evaluate the effect of platelet-rich fibrin (PRF) membranes application on dental pulp as a partial pulpotomy agent in permanent teeth.

Material and Methods: 40 permanent teeth from 40 healthy patient aged 8-18 years with iatrogenic or carious exposed pulps were randomly divided into 4 groups (n=10) depending on the cause of the exposure and pulpotomy agent. In all specimens 1-2 mm of exposed pulp was removed. After hemostasis, exposed pulps were covered using PRF membrane with MTA or MTA only, then all teeth were restored with glass-ionomer cement and composite resin. Clinical and radiographic evaluation was undertaken at (3, 6, and 12) months intervals. The results were analyzed using appropriate statistical tests.

Results: There were differences between studied groups but they were not significant since most of examined teeth showed positive responses to electrical pulp test and dentinal bridge formation.

Conclusion: PRF could improve the prognosis of pulpotomy procedures of mature permanent teeth.

Keywords: dental pulp, partial pulpotomy, pulp regeneration, platelet-rich fibrin PRF, mineral trioxide aggregate cement MTA

Introduction

The vitality of the dentin-pulp complex is fundamental to the ideal function of tooth and is a priority during treatment [1]. Partial Pulpotomy is a vital pulp therapy in which a portion of coronal pulp is removed, and the remaining pulp is preserved intact. The remaining pulp tissue will be covered with a biocompatible material in order to protect and stimulate the pulp repairing and healing [2]. Mineral trioxide aggregate (MTA) is one of the most widely used materials for such purposes with high successful rate of clinical outcomes. However, there is a constant need for biologically based autologous materials to avoid immunological side effects [3]. Recently, platelet rich fibrin (PRF) has been used for tissue regeneration [4]. Understanding of physiologic properties of platelets in wound healing has led to augment their therapeutic applications [5]. PRF was first developed in France by Choukroun *et al.* in 2001 [6]. Clinical use of platelet preparation lies in the fact that PRF serves as a reservoir for continuous release of growth factors which directs the process of reparative dentinogenesis. Huang *et al.* investigated the effect of PRF on cultured primary dental pulp cells and concluded that PRF can increase dental pulp cell proliferation and differentiation [7]. Hiremath *et al.* first reported the successful management of a mature molar with pulpitis using PRF as pulpotomy agent [1]. Several case reports [3, 8, 9] and studies [10, 11, 12, 13] showed regenerative potential of PRF as a covering material on dental pulp in temporary or permanent teeth whatever the state of the pulp tissue. However, no long-term study or clinical trial has evaluated the effectiveness of this protocol. Hence, this study was designed to investigate the clinical role and radiographic success of PRF to enhance healing after partial pulpotomy in permanent teeth with complete root development in different pulp conditions after 3 follow-ups period.

Materials and methods

Ethical clearance and consent

Ethical clearance to conduct the study was obtained from the institutional review board.

The parents of the children received detailed information regarding procedure, benefits, and possible risk involved in the study. In PRF Group, blood was collected from each child, written consent was obtained from parents before treatment.

Study design and sampling

This study was carried out on 40 permanent teeth from 40 healthy patient aged 8-18 years, who visited clinics of Endodontic and Operative Dentistry Department, Faculty of Dentistry, Hama University. Teeth of samples were divided into 2 main groups depending on the cause of exposure (iatrogenic and carious) (n=20), then they were divided into 2 subgroups depending on pulpotomy agent (PRF with MTA and MTA only) (n=10), so the studied groups were as follows:

1. Iatrogenic Exposure + PRF with MTA.
2. Iatrogenic Exposure + MTA only
3. Carious Exposure + PRF with MTA.
4. Carious Exposure + MTA only.

The teeth were selected according to the following criteria: a carious or iatrogenic exposure of the vital pulp, absence of symptoms of advanced pulpal inflammation such as spontaneous pain or history of nocturnal pain, absence of clinical signs or symptoms suggesting a non-vital tooth such as suppurating sinus, soft tissue swelling, the absence of radiographic signs of pulpal necrosis, i.e., periapical pathology, and the teeth should be restorable after completion of the procedure. Teeth which showed excessive bleeding during the amputation of pulp tissue which is difficult to control and patients having medical conditions such as the history of heart surgery, leukemia, or immune-compromised conditions and congenital heart defects were excluded from the study.

Procedure

Local anesthesia was administrated using 2% lidocaine with 1:100,000 adrenaline. The tooth was isolated using the rubber dam, in all groups the cavity outline was established with a high-speed round diamond bur with water coolant. Normal saline was used to wash away the debris. The exposed pulp appeared vital; judged by its appearance, bright red color, and bleeding overflowing from the exposure site. Then, approximately 1-2 mm in depth of pulp tissue at the exposure site was removed with a spoon excavator, the cavity was irrigated with normal saline. Hemorrhage was controlled using a sterile moistened cotton pellets under pressure [14].

Platelet-rich fibrin group

PRF was prepared using Choukroun's procedure [6]. The required quantity of blood was drawn by a trained medical staff into 10 ml test tubes without an anticoagulant and centrifuged immediately for 12 min at 2700 rounds per minute. The resultant product consists of three layers; platelet-poor plasma at the surface, PRF clot in the middle, and red blood cells at the bottom. Sterile tweezers inserted into a test tube to retrieve the PRF clot. The PRF membrane was obtained by squeezing the PRF clot between the sterile dry gauges to drive out the fluids trapped in the fibrin matrix [Figure 1]. A piece of prepared fibrin membrane was gently packed over the amputated pulp using a sterile gauze and covered with MTA [15] [Figure 2].

Mineral trioxide aggregate group

The exposed pulp was covered only with MTA cement (paste obtained by mixing MTA powder with sterile water at a 3:1 ratio according to manufacturer's instruction: OrthoMTA BioMTA, Seoul, Korea). The mixture was placed on the pulp surface and patted with a moist cotton pellet. The remaining cavity in both groups was filled with glass ionomer cement and composite resin. Clinical examinations and radiographic evaluation were undertaken at 3, 6, and 12 month intervals [Figure 3].

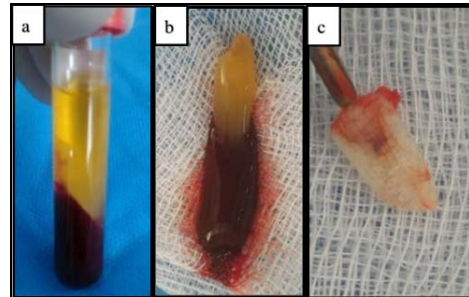


Fig 1: PRF membrane preparation (a: glass tubes after centrifugation, b: fibrin clot (PRF) with red base, c: PRF membrane)

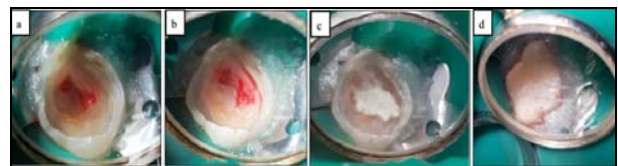


Fig 2: Clinical Procedure (a: pulp exposure, b: PRF membrane application on exposed pulp, c: MTA application over PRF membrane, d: coronal restoration).

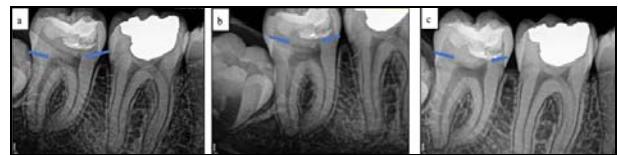

Fig 3: periapical radiographs at 3 periods follow-ups (a: after 3 months, b: after 6 months, c: after 12 months).

Clinical Examination: The electrical pulp test was applied to the intact similar tooth. The obtained values were recorded and considered the threshold of the pulps' normal response. Gradual scaling from 0 to 3 was used to evaluate the dental pulp state.

Radiographic Examination: Periapical radiographs were studied to investigate the formation of the dentinal bridge. Gradual scaling from 0 to 3 was used to evaluate the degree of dentinal bridge formation in the studied samples.

Results

Tooth response degree to electrical pulp test (TRDEP) category and formation degree of dentinal bridge (FDDB) category were observed in three distinct periods (after 3 months, after 6 months and after 12 months) and compared with the values that had been recorded before treatment for each studied tooth in the sample. Each one of TRDEP and FDDB variables had 4 ordinal categories. Each category for each variable was assigned to a distinct numerical value, which reflects the strength of the according variable as shown in [Table 1].

Table 1: shows the values of teeth responses to the electrical pulp test and dentinal bridge formation adopted in the studied sample and the corresponding values given for each grade.

Assigned value	Tooth responds to electrical pulp test
0	No response
1	The pulp response threshold for electricity is lower than normal
2	The pulp response to electricity is normal
3	The pulp response threshold for electricity is higher than normal

A Mann-Whitney U test was applied to know if there were significant differences in tooth response degree to electrical pulp test and formation degree of dentinal bridge variable degrees' frequencies:

- No significant differences in TRDEP and FDDB variable's degrees between the PRF group and MTA group whatever the cause of exposure and the studied period [Figure 4,5].

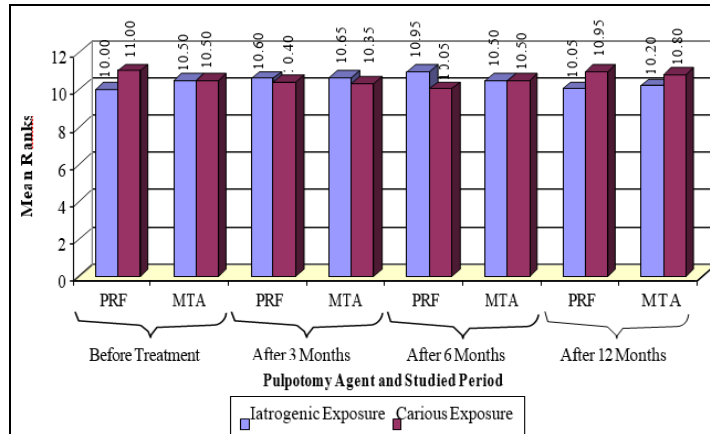


Fig 4: Mean Ranks values of TRDEP According to Pulpotomy Agent, Cause of Exposure and Studied Period Variables.

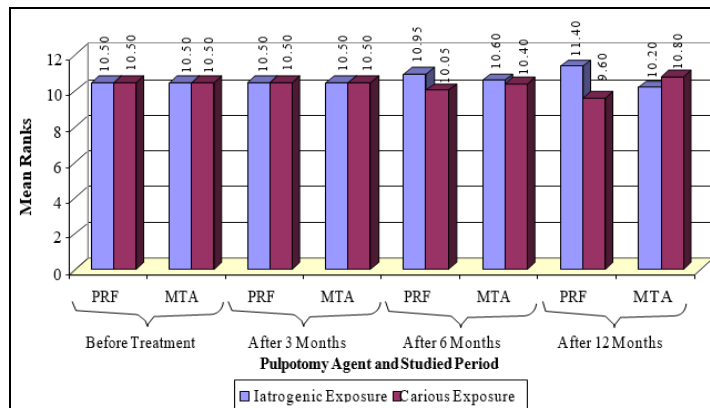


Fig 5: Mean Ranks values of FDDB According to Cause of Exposure, Pulpotomy Agent and Studied Period Variables

- No significant differences in TRDEP and FDDB variable's degrees between iatrogenic exposure group and carious exposure group whatever the pulpotomy agent and the studied period [Figure 6,7].

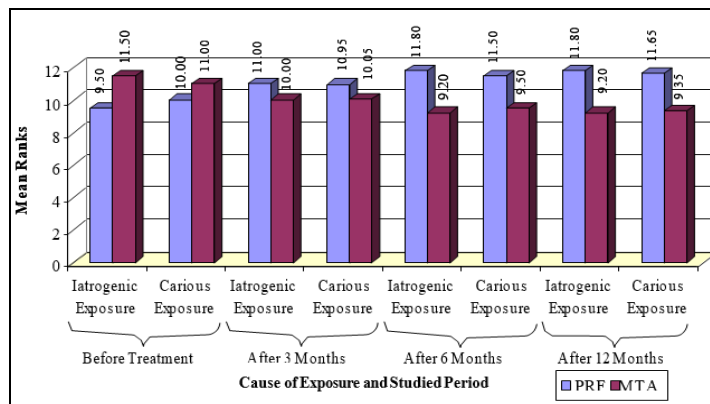


Fig 6: Mean Ranks values of TRDEP According to Cause of Exposure, Pulpotomy Agent and Studied Period Variables.

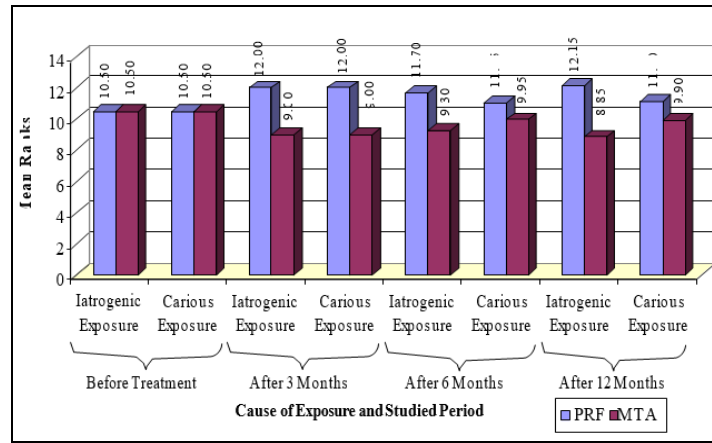


Fig 7: Mean Ranks values of FDDB According to Pulpotomy Agent, Cause of Exposure and Studied Period Variables.

A Friedman test was applied to know if there were significant differences in TRDEP and FDDB variable degrees' frequencies between the four studied Periods according to pulpotomy agent and cause of exposure variables [Figure 8, 9]:

- No significant differences in TRDEP variable's degrees between the four studied Periods whatever the Cause of Exposure and the Pulpotomy Agent were in the studied

sample.

- No significant differences in FDDB variable's degrees between the four studied Periods in MTA + Cariou Exposure Group. significant differences in FDDB variable's degrees between at least two of the four studied Periods in iatrogenic exposure whatever the pulpotomy agent was and in PRF + cariou exposure group in the studied sample

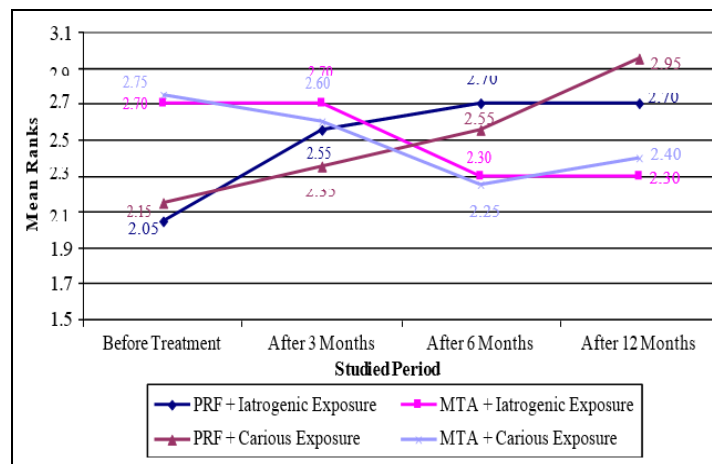


Fig 8: Mean Ranks values of TRDEP According to Studied Period, Cause of Exposure and Pulpotomy Agent

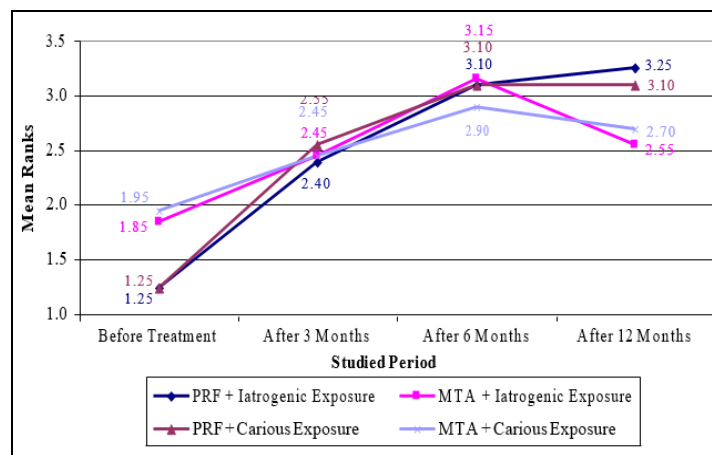


Fig 9: Mean Ranks values of FDDB According to Studied Period, Cause of Exposure and Pulpotomy Agent Variables

A Wilcoxon Signed Ranks test was applied to know if there were significant pair-wise differences in FDDDB variable degrees' frequencies between the four studied Periods in Iatrogenic Exposure according the Pulpotomy Agent in PRF + Carious Exposure Group:

- Significant pair-wise differences in FDDDB variable's degrees between the sub-mentioned periods in the studied sample.

Discussion

Preservation of the dental pulp is essential to maintain the function teeth^[8], so in the present study partial pulpotomy was the treatment of choice to manage exposed pulps in permanent teeth. Since the status of pulp before vital pulp therapy is also a key factor in determining the success rate of this technique^[16]; we chose two types of pulp exposure (iatrogenic or carious) to be included in the study.

Two materials have been chosen (MTA and PRF). Many studies were carried out using MTA and proposed MTA as excellent pulpotomy agent^[17], although it has some drawback, Fridland and Rosado showed that a high PH of 12.5 created in the area adjacent to the MTA remains high for at least 8 weeks^[18]. This high PH during setting has been found to affect cell activity and exert a cytotoxic effect on both especially on macrophages and fibroblast^[19]. Therefore, it is important to develop biocompatible materials to maintain pulp vitality and increasing tooth longevity^[7].

Hiremath *et al.* first reported the successful management of PRF as pulpotomy agent^[1]. Then many case reports and clinical study reported favorable outcomes using PRF as pulpotomy agent in permanent mature teeth^[3, 8, 9, 11], immature teeth with incomplete root development^[10], and in primary teeth^[12]. However, no many long-term study or clinical trial has evaluated the effectiveness of this biological material, so PRF was used in the present study considering its biocompatibility and bioactivity.

The present study showed differences but they were not significant between studied groups. Both PRF with MTA and MTA only had similar and favorable clinical outcomes since the majority of the teeth responded positively to electric pulp test at follow-up periods except of 5 teeth: (1 in MTA + iatrogenic exposure, 2 in PRF with MTA + carious exposure, and 2 in MTA + carious exposure) after 12 month follow up. A statistically significant difference was observed between the groups at 12 months of follow-up appointment. Radiographic examination showed different degrees of dentinal bridge formation, it was obvious almost in all teeth that had iatrogenic pulp exposure (2 of 20; 1 in PRF with MTA group and 1 in MTA group), while it was not identified or irregular in the teeth that had carious pulp exposure (5 of 20; 2 in PRF with MTA group and 3 in MTA group).

Similar results were obtained in the study of Keswani *et al.*^[10] regarding the absence of significant differences between the application of PRF and MTA as pulpotomy agent in terms of clinical success in maintaining the vitality of the dental pulp. While radiographic results were partially similar to our results, that's because we only evaluated the formation of the dentinal bridge while their radiographic evaluation included the completion of root development and apical closure since their studied samples involved immature permanent teeth.

The results of Kumar *et al.*^[11] study was partly in agreement with ours, who reported a good clinical success rate at 12 months. However, radiographic success rate was much less. We can attribute the reason for radiographic success differences to the applied pulpotomy technique, where in our

study we used partial pulpotomy technique, while in their study full coronal pulpotomy was applied.

The results of our study was in agreement with the results of Patidar *et al.*^[12] study; they also found that both PRF and MTA had similar and positive clinical results. However, radiographic success rate was low in their study compared to ours, this difference can be attributed to the type of teeth to which the treatment was applied, since their studied samples were primary teeth roots may be subjected to physiological absorption during the follow-up periods.

The histological results of Tabatabayi *et al.*^[13] study who evaluated the regenerative capability of PRF as a pulpotomy agent in dogs' teeth showed that the dentinal bridge had formed in all studied samples. This may support our radiographic findings, as we have noticed the formation of dentinal bridge in the vast majority of the samples in which PRF was applied as pulpotomy agent.

It was not possible to include more participants in the current study because of its reluctance of patients opting for pulpotomy, difficulty obtaining parents or guardians approval, and strict inclusion criteria adopted. According to present study, we cannot provide conclusive evidence to consider partial pulpotomy using PRF an alternative option for MTA. More randomized controlled clinical trials with larger sample size are imperative before a final conclusion regarding its usefulness in pulpotomy, its role as bioactive agents and the incidence of pulp canal obliteration in such cases.

Conclusion

Based on the present study we concluded that partial pulpotomy as a treatment option has an acceptable clinical success rate using PRF whatever the cause of pulp exposure in permanent teeth with promising horizons in clinical application that may lead to paradigm shift in vital pulp therapy.

References

1. Hiremath H, Saikalyan S, Kulkarni SS, Hiremath V. Second-generation platelet concentrate (PRF) as a pulpotomy medicament in a permanent molar with pulpitis: A case report. *Int Endod J.* 2012; 45(1):105-12.
2. Choukroun J, Diss A, Simonpieri A, Girard MO, Schoeffler C, Dohan SL *et al.* Platelet- rich fibrin (PRF): A second-generation platelet concentrate. Part IV: Clinical effects on tissue healing. *Oral Surg Oral Med Oral Pathol Oral Radiol Endod.* 2006; 101:E56-60.
3. Prasanthi N, Simpsy G, Chittem J, Sajjan G. Biological approach in the management of permanent molars with irreversible pulpitis using platelet-rich fibrin as a pulpotomy medicament: case reports with 2-year follow up. *Journal of Interdisciplinary Dentistry.* 2018; 8(1):30-4.
4. Huang GT. Pulp and dentin tissue engineering and regeneration: Current progress. *Regen Med.* 2009; 4(5):697-707.
5. Hotwani K, Sharma K. Platelet rich fibrin - a novel acumen into regenerative endodontic therapy. *Restor Dent Endod.* 2014; 39(1):1-6.
6. Choukroun J, Adda F, Schoeffler C, Vervelle A. An opportunity in perio-implantology: the PRF. *Implantodontie.* 2001; 42:55-62.
7. Huang FM, Yang SF, Zhao JH, Chang YC. Platelet-rich fibrin increases proliferation and differentiation of human dental pulp cells. *J Endod.* 2010; 36(10):1628-32.
8. Pathak S, Bansode B, Ahire CH. PRF as a pulpotomy

- medicament in a permanent molar with pulp. IOSR Journal of Dental and Medical Sciences. 2014; 10(13):05-09.
9. Solomon RV, Faizuddin U, Karunakar P, Sarvani GD, Soumya SS. Coronal pulpotomy technique analysis as an alternative to pulpectomy for preserving the tooth vitality in the context of tissue regeneration: a correlated clinical study across 4 adult permanent molars. *Case Rep Dent*. 2015, 1-12.
 10. Keswani D, Pandey RK, Ansari A, Gupta SH. Comparative evaluation of platelet-rich fibrin and mineral trioxide aggregate as pulpotomy agents in permanent teeth with incomplete root development: a randomized controlled trial. *JOE*. 2014; 40(5):599-605.
 11. Kumar V, Juneja R, Duhan J, Sangwan P, Tewari S. Comparative evaluation of platelet-rich fibrin, mineral trioxide aggregate, and calcium hydroxide as pulpotomy agents in permanent molars with irreversible pulpitis: A randomized controlled trial. *Contemp Clin Dent*. 2016; 7(4):512-518.
 12. Patidar S, Kalra K, Khatri A, Tyagi R. Clinical and radiographic comparison of platelet-rich fibrin and mineral trioxide aggregate as pulpotomy agents in primary molars. *J Indian Soc Pedod Prev Dent*. 2017; 35:367-73.
 13. Tabatabayi MH, Tavakoli A, Ameghani BA. Regenerative property of PRF used as capping material in pulpotomy in dogs. *Biomedical Research*. 2017; 28(10):4634-4639.
 14. Kang CM, Sun Y, Song JS, Pang NS, Roh BD, Lee CY *et al*. A randomized controlled trial of various MTA materials for partial pulpotomy in permanent teeth. *J Dent*. 2017; 60:8-13.
 15. Abdulgani A, Abdulgani M, Abu-Hussein M. Platelet-rich fibrin (PRF) in dentistry. *International Journal of Applied Dental Sciences*. 2019; 5(4):01-08.
 16. Ward J. Vital pulp therapy in cariously exposed permanent teeth and its limitations. *Aust Endod J*. 2002; 28(1):29-37.
 17. Verma N, Kaur A, Acharya SH, Sharma S. Clinical and radiographic evaluation of mineral trioxide aggregate pulpotomy in permanent teeth. *Dental Journal of Advance Studies*. 2016; 7(4):475-480.
 18. Fridland M, Rosado R. MTA solubility: A long term study. *J Endod*. 2005; 31(5):376-9.
 19. Monteiro Bramante C, Demarchi AC, de Moraes IG, Bernadineli N, Garcia RB, Spångberg LS *et al*. Presence of arsenic in different types of MTA and white and gray Portland cement. *Oral Surg Oral Med Oral Pathol Oral Radiol Endod*. 2008; 106(6):909-13.