ISSN Print: 2394-7489
ISSN Online: 2394-7497
IJADS 2020; 6(3): 146-154
© 2020 IJADS
www.oraljournal.com
Received: 01-05-2020
Accepted: 03-06-2020

Dr. Bhushan Jawale
Professor, Dept of Orthodontics and Dentofacial Orthopedics, Sinhgad Dental College and Hospital, Sinhgad, Pune, Maharashtra, India

Dr. Lishoy Rodrigues
PG Student, Dept of Orthodontics and Dentofacial Orthopedics, Sinhgad Dental College and Hospital, Sinhgad, Pune, Maharashtra, India

Dr. KM Keluskar
Dean, Professor and HOD, Dept of Orthodontics and Dentofacial Orthopedics, KLE Dental College and Hospital, Belgaum, Karnataka, India

Dr. Roopa Jatti
Professor, Dept of Orthodontics and Dentofacial Orthopedics, KLE Dental College and Hospital, Belgaum, Karnataka, India

Dr. Anup Belludi
Professor and HOD, Dept of Orthodontics and Dentofacial Orthopedics, KLE Dental College and Hospital, Bangalore, Karnataka, India

Dr Rohan Hattarki
Associate Professor, Dept of Orthodontics and Dentofacial Orthopedics, KLE Dental College and Hospital, Belgaum, Karnataka, India

Corresponding Author:
Dr. Lishoy Rodrigues
PG Student, Dept of Orthodontics and Dentofacial Orthopedics, Sinhgad Dental College and Hospital, Sinhgad, Pune, Maharashtra, India

Treatment of a growing male having a recessive mandible with removable myofunctional appliance therapy followed by fixed orthodontic treatment: A case report

Dr. Bhushan Jawale, Dr. Lishoy Rodrigues, Dr. KM Keluskar, Dr. Roopa Jatti, Dr. Anup Belludi and Dr Rohan Hattarki

Abstract
Class II malocclusion is one of the most common problems around the globe affecting around one-third of the patients who come for orthodontic treatment Twin block appliance from its inception and evolution itself has been widely accepted as a more competent Class II corrector compared to earlier bulky monoblock appliances. Functional appliances can be used successfully in growing patients with certain skeletal Class II patients. Twin block appliance is very effective in a growing patient. The successful use of this appliance in the treatment of skeletal Class II malocclusion is based upon factors such as; age of patient, compliance of the patient and other case selection criteria. This appliance is very successful in a patient with a retrognathic mandible and well aligned arches with a positive VTO. This efficiently enables the mandibular forward positioning and improves the profile. This case report is of a 12-year-old growing male patient with a Skeletal Class II Pattern and a recessive lower jaw who was treated with Twin block appliance. The profile changes and treatment results were demonstrated. In permanent dentition, twin block appliance produces a similar effect as in mixed dentition phase. With proper case selection and good patient cooperation, we can obtain a significant result with twin block appliance.

Keywords: Removable myofunctional appliance, fixed appliance therapy, recessive mandible, Twinblock, Class II

Introduction

Twin block appliance is very effective in a growing patient. The successful use of this appliance in the treatment of skeletal Class II malocclusion is based upon factors such as; age of patient, compliance of the patient and other case selection criteria Dentofacial orthopedic treatment can significantly alter and improve facial appearance in addition to correcting irregularity of the teeth. Functional appliance therapy can be used successfully in Class II malocclusion, e.g., in a growing patient. Twin blocks are simple bite blocks that interlock at a 70° angle and correct the maxillomandibular relationship through functional mandibular displacement. The twin block appliance was developed by Clark in 1980s. They modify the occlusal inclined plane, guiding the mandible forward into correct occlusion. The use of these appliances is greatly dependent on patient's compliance and they simplify the fixed appliance phase. Functional appliances may be defined as orthodontic appliances that use the forces generated by the muscles to achieve dental and skeletal changes [1, 2]. These appliances have been used in clinical orthodontics for a long time and are extensively featured in the literature [3, 4]. Their effect is produced from the forces generated by the stretching of the muscles [5]. It is a commonly used functional appliance partly due to its acceptability by patients (Chadwick *et al*., 1998) [6]. The muscles and soft tissues are stretched with the generated pressure transmitted to the skeletal and dental structures potentially resulting in skeletal growth modification and tooth movement [6]

Case Report

Extra-Oral Examination

A 12year 8 month old male patient presented with the chief complaint of forwardly placed and irregular upper and lower front teeth and a backwardly placed lower jaw. On Extraoral examination, the patient had a convex profile, grossly symmetrical face on both sides with a retruded chin, competent lips, deep mentolabial sulcus and an average Nasolabial Angle, a Leptoprosopic facial form, Dolicocephalic head form, Average width of nose and mouth, minimal buccal corridor space, a consonant smile arc and posterior divergence of face . The patient had no relevant prenatal, natal, postnatal history, history of habits or a family history.

Pre Treatment Extraoral Photographs

Intra-Oral Examination

Intraoral examination on frontal view shows presence of a deep overbite, on side views the patient shows the presence of Class II div 1 incisor relationship, an End on canine relationship on both sides and an end on molar relationship on both sides. Patient has an overjet of 7 mm and an overbite of 5mm. There is moderate crowding in upper and lower anterior region. The upper and lower arch shows the presence of a V shaped arch form. OPG of the patient shows presence of all four 3rd molars in a developing stage. Hand wrist radiograph shows SMI stage 3 and lateral cephalogram is clearly indicative of a concex facial profile and a recessive lower jaw,

Pre-Treatment Intraoral Photographs

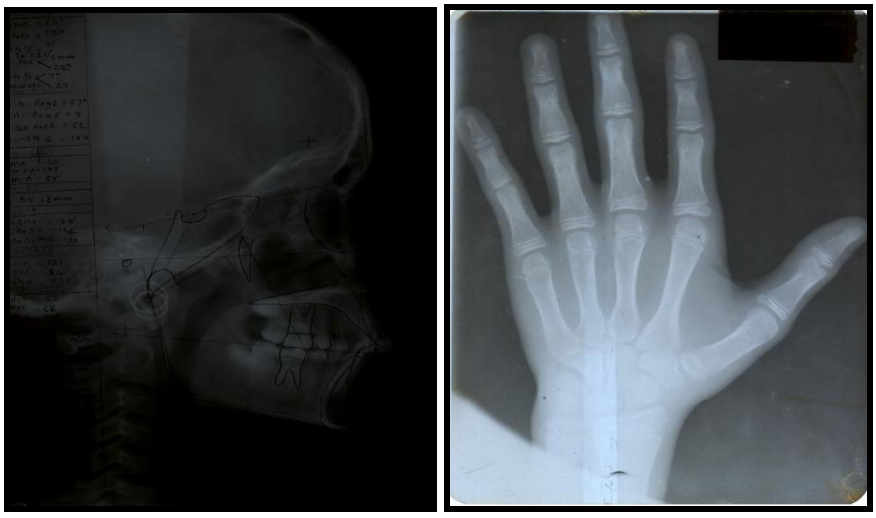

Pre Treatment Radiographs

Pre Treatment Cephalometric Readings

Parameters	Pre- Treatment
SNA	83°
SNB	76°
ANB	7°
WITS	5mm
MAX. LENGTH	75mm
MAN. LENGTH	98mm
IMPA	110°
NASOLABIAL ANGLE	88°
U1 TO NA DEGREES	39°
U1 TO NA mm	8mm
L1 TO NB DEGREES	35°
L1 TO NB mm	7mm
U1/L1 ANGLE	103°
SADDLE ANGLE	130°
ARTICULAR ANGLE	154°
GONIAL ANGLE	143°
FMA	24°
Y AXIS	69°

1. Steiners analysis shows an average maxilla and a retrognathic mandible, Class II Skeletal pattern, an Average to Horizontal growth pattern, proclined maxillary and mandibular anteriors, forwardly placed maxillary and mandibular anteriors and protrusive upper and lower lips
2. Tweeds analysis shows a Horizontal growth pattern and proclined mandibular incisors
3. Wits appraisal shows AO ahead of BO by 4 mm indicating Skeletal Class II pattern
4. Ricketts analysis shows a retrognathic mandible,retropositioned condyles and proclined mandibular anteriors
5. McNamara analysis shows a retrognathic maxilla, retrognathic mandible, a horizontal growth pattern, decreased lower anterior facial height and proclined mandibular incisors
6. Rakosi Jaraback analysis shows a Horizontal growth pattern and proclined maxillary and mandibular incisors
7. Holdaway soft tissue analysis shows increased maxillary and mandibular sulcus depth and increased strain of lips
8. Downs analysis shows a retropositioned chin, a Class II Skeletal pattern, a horizontal growth pattern and proclined maxillary and mandibular anterior teeth

Model Analysis

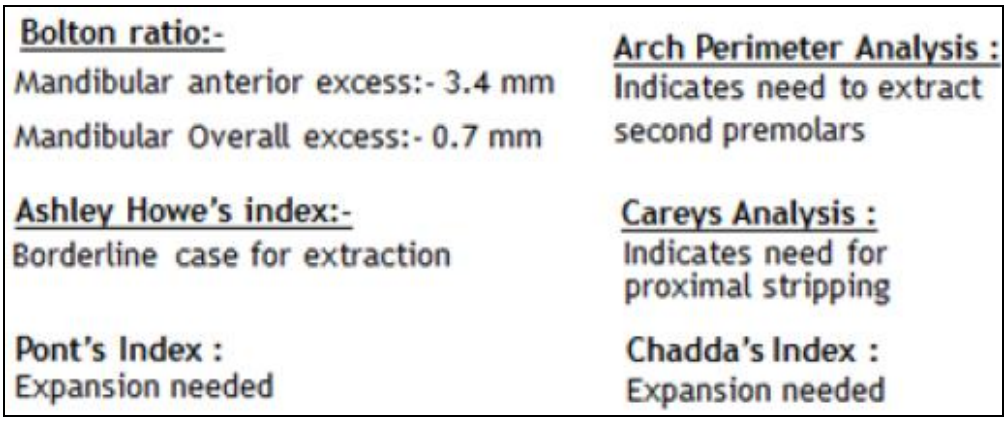

Diagnosis

This 12 years 8 month old male patient was diagnosed with Angle's Class II div 1 malocclusion with a avrerage maxilla, retrognathic mandible and a horizontal growth pattern, increased overjet and overbite, proclined upper and lower incisors, deep mentolabial sulcus and protrusive upper and lower lips

Treatment Objectives

1. To correct mandibular retrognathism
2. To correct crowding in upper and lower anterior region
3. To correct proclination of upper and lower anteriors
4. To correct overjet and overbite
5. To correct a deep mentolabial sulcus
6. To correct a deep curve of spee
7. To achieve a pleasing smile and a pleasing profile

Treatment Plan

a) Myofuntional Therapy: Removable Twinblock appliance
b) Appliance design:

- Saggital advancement: 7 mm
- Vertical opening: 4 mm

c) Fixed Appliance Therapy

Treatment

The treatment plan followed 2 phases of orthopedic and orthodontic correction. 1st phase involved correction of Sagittal discrepancy using Twinblock functional appliance therapy. The appliance used was a standard Clarks original Twinblock with a sagittal advancement of 6 mm and a vertical opening of 4 mm. The 2nd phase of treatment involved fixed orthodontic treatment with MBT 0.022 inch slot.

Twinblock Design

The design of the upper component of the twin block involved an acrylic base plate, which covers the palate and occlusal surfaces of the first molars and second premolars. There was an inclined plane at the end of the mesial end of the acrylic block. A labial bow was used for anterior retention of the appliance. A midline screw was also included. The lower component consisted of a lingual acrylic base plate covering the edge of the lower incisors.

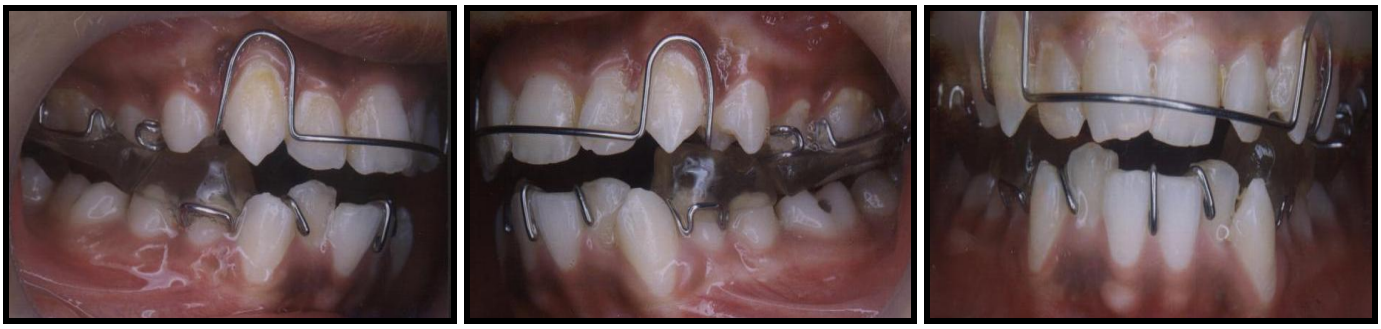

Twinblock Appliance Delivery Intraoral Photographs

Treatment Progress

Construction bite of the patient was registered by training the patient to bite in the desired anterior position which corrected the profile and enabled a class I molar relation bilaterally. Construction bite was taken with 6mm advancement and 4 mm opening. Clarks Twinblock was fabricated and appliance was delivered to the patient and proper post appliance delivery instructions were given. Follow ups were carried out regularly. Pterygoid response was observed in the patient within 28 days of delivery of the appliance. Trimming of the appliance was done in an occlusogingival direction at an interval of 3 weeks. Sagittal correction into a class I molar relation was achieved in 8 months. Photograph of Profile change after myofunctional therapy show the positive change in patients profile.

Profile Changes after Myofunctional therapy

Fixed Appliance Therapy with Mbt0.022 Inch Slot

Treatment Rationale of Phase I of the treatment involved the use of functional appliance to reduce the overjet, achieve class I molar relationships, and gain anchorage at the start of the treatment to simplify the fixed appliance stage and improve the patient's profile by causing a small skeletal change. This phase was followed with upper and lower fixed appliances (0.022″ slot brackets) to close spaces, detailing, and finishing of the case. The overall treatment time was 24 months, i.e., 12 months of functional appliance wear and 12 months of fixed appliance treatment. The molar relationship was overcorrected to a super Class I on the right and left side. Retention by means of both removable Hawleys retainer was given for 1 year and permmanent Lingual Bonded retainers in upper and lower arch were given.

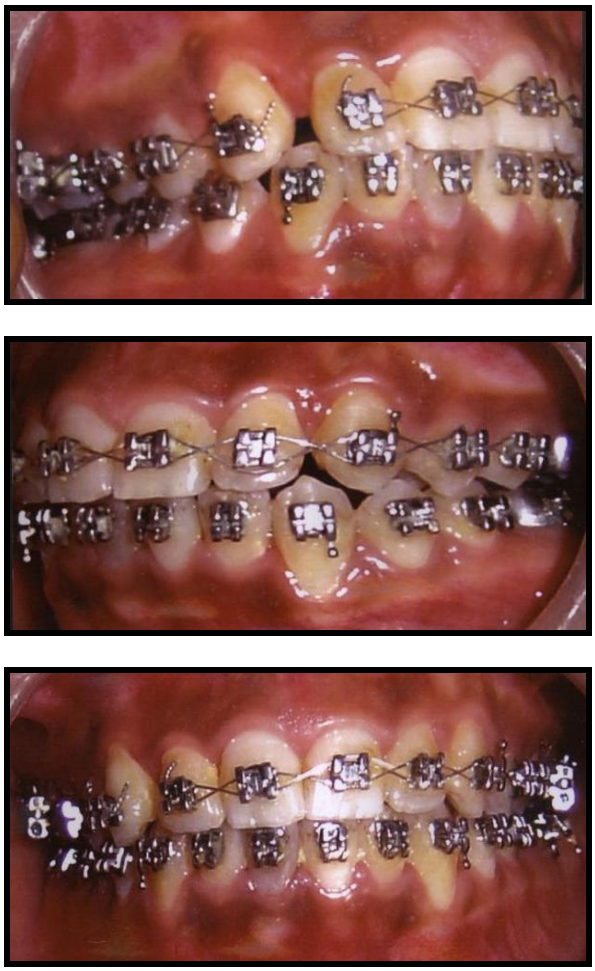

Mid Treatment Intraoral of Fixed Appliance Therapy

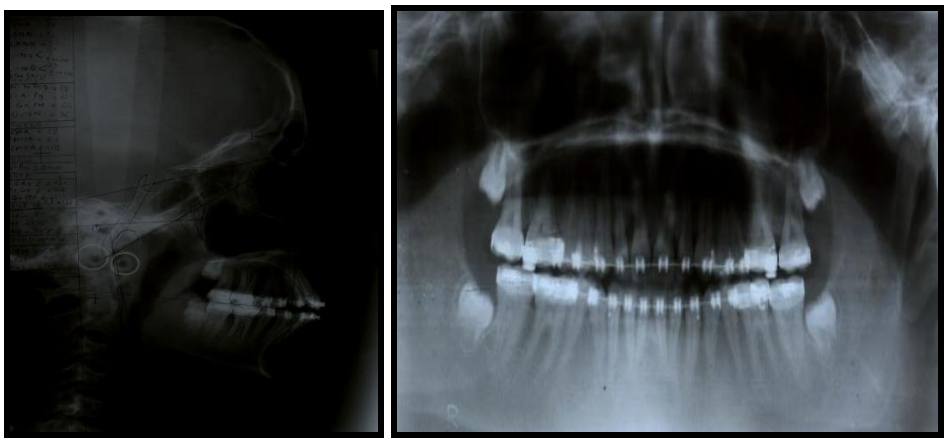

Mid Treatment Xrays

Discussion

Class II malocclusion might have any number of a combination of the skeletal and dental component. Hence, identifying and understanding the etiology and expression of Class II malocclusion and identifying differential diagnosis is helpful for its correction Twin block functional appliance has several well established advantages including the fact that it is well tolerated by patients and it can be used in the mixed and permanent dentition. There are potential disadvantages such as the proclination of the lower incisors and development of posterior open bites. In this case, the treatment objectives were achieved largely due to good patient compliance The patient's chief complaint was forwardly placed and irregular upper and lower front teeth and a backwardly placed lower jaw. The selection of functional appliances is dependent upon several factors which can be categorized into patient factors, such as age and compliance, and clinical factors, such as preference/familiarity and laboratory facilities. The myofunctional therapy resulted in an improvement in the patient's profile, which is largely attributed to the favorable growth and partly to the functional appliance. It has been proved in the literature that functional appliances do not produce long-term skeletal changes and most of their effects are dentoalveloar. In a prospective controlled trial with twin blocks and controls to investigate the skeletal and dental effects showed that the ANB angle reduced by 2°, which was almost entirely due to mandibular length increase which was 2.4 mm compared to the controls as measured from Ar-Pog. There was no evidence of a restriction in maxillary growth. Successful results were obtained after the myofunctional therapy within 12 months of time. The overall treatment time was 24 months, i.e., 12 months of functional appliance wear and 12 months of fixed appliance treatment. After this active treatment phase, the profile of this 12 year old growing male patient improved significantly as seen in the post treatment extra oral photographs

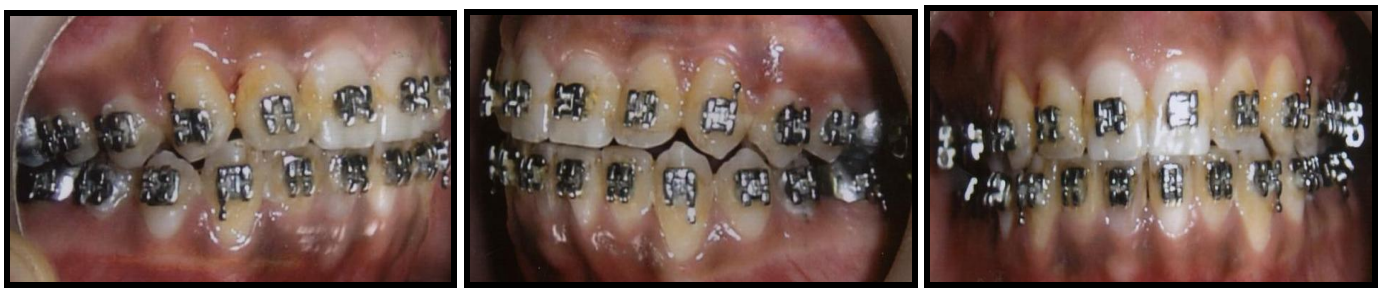

Pre Finishing Intraoral

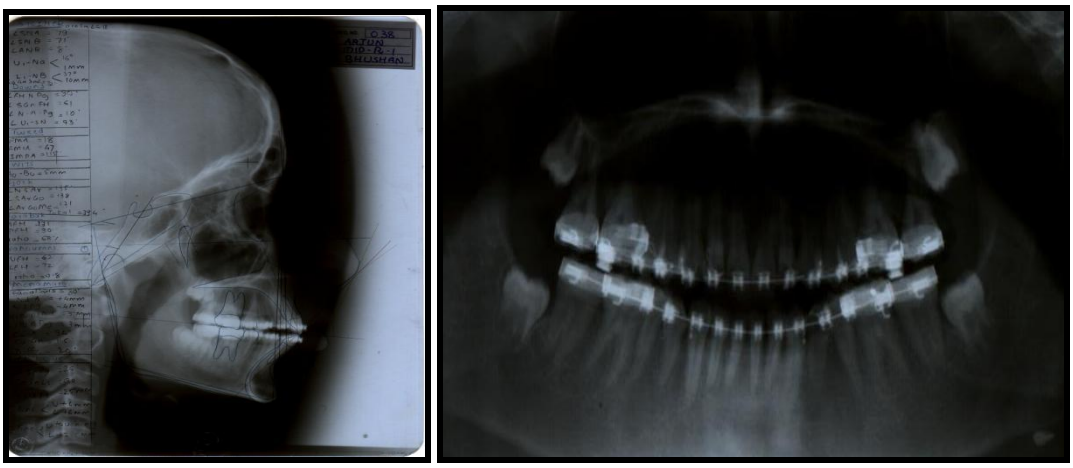

Pre Finishing Xrays

Post Treatment Cephalometric Readings

Parameters	Post-Treatment
SNA	81°
SNB	80°
ANB	1°
WITS	1mm
Max. Length	76mm
Man. Length	104mm
Impa	97°
Nasolabial Angle	99°
U1 To Na Degrees	26°
U1 TO NA Mm	2mm
L1 To Nb Degrees	24°
L1 TO NB Mm	2mm
U1/L1 Angle	132°
Saddle Angle	123°
Articular Angle	145°
Gonial Angle	132°
Fma	25°
Y Axis	71°

Post Treatment Extraoral Photographs

Post Treatment Intraoral Photographs

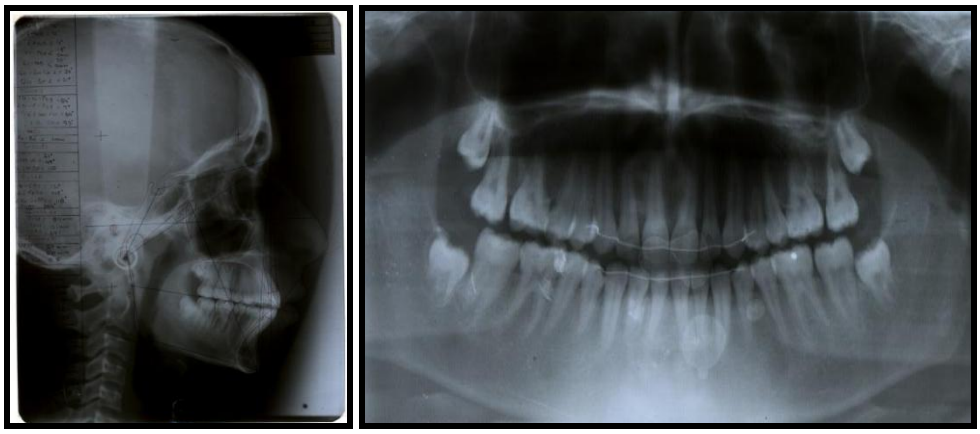

Post Treatment Xrays

Comparison of Pre and Post Treatment Cephalometric Readings

Parameters	Pre- Treatment	Post-Treatment
SNA	83°	81°
SNB	76°	80°
ANB	7°	1°
WITS	5mm	1mm
MAX. LENGTH	75mm	76mm
MAN. LENGTH	98mm	104mm
IMPA	110°	97°
NASOLABIAL ANGLE	88°	99°
U1 TO NA DEGREES	39°	26°
U1 TO NA mm	8mm	2mm
L1 TO NB DEGREES	35°	24°
L1 TO NB mm	7mm	2mm
U1/L1 ANGLE	103°	132°
SADDLE ANGLE	130°	123°
ARTICULAR ANGLE	154°	145°
GONIAL ANGLE	143°	132°
FMA	24°	25°
Y AXIS	69°	71°

Removable Retention

Fixed Retention

Profile Changes Pre-Treatment, After Twinblock Therapy and After Fixed Appliance Treatment

The Wonders of a Myofunctional Appliance

Conclusion

Functional appliance therapy is an effective way of treating skeletal Class II malocclusion due to mandibular retrusion via growth modification. The effect of twin block functional appliances is mostly dentoalveloar with small skeletal component. However, there are a number of situations where functional appliances can be successfully used to correct Class II malocclusion. Clinically significant restraint of maxillary growth was not found. Although the mandibular body length is increased, the facial impact of it is reduced by the simultaneous increment of the face height. It is important that functional appliances are used in a growing patient to achieve the maximum benefit. They simplify the following phase of fixed appliance by gaining anchorage and achieving Class I molar relationship. In this case, the patient was treated with twin block appliance followed by fixed appliance phase.

References

1. Clark WJ. The Twin Block technique. A functional orthopaedic appliance system. Am J Orthod Dentofac Orthop 1988; 93:1‑18.
2. Graber TM, Rakosi T, Petrovic A. Dentofacial orthopedics with functional appliances. 2nd ed. St Louis: Mosby, 1997.
3. Brien O. The effectiveness of treatment of class II malocclusion with the Twin Block appliance: A randomised, controlled trial. Am J Orthod Dentofac Orthop. 2003; 124:128-37.
4. Brien O. The effectiveness of treatment of class II malocclusion with the Twin Block appliance: A randomised, controlled trial. Part 2: Psychological effects. Am J Orthod Dentofac Orthop. 2003; 124:488‑95.
5. Mills JR. The effect of functional appliances on the skeletal pattern. Br J Orthod. 1991; 18:267‑75.
6. Singh Gd, Hodge Mr. Bimaxillary morphometry of patients with Class II division 1 malocclusion treated with twin block appliances. Angle orthod. 2002; 72:402-9.
7. Harradine N, Gale D. The effects of torquing spurs in Clark Twin Block appliances. Clin Ortho Res. 2000; 3:202-10.
8. Lee RT, Kyi CS, Mack GJ. A controlled clinical trial of the effects of the Twin Block and Dynamax appliances on the hard and soft tissues. Eur J Ortho 2007; 29:272-82
9. Lund DI, Sandler PJ. The effect of Twin Blocks: A prospective controlled study. Am J Orthod Dentofac Orthop. 1998; 13:104-10.
10. Hichens L, Rowland H, Williams A, Hollinghurst E, Ewings P, Clark S *et al*. Cost-effectiveness and patient satisfaction: Hawley and vacuum-formed retainers. Eur J Orthod. 2007; 29:372-8.
11. Little RM. Stability and relapse of mandibular anterior alignment: University of Washington studies. Semin Orthod. 1999; 5:191-204.
12. Chadwick SM, Banks P, Wright JL. Th e use of myofunctional appliances in the UK: A survey of British orthodontists. Dent Update. 1998; 25:302-8.
13. Petrovic AG, Stutzmann JJ, Gasson N. Th e fi nal length of the mandible: Is it genetically determined? In: Carlson DS, editors. Craniofacial Biology. Monograph No. 10. Ann Arbor: Center for Human Growth and Development, University of Michigan, 1981, 105-26.
14. Sharma NS. Management of growing skeletal class II patient: A case report. Int J Clin Paediatr Dent. 2013; 6:48-54.
15. Clark WJ. Th e twin block traction technique. Eur J Orthod. 1982; 4:129-38.

16. Al-Anezi SA. Class II malocclusion treatment using combined Twin Block and fi xed orthodontic appliances - A case report. Saudi Dent J. 2011; 23:43-51.
17. Trenouth MJ. A comparison of twin block, Andresen and removable appliances in the treatment of Class II Division 1 malocclusion. Funct Orthod. 1992; 9:26-31.
18. Trenouth MJ. Cephalometric evaluation of the Twin-block appliance in the treatment of Class II Division 1 malocclusion with matched normative growth data. Am J Orthod Dentofacial Orthop. 2000; 117:54-9?