



ISSN Print: 2394-7489  
ISSN Online: 2394-7497  
IJADS 2020; 6(3): 163-168  
© 2020 IJADS  
[www.oraljournal.com](http://www.oraljournal.com)  
Received: 10-05-2020  
Accepted: 12-06-2020

**Ahmad Al-Abdullah**  
Master Student in Endodontic  
and Operative Department,  
Faculty of Dentistry, Hama  
University, Hama, Syria

**Atef Abdullah**  
Assistant Professor, PhD in  
Endodontic and Operative  
Dentistry, Hama University,  
Hama, Syria

**Khetam Al-Marrawi**  
Assistant Professor, PhD in  
Endodontic and Operative  
Dentistry, Hama University,  
Hama, Syria

**Corresponding Author:**  
**Ahmad Al-Abdullah**  
Master Student in Endodontic  
and Operative Department,  
Faculty of Dentistry, Hama  
University, Hama, Syria

## Comparative study to investigate the effect of cryotherapy on post-operative pain using two different preparation techniques (*In vivo* study)

**Ahmad Al-Abdullah, Atef Abdullah and Khetam Al-Marrawi**

### Abstract

To evaluate the role of cryotherapy in post-operative pain after using two different preparation techniques in vital single root with single canal teeth.

**Materials and Methods:** 60 symptomatic single-rooted teeth were treated endodontically with two different preparation techniques. Teeth were randomly assigned to four groups (n=15):

Group 1: ProTaper Universal preparation without cold saline, Group 2: Reciproc Blue preparation without cold saline, Group 3: ProTaper Universal preparation with cold saline 20mm for 5-minute, Group 4: Reciproc Blue preparation with cold saline 20mm for 5-minute. All teeth were restored with GIC temporally, Pain levels were assessed by Visual Analogue Scale (VAS) of pain / discomfort questionnaire after 6, 12, 24, and 48 hours and 7 days of canal obturation.

**Results:** The results showed that there was a significant difference ( $P<0.05$ ), in all study periods except after 1 week between Groups 1 and 3.

### Conclusion

1. Post- endodontic pain represented in the highest values after 12 hours of treatment, and reduced to almost finished after 1 week.
2. The intracanal cryotherapy eliminated post-endodontic pain clinically.

**Keywords:** Post-operative pain, cryotherapy, irreversible pulpitis, preparation techniques

### Introduction

Post-endodontic pain is defined as the sensation of discomfort after endodontic treatment and is reported by 25%–40% [1], and ranging from 1.5% [2]-more than 50% [3] of patients regardless of pulp and periradicular status [1]. The difference between studies may be partly explained by the fact that most of the authors assessed and defined post-endodontic pain according to different criteria, using different endodontic materials and techniques [4].

Post-endodontic pain is common, even when the endodontist has followed acceptable standards of treatment. According to previously published data, pulp therapy and Root Canal Treatment (RCT) induce more frequent and more severe postoperative pain than do other dental operative procedures [5, 6].

The common factors influencing the occurrence of pain after root canal treatment include insufficient instrumentation, irrigant extrusion, intracanal interappointment dressing extrusion, hyperocclusion, missed canals, presence of preoperative pain, presence of periapical pathosis, apical debris extrusion, and apical patency during root canal preparation [7]. Post-endodontic pain most often occurs during the first 24–48 hours after obturation, and generally recedes in a few hours [8, 9], although it occasionally persists for several days [10, 11, 12].

Major advances in rotary instrumentation and metallurgy have led to the introduction of numerous systems with innovative designs in recent years. Nonetheless, all the preparation techniques and instruments available to date are still associated with some degree of extrusion of debris which may cause post-endodontic pain [13].

ProTaper Universal (Dentsply/ Maillefer, Ballaigues, Switzerland) is one of the conventional clockwise rotation multi-file rotary systems used since 2001, which prepares the root canals with six files: three shaping and three finishing files. A unique design element is the convex triangular cross-section and the varying tapers along the instruments [14].

Bürklein and Schafer demonstrated that full-sequence rotary instrumentation was associated with less debris extrusion when compared with the use of reciprocating single-file systems [15].

Reciproc blue (VDW GmbH, Munich, Germany), a thermally treated nickel—titanium instrument, is an improved version of the original Reciproc which works in (150:30) contraclockwise reciprocation motion [16]. It has an increased resistance to cyclic fatigue and a greater flexibility [17].

Irrigation has a key role in successful endodontic treatment. Although hypochlorite is the most important used irrigating solution, no single irrigant can accomplish all the tasks required by optimum irrigation solution [18].

Bashetty and Hegde in 2010 reported that the type of irrigant used was not associated with the post-endodontic pain after one or seven days [19].

Cryotherapy is a relatively new form of treatment in which the body is briefly exposed to very cold temperatures in order to promote healing and other therapeutic results. The basic technique of cryotherapy stresses rapid cooling, slow thawing and repetition of the freezing process to maximize tissue destruction [28]. It will reduce the local blood flow by vasoconstriction and therefore the local inflammatory reaction, swelling, and heat experience, and also will slow the conduction of nerve signals potentially reducing pain transmission [20, 21].

In Dentistry, Cryotherapy has been used after intraoral surgical procedures such as periodontal surgery, extractions, and implant placement, and was found to be effective in reducing swelling and pain [22].

In endodontics, George GK *et al.* in 2011 have found in their in vitro study that the deep dry cryotherapy of NiTi endodontic files can improve its cyclic fatigue resistance [23], reducing the potential file separation.

In recent one in vitro study by Jorge Vera *et al.*, in 2015, it was found that intracanal delivery of cold saline solution (2.5 °C) with negative pressure irrigation reduced the external root surface temperature more than 10 °C, and maintained it long enough to possibly produce a potential local anti-inflammatory effect in the periradicular tissues [24].

So, the aim of this study was to Investigate the Effect of Cryotherapy on Post-Operative Pain Using Two Different Preparation Techniques

## Material and methods

**Study design:** Randomized Clinical Trial (RCT), with single blind assessment technique.

This study was carried out in the clinics of faculty of Dentistry at the Hama University, after ethical approval obtaining from Hama University ethical committee. Before starting treatment procedures, all participants were informed about the nature and objectives of the study, along with obtaining a written consent from all. Participants were also not aware of the study group that they were belonging to (single blind).

**Inclusion and Exclusion Criteria:** 20 years and older Patients referring to dental clinics at Hama dentistry collage with irreversible pulpitis or deep caries lesions, acceptable oral health, no gingival recession (or existing periodontal disease), good general health, and no chronic diseases or pregnancy or medicaments intake were good candidates for this study.

Accepted teeth for this study were with the following criteria:

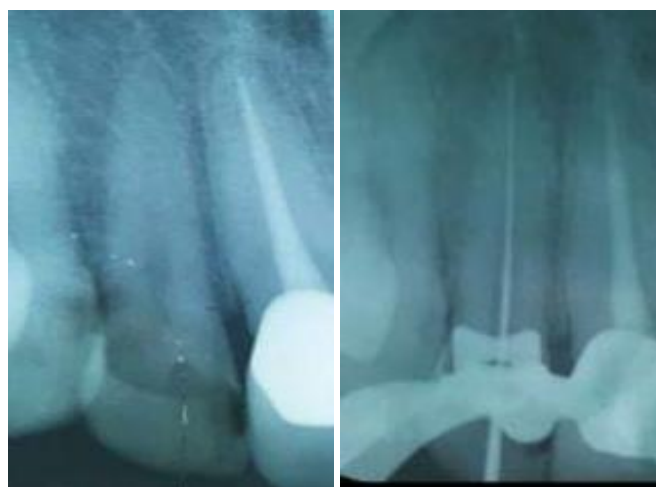1. Vital teeth with irreversible pulpitis or pulp exposure due

to deep caries excavation.

2. Single rooted with single canal teeth (radiographically and clinically assessed).
3. Ability for isolation with rubber dam.
4. Restorable teeth.
5. Excluded teeth were:
6. 1-Teeth with wide or open apex.
7. 2- Resorptions and apical periodontitis.
8. 3- Lower anterior incisors.

## Treatment procedures

Endodontic treatment was performed on all teeth in a single visit. After clinical examination and preoperative peri-apical radiograph, the teeth were anaesthetized, isolated with rubber dam, caries removed, and standard access gained to the root canal system with diamond burs under copious water cooling. Following complete access, the initial glide path was obtained by using #10 K-file (THOMAS, France). Working lengths were determined with an apex locator I-root (Meta-Biomed, Korea) and confirmed radiographically using film holder (Kerr Endo, Orange County, CA) Figure 1. Canals were prepared in groups 1,3 by using ProTaper Universal rotary files (Dentsply Maillefer, Ballaigues, Switzerland) till the file F2 (25/.08) and in groups 2,4 Canals were prepared by using Reciproc blue (VDW GmbH, Munich, Germany) R25 (25/.08) following the full sequence recommended by the manufacturer with the aid of 17 % EDTA gel (Meta-Biomed, Korea) as a lubricant. The canals were irrigated between each file with 5 ml of 5.25% NaOCl.



Diagnosis

Working length

**Fig 1:** diagnosis & working length

After root canal preparation, study sample 60 teeth were divided randomly into 4 equal groups (n=15) as follows:

Group1: ProTaper Universal preparation without cold saline,  
Group 2: Reciproc Blue preparation without cold saline,  
Group 3: ProTaper Universal preparation with cold saline 20mm for 5-minute, Group 4: Reciproc Blue preparation with cold saline 20mm for 5-minute.

Randomization: Regardless of the treated included case in the study, and without informing the patient of which group the treated tooth was belonging to (single blind), the first treated case was for the first group, the second was for the second group, and the third case was for the third group and so on.

The temperature of cold saline was preserved for the 5 minutes irrigation period by keeping the irrigation syringes, which were used one by one, in special box filled with ice after removal from refrigerator with thermocouple (Vici

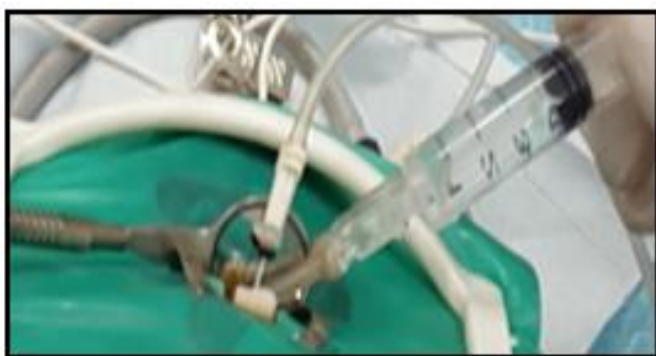CTH-608A Outdoor Thermometer, China) inserted inside to confirm the 2-4 °C temperature range. Figure 2



Saline 2 °C

**Fig 2:** Saving the irrigation syringes in special box filled with ice

In groups 3 and 4, irrigation needle inserted to the working length and another irrigation needle supplying the 20 ml saline solution during 5 minutes at the canal orifice.

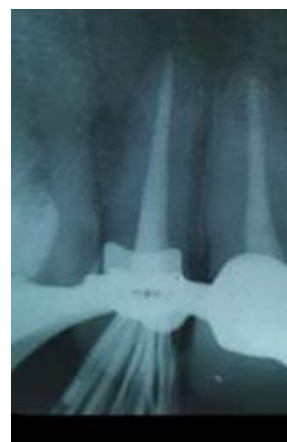

Applying cold saline clinically

**Fig 3:** Applying cold saline 2-4 °C irrigation in group 3,4

Canals were then dried with paper points and obturated in the same visit by lateral condensation technique with resin-based sealer Adseal (Meta-Biomed, Korea lot: ADS1505151) and gutta percha cones taper 4% (Meta-Biomed, Korea lot:

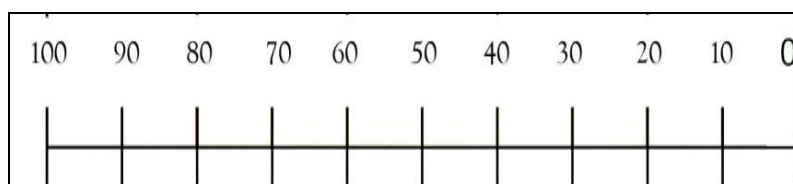
GE1102078). Figure 4, Upon completion of root canal treatment, each canal access was sealed temporary with a glass ionomer restoration (Kavitan plus SpofaDENTAL, Czech Republic, lot: 2481885-1). A periapical radiograph was then carried out to ensure the accuracy of root canal obturation, and any improper obturation was retreated and excluded from the study.



**Fig 4:** The obturation canal

Each patient received instruction on how to use a questionnaire for the numeric the questionnaire contained a 10-cm (100 millimeter) Visual Analogue Scale (VAS) [25] (Figure 5) to assess discomfort / pain after 6, 12, 24, 48 hours and 7 days of canal obturation.

The patient has to mark the area on the VAS that corresponds with the amount of felt pain as the (0) degree refers for no pain, and the (100) degree refers for unbearable pain. The distance between the beginning of the scale (0 degree) and the patient's pain mark was measured using a roller and the VAS value by millimeters was recorded. Patients were contacted on phone to remind them registering pain according to different periods. The questionnaires were completed and delivered after one week of canal obturation at the composite (Nexcomp, Meta-Biomed, Korea lot: 0120) final restoration appointment.



**Fig 5:** Visual analogue scale (VAS) of 10 cm used to assess discomfort / pain.

In case of sever or unbearable pain, patients were allowed to take anti-inflammatories like Ibuprofen 400 mg, or sedatives like Acetaminophen, or both according to pain severity and was excluded from the study.

The data was then inserted to a personal computer and analyzed using the SPSS 13.0 computer software by using Mann-Whitney U Test for comparing between the study groups. P value of 0.05 was considered statistically significant.

**Results and Statistical Study**

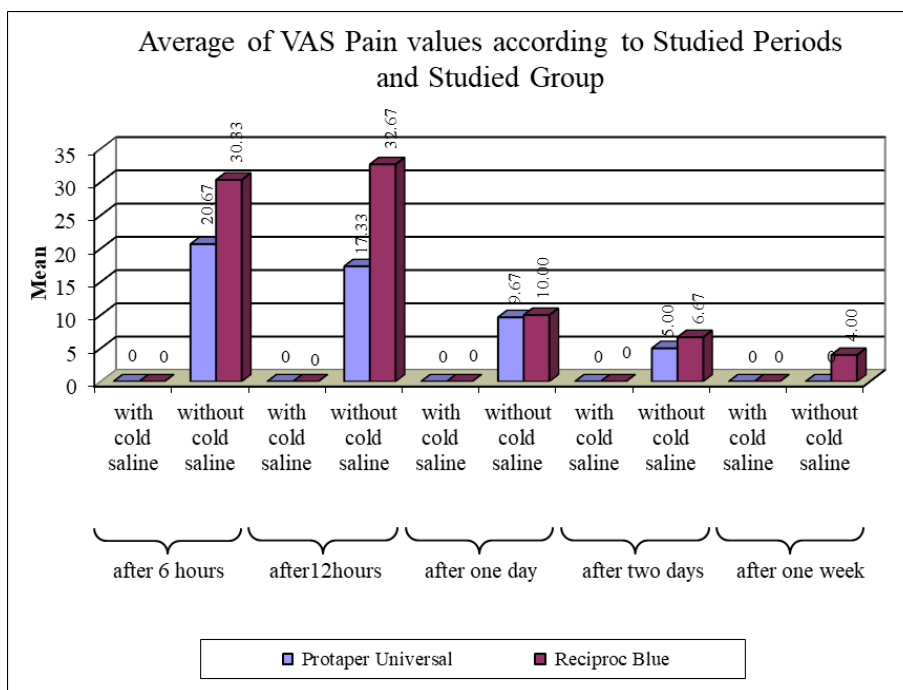
Study sample consisted of 60 single-visit root canal treatment. Study sample was divided into 4 equal distinct groups (*group1:* ProTaper Universal without cold saline *group2:*

Reciproc Blue without cold saline *group3:* ProTaper Universal with cold saline *group4:* Reciproc Blue with cold saline). Table 1.

**Table 1:** Sample Distribution according to Studied Groups

| Studied Group                          | N  | Percent |
|--|----|---------|
| ProTaper Universal without cold saline | 15 | 25.0    |
| Reciproc Blue without cold saline      | 15 | 25.0    |
| ProTaper Universal with cold saline    | 15 | 25.0    |
| Reciproc Blue with cold saline         | 15 | 25.0    |
| Total                                  | 60 | 100     |

The results of VAS pain values according to different groups and periods are illustrated in figure 6



**Fig 6:** Average of VAS Pain values according to Studied Group and the studied Period.

A Kruskal-Wallis Test was applied to know if there were significant differences in VAS Pain values between study groups according to the studied Period like it is shown below: Table 2

**Table 2:** Kruskal-Wallis Test results to know if there were significant differences in VAS Pain values between study groups according to the studied Period.

| Studied Variables = VAS Pain |         |         |           |                    |                |
|------------------------------|---------|---------|-----------|--------------------|----------------|
| Significant Diff.?           | P-Value | U value | Mean Rank | Studied Group      | Studied Period |
| YES                          | 0.000   | 30.0    | -20.67    | ProTaper Universal | After 6 hours  |
| YES                          | 0.000   | 15.0    | -30.33    | Reciproc Blue      |                |
| YES                          | 0.000   | 30.0    | -17.33    | ProTaper Universal | After 12 hours |
| YES                          | 0.000   | 15.0    | -32.67    | Reciproc Blue      |                |
| YES                          | 0.000   | 37.5    | -9.67     | ProTaper Universal | After one day  |
| YES                          | 0.000   | 22.5    | -10.00    | Reciproc Blue      |                |
| YES                          | 0.016   | 75.0    | -5.00     | ProTaper Universal | After two days |
| YES                          | 0.001   | 52.5    | -6.67     | Reciproc Blue      |                |
| No                           | 1.000   | 112.5   | 0         | ProTaper Universal | After one week |
| YES                          | 0.016   | 75.0    | -4.00     | Reciproc Blue      |                |

P-Values were greater than 0.05 after 1 week, so at the confidence level of 95% there were no significant differences in VAS Pain after 1 week between studied groups in the studied sample.

All other P-Values were lower than 0.05, so at the confidence level of 95% there were significant differences in VAS Pain between at least two of the three studied groups according to studied periods.

**Discussion**

The most important objective of root canal therapy is total tissue debridement and to minimize the number of microorganisms in root canal system followed by 3d obturation of the prepared space [26].

Postoperative pain is a frequent complication associated with root canal treatment, especially during apical instrumentation of tooth with preexisting periradicular inflammation objectives [27].

Prevalence of post-operative pain after endodontic treatment has been reported to range from 1.5% [2] to more than 50%. [3] So, the aim of this study was to Investigate the Effect of Cryotherapy on Post-Operative Pain Using Two Different Preparation Techniques

It was noticed from study results that in groups without cold saline, post endodontic pain presented with highest values after 12 hours of treatment which started to reduce in the after-monitoring periods until it was almost diminished after 1 week. This could be attributed to the possible irritation of the periapical area due to endodontic treatment that caused the local inflammatory response which leads to this post endodontic pain that diminished after recovery of the periapical area. These results were in correspondence with Siqueira JF *et al.* in 2004 [28].

On the contrast and remarkably, there were no post endodontic pain values in all monitoring periods for groups with cold saline. The results showed that there was a significant difference (P<0.05), in all study periods except after 1 week between Groups with Cold Saline and Groups without Cold Saline in ProTaper Universal samples. This result could be explained that the cold saline application reduced the temperature of the root, as it was emphasized in the in vitro study by Jorge Vera *et al.*, in 2015 [24], to unknown duration, and this root temperature reduction possibly extended to the peri apical area the action that could have a local anti-inflammatory effect by reducing edema [29]. McGown showed that a 5-minute ice massage was enough to

induce changes in the inflamed tissue of the quadriceps muscles<sup>[30]</sup>.

Hochberg showed that continuous cold application resulted in a significant reduction of pain when compared with intermittent application<sup>[31]</sup>.

These results similar to Keskin study which revealed that irrigation of root canals with a cold sterile saline solution held at 2.5 °C for 5 min reduced postoperative pain when compared with the pain levels of patients in a control group<sup>[32]</sup>.

### Conclusions

Within the limitations of this study limitation, it was concluded that:

1. Post- endodontic pain represented in the highest values after 12 hours of treatment, and reduced to almost finished after 1 week.
2. The intracanal cryotherapy eliminated post-endodontic pain clinically.

### References

1. Ince B, Ercan E, Dalli M, Dulgergil CT, Zorba YO, Colak H. Incidence of postoperative pain after single-and multi-visit endodontic treatment in teeth with vital and non-vital pulp. *European journal of dentistry*. 2009; 3(4):273.
2. Imura N, Zuolo ML. Factors associated with endodontic flare-ups: a prospective study. *International Endodontic Journal*. 1995; 28(5):261-5.
3. Levin L, Amit A, Ashkenazi M. Post-operative pain and use of analgesic agents following various dental procedures. *American journal of dentistry*. 2006; 19(4):245-7.
4. Gotler M, Bar-Gil B, Ashkenazi M. Postoperative pain after root canal treatment: a prospective cohort study. *International journal of dentistry*, 2012, 2012.
5. Levin L, Amit A, Ashkenazi M. Post-operative pain and use of analgesic agents following various dental procedures. *American journal of dentistry*. 2006; 19(4):245-7.
6. Ashkenazi M, Blumer S, Eli I. Post-operative pain and use of analgesic agents in children following intrasulcular anaesthesia and various operative procedures. *British dental journal*. 2007; 202(5):E13
7. Alves Vd O. Endodontic flare-ups: a prospective study. *Oral Surg Oral Med Oral Pathol Oral Radiol Endod*. 2010; 110:e68-72.
8. Harrison JW, Baumgartner JC, Svec TA. Incidence of pain associated with clinical factors during and after root canal therapy. Part 2. Postobturation pain. *Journal of Endodontics*. 1983; 9:434-38.
9. Al-Negrish AR, Hababbeh R. Flare up rate related to root canal treatment of asymptomatic pulpally necrotic central incisor teeth in patients attending a military hospital. *Journal of Dentistry*. 2006; 34:635-40.
10. Pak JG, White SN. Pain prevalence and severity before, during, and after root canal treatment: A systematic review. *Journal of Endodontics*. 2011; 37:429-38.
11. Seltzer S, Bender IB, Ehrenreich J. Incidence and duration of pain following endodontic therapy. Relationship to treatment with sulfonamides and to other factors. *Oral Surgery Oral Medicine Oral Pathology Oral Radiology & Endodontics*. 1961; 14:74-82. .
12. Siqueira JF, Jr. Microbial causes of endodontic flare-ups. *International Endodontic Journal*. 2003; 36:453-63.
13. Kirchhoff AL, Fariniuk LF, Mello I. Apical extrusion of debris in flat-oval root canals after using different instrumentation systems. *Journal of endodontics*. 2015; 41(2):237-41.
14. Shokraneh A, Ajami M, Farhadi N, Hosseini M, Rohani B. Postoperative endodontic pain of three different instrumentation techniques in asymptomatic necrotic mandibular molars with periapical lesion: a prospective, randomized, double-blind clinical trial. *Clinical oral investigations*. 2017; 21(1):413-8.
15. Bürklein S, Schäfer E. Apically extruded debris with reciprocating single-file and full-sequence rotary instrumentation systems. *Journal of endodontics*. 2012; 38(6):850-2.
16. <https://www.vdwdental.com/fileadmin/Dokumente/Sortiment/Aufbereitung/Reziproke-Aufbereitung/RECIPROC-blue/VDW-Dental-Reciprocblue-brochure-EN.pdf>.
17. De-Deus G, Silva EJ, Vieira VT, Belladonna FG, Elias CN, Plotino G *et al*. Blue thermomechanical treatment optimizes fatigue resistance and flexibility of the Reciproc files. *Journal of endodontics*. 2017; 43(3):462-6.
18. Haapasalo M, Shen Y, Qian W, Gao Y. Irrigation in endodontics. *Dental Clinics of North America*. 2010; 54(2):291-312
19. Bashetty K, Hegde J. Comparison of 2 % chlorhexidine and 5.25 % sodium hypochlorite irrigating solutions on postoperative pain: a randomized clinical trial. *Indian J Dent Res*. 2010; 21(4):523-7.
20. Algaflly AA, George KP. The effect of cryotherapy on nerve conduction velocity, pain threshold and pain tolerance. *Br J Sports Med*. 2007; 41:365-369; discussion 369.
21. Kullenberg B, Ylipaa S, Soderlund K, Resch S. Postoperative cryotherapy after total knee arthroplasty: a prospective study of 86 patients. *J Arthroplasty*. 2006; 21:1175–1179. doi: 10.1016/j.arth.2006.02.159.
22. Laureano Filho JR, de Oliveira e Silva ED, Batista CI, Gouveia FM. The influence of cryotherapy on reduction of swelling, pain and trismus after third-molar extraction: a preliminary study. *J Am Dent Assoc* 2005; 136:774-8.
23. George GK, Sanjeev K, Sekar M. An in vitro evaluation of the effect of deep dry cryotreatment on the cutting efficiency of three rotary nickel titanium instruments. *Journal of Conservative Dentistry*. 2011; 14(2):169.
24. Vera J, Ochoa-Rivera J, Vazquez-Carcano M, Romero M, Arias A, Sleiman P. Effect of Intracanal Cryotherapy on Reducing Root Surface Temperature. *Journal of endodontics*. 2015; 41(11):1884-7.
25. Huskisson EC. Measurement of pain. *Lancet*. 1974; 2:1127-31.
26. Grossman LI. *Root canal therapy*. Lea & Febiger; 1955.
27. Sathorn C, Parashos P, Messer H. The prevalence of postoperative pain and flare-up in single-and multiple-visit endodontic treatment: a systematic review. *International endodontic journal*. 2008; 41(2):91-9.
28. Siqueira JF, Barnett F. Interappointment pain: mechanisms, diagnosis, and treatment. *Endodontic Topics*. 2004; 7(1):93-109.
29. Saini D. Cryotherapy–An Inevitable part of Sports Medicine and it’s benefits for Sports Injury. *IJAR*. 2015; 1(4):324-7.
30. McGown HL. Effects of cold application on maximal isometric contraction. *Phys Ther*. 1967; 47:185-92.

31. Hochberg J. A randomized prospective study to assess the efficacy of two cold therapy treatments following carpal tunnel release. *J Hand Ther.* 2001; 14:208-15.
32. Keskin C, OzgOzdemir, Ismail Uzun, Bugra G, Effect of intracanal cryotherapy on pain after single-visit root canal treatment, *Australian endodontic journal*, 2016, 1-4.