



ISSN Print: 2394-7489
ISSN Online: 2394-7497
IJADS 2021; 7(3): 37-39
© 2021 IJADS
www.oraljournal.com
Received: 22-05-2021
Accepted: 24-06-2021

Dr. Aanchal Tyagi
P.G Student, Department of
Periodontology and
Implantology, Subharti Dental
College and Hospital, Meerut,
Uttar Pradesh, India

Dr. Mehvish Saleem
Senior Lecturer, Department of
Periodontology and
Implantology, Subharti Dental
College and Hospital, Meerut,
Uttar Pradesh, India

Dr. Mayur Kaushik
Professor and Head, Department
of Periodontology and
Implantology, Subharti Dental
College and Hospital, Meerut,
Uttar Pradesh, India

Dr. Nazar Rana
Associate Professor, Department
of Periodontology and
Implantology, Subharti, Meerut,
Uttar Pradesh, India

Corresponding Author:
Dr. Aanchal Tyagi
P.G student, Department of
Periodontology and
Implantology, Subharti Dental
College and Hospital, Meerut,
Uttar Pradesh, India

Classical frenectomy: A case report

**Dr. Aanchal Tyagi, Dr. Mehvish Saleem, Dr. Mayur Kaushik and
Dr. Nazar Rana**

DOI: <https://doi.org/10.22271/oral.2021.v7.i3a.1278>

Abstract

The frenum is a mucous membrane fold that attaches the lip and the cheek to the alveolar mucosa, the gingiva, and the underlying periosteum. The frenum may hamper the gingival health if it is attached too closely to the gingival margin, which can be a result of interference in the plaque control or due to a muscle pull. The management of such an aberrant frenum is treated by performing a frenectomy. The present case report is on frenectomy using the conventional technique with 3 months of follow up.

Keywords: frenectomy, conventional frenectomy, frenum, mucogingival technique

Introduction

The frenum is a mucous membrane fold that attaches the lip and the cheek to the alveolar mucosa, the gingiva, and the underlying periosteum [1].

The presence of a diastema between the maxillary central incisors in adults has often been considered as an aesthetic problem. Labial thick and high attached maxillary frenum is commonly regarded as contributing etiology for maintaining midline diastema and delayed upper jaw development, so the focus on the frenum has become essential. The frena may also jeopardize the gingival health by causing a gingival recession when they are attached too closely to the gingival margin, either because of an interference with the proper placement of a toothbrush or through the opening of the gingival crevice because of a muscle pull [2].

Indication

The frenum is characterized as pathogenic and is indicated for removal when

1. An aberrant frenal attachment is present, which causes a midline diastema.
2. A flattened papilla with the frenum closely attached to the gingival margin is present, which causes a gingival recession and a hindrance in maintaining the oral hygiene.
3. An aberrant frenum with an inadequately attached gingiva and a shallow vestibule is seen.

Classification

The labial frenal attachments have been classified as mucosal, gingival, papillary and papilla penetrating, by Placek *et al* (1974) [3].

1. Mucosal – when the frenal fibres are attached up to the mucogingival junction.
2. Gingival – when the fibres are inserted within the attached gingiva.
3. Papillary – when the fibres are extending into the interdental papilla.
4. Papilla penetrating – when the frenal fibres cross the alveolar process and extend up to the palatine papilla.

Diagnosis

The abnormal frena are detected visually by applying tension over the frenum to see the movement of the papillary tip or the blanch which is produced due to ischaemia in the region. The frenum is characterized as pathogenic when it is unusually wide or when there is no apparent zone of the attached gingiva along the midline or the interdental papilla shifts when the frenum is extended.

There are various modalities used to excise the frenum, it can be performed by conventional method using blade and scalpel, using soft tissue laser or electrocautery. Below are the conventional frenectomy techniques employed:

1. Conventional (classical) frenectomy
2. Miller's technique
3. V-Y plasty
4. Z Plasty
5. Frenectomy by electrosurgery and Laser

Case Report

A 35 years old male patient reported in the Department of Periodontology and Implantology Subharti Dental College and Hospital, Meerut, U.P, with a chief complain of space in the front teeth since 5 years. On clinical examination pull test revealed a papillary penetrating type of maxillary labial frenum attachment. Medical history was not significant. After obtaining informed consent, labial frenectomy was planned using the classical technique introduced by Archer (1961) and Kruger (1964).

Armamentarium

Haemostat, scalpel blade no.15, gauze sponges, 4-0 black silk sutures, suture pliers, scissors, and a periodontal dressing (Coe-pak).

Procedure performed was classical scalpel technique

- Local infiltration given by using 2% lignocaine with 1:80000 adrenaline.
- Haemostat was inserted to deepest depth of vestibule (Fig.1.)

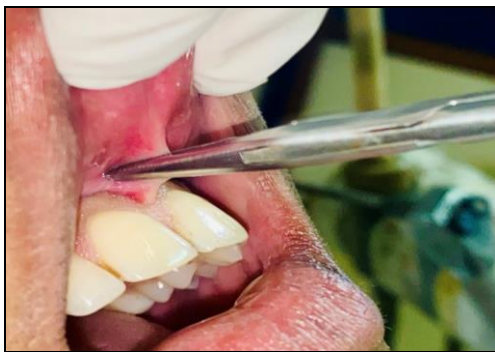

Fig 1: Frenum held with Haemostat

- With the help of No.15 Bard Parker blade, two parallel vertical incision was given.
- Triangular resected frenum was removed and underlying tissue was exposed. (Fig.2.) (Fig.3.)

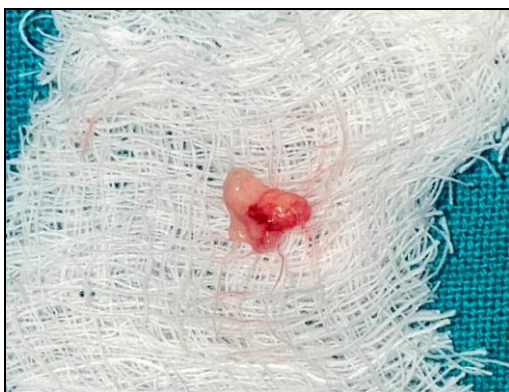


Fig 2: Resected frenum

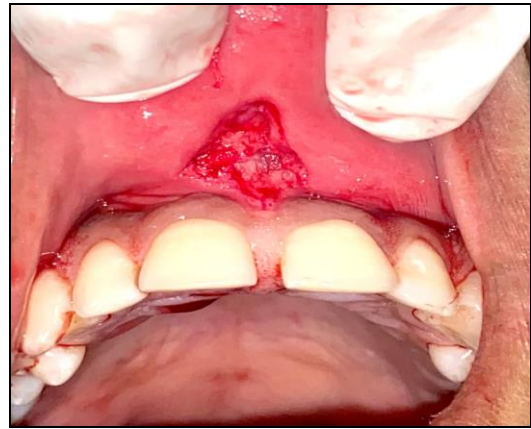

Fig 3: Excision of frenum with scalpel

- Horizontal incision were made to separate the attached fibres with gradually blending of vestibular tissue. (Fig.4.)

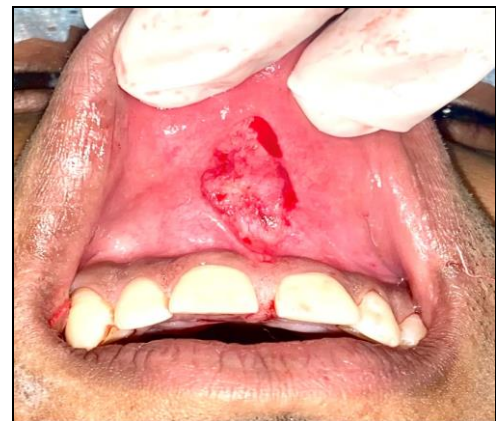

Fig 4: Separation of attached fibers

- 4-0 suture was placed (Fig.4.).

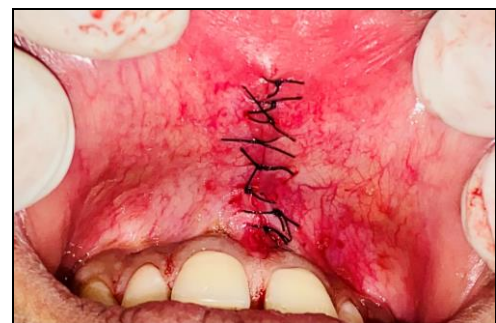

Fig 4: Placement of 4-0 suture

- Surgical area was covered with periodontal pack.

The patient was recalled after a week for suture removal. (Fig.5.) After one week satisfactory healing was observed. The patient was followed up for a period of 3 months and significant improvement was observed at the end of 3 months. (Fig.6.) Patient did not complain of any disturbance in speech and in chewing from front teeth after the removal of high frenum. The overall appearance of the patient's soft tissues, gingiva and superior lip were found to be healthy and esthetic. The patient was referred to the department of orthodontics for the further treatment of midline diastema.

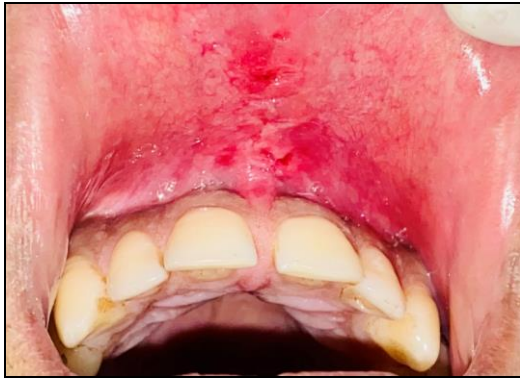

Fig 5: One week follow up after suture removal

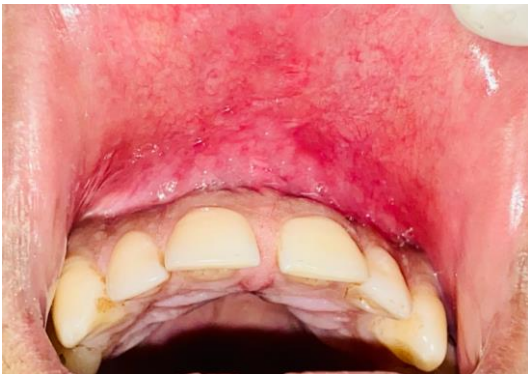

Fig 6: Three months follow up

Discussion

In the era of periodontal plastic surgery, more conservative and precise techniques are being adopted to create more functional and aesthetic results. The presence of an aberrant frenum being one of the etiological factors for the persistence of a midline diastema, the focus on the frenum has become essential. The aberrant frenum can be treated by frenectomy or by frenotomy procedures^[4].

The classical technique was introduced by Archer (1961) and Kruger (1964). This approach was advocated in the midline diastema cases with an aberrant frenum to ensure the removal of the muscle fibres which were supposedly connecting the orbicularis oris with the palatine papilla^[5].

The causes for spacing between the maxillary incisors as a result of high frenum attachment, microdontia, macrognathia, supernumerary teeth, peg laterals, missing lateral incisors, midline cysts and habits such as thumb sucking, mouth-breathing and tongue-thrusting^[6].

Generally abnormal frenal attachment may require removal either before orthodontic treatment or at the end of active treatment. The advantage of excision prior to orthodontic treatment is the ease of surgical access^[7].

An aberrant frenum can be removed by any of the modification techniques that have been proposed, however, a functional and an aesthetic outcome can be achieved by a proper technique selection, based on the type of the frenal attachment^[8].

Periodontal situation is influenced by certain forms of maxillary frenum. In case scenarios of gingival, papillary, and papillary penetrating types of maxillary frenum attachment, the periodontal resistance was substantially lower in individuals with pathological changes in the papilla compared to individuals with the same form of attachment but with stable papilla^[9].

In the present case report, we have excised the frenum by conventional scalpel technique at the visible region (frenal

attachment from interdental papilla until the mucogingival junction) to preserve the esthetic as the patient had a high smile line. Scalpel technique was followed in the deeper vestibule to prevent greater tissue damage in the interior aspect and for faster healing.

Patient was recalled after one week for suture removal. Uneventful healing was observed during the healing phase. Patient was followed up for three months. There was no relapse of the outcome.

Conclusion

Oral frenula are band like formations of congenital located on the midline, which comprised of fibrous, muscular or fibro muscular tissue, fenced by means of a mucosal membrane and this fold contains vascular structures with thin peripheral nervous ramifications and is covered by stratified layered epithelium.

In the present case report, the papilla penetrating frenum was present and successful outcome was achieved with the classical conventional technique. The technique was simple to perform and resulted in the desirable results with complete patient satisfaction.

Reference

1. Devishree, Gujjari SK, Shubhashini PV. Frenectomy: a review with the reports of surgical techniques. *J Clin Diag Res* 2012;6:1587-1592.
2. Jhaveri H, Jhaveri Hiral. *The Aberrant Frenum*. Dr. PD Miller the father of periodontal plastic surgery 2006, 29-34.
3. Dibart S, Karima M, Dibart Serge, Karima Mamdouth. *Practical Periodontal Plastic Surgery*. Germany: Blackwell Munksgaard; Labial frenectomy alone or in combination with a free gingival autograft 53.
4. Fiorotti RC, Bertolini MM, Nicola JH, Nicola EM. Early lingual frenectomy assisted by CO2 laser helps prevention and treatment of functional alterations caused by ankyloglossia. *Int J Orofacial Myology* 2004;30:64-71.
5. Jhaveri H. *The Aberrant Frenum*, Dr. PD Miller the father of periodontal plastic surgery 2006, 29-34.
6. Weber. Quoted in: *Orthodontic principles and practice*. Graber TM. 3rd ed. WB Saunders Co, 1972.
7. Koora K, Muthu MS, Prabhu R. Spontaneous closure of midline diastema following frenectomy. *J Indian Soc Pedod Prev* 2007;3:23-26.
8. Kaushik N, Srivastava N, Kaushik M, Sharma N, Khattar S. Esthetic Management of Papillary Penetrating Frenum Using Conventional Technique: A Case Report with one year follow up. *Int J Adv Res* 2016;4:1248-1255.
9. Mirko P, Miroslav S, Lubor M. Significance of the labial frenum attachment in periodontal disease in man. Part II. An attempt to determine the resistance of periodontium. *J Periodontol* 1974;45:895-897.