



ISSN Print: 2394-7489
ISSN Online: 2394-7497
IJADS 2021; 7(3): 393-395
© 2021 IJADS
www.oraljournal.com
Received: 17-05-2021
Accepted: 21-06-2021

Dr. Kaumudhi Kalla
Department of Prosthodontics
Sree Sai Dental College and
Research Institute, Srikakulam,
Andhra Pradesh, India

Dr. Tulsi Lodhi
Associate Professor,
Prosthodontist, Department of
Plastic Reconstructive and
Maxilla Facial Surgery,
Government Medical College,
Nagpur, Maharashtra, India

Dr. Chippada Satya Kinnera
M.D.S Oral and Maxillofacial
Surgery, Senior Resident Doctor
in Osmania Dental Hospital,
Hyderabad, Telangana, India

Dr. Abhishek Srivastava
Lecturer, (Department of Oral
and Maxillofacial Surgery)
Chandra Dental College &
Hospital, Lucknow, Uttar
Pradesh, India

Dr. Furkan Ahmed Khan
Senior Lecturer, Department:
Prosthodontics Crown and
Bridge, Sri Aurobindo College of
Dentistry, Indore, Madhya
Pradesh, India

Dr. Ansuman Jyoti Das
Department of Prosthodontics,
Sardar Patel Post Graduate
Institute of Dental and Medical
sciences, Lucknow, Uttar
Pradesh, India

Corresponding Author:
Dr. Kaumudhi Kalla
Department of Prosthodontics
Sree Sai Dental College and
Research Institute, Srikakulam,
Andhra Pradesh, India

Evaluation of dental implant placement site in anterior maxilla

Dr. Kaumudhi Kalla, Dr. Tulsi Lodhi, Dr. Chippada Satya Kinnera, Dr. Abhishek Srivastava, Dr. Furkan Ahmed Khan and Dr. Ansuman Jyoti Das

DOI: <https://doi.org/10.22271/oral.2021.v7.i3f.1328>

Abstract

Background: Successful implant treatment depends on precise planning. Information on the height, width, morphology, and density of alveolar bone surrounding the proposed implant site is very critical for determination of the size of the implant and angle of placement. The present study was conducted to assess anterior maxilla for dental implant placement.

Materials & Methods: 45 patients of both genders requiring dental implant in maxillary anterior teeth underwent CBCT scan of anterior maxilla was done with Planmeca CBCT machine. Parameters such as bone height, bone width, buccal undercut location and buccal undercut depth was measured.

Results: The mean bone height in central incisor region was 18.26 mm, in lateral incisor region was 18.02 mm and in canine region was 23.14 mm. The mean bone width in central incisor region was 9.30 mm, in lateral incisor was 8.45 mm and in canine region was 9.81 mm. The mean buccal undercut location at central incisor was 5.72 mm, at lateral incisor was 3.42 mm and at canine was 5.14 mm. Buccal undercut depth at central incisor was 0.72 mm, at lateral incisor was 0.80 mm and at canine region was 0.71 mm. The difference was significant ($P < 0.05$).

Conclusion: Canine region showed maximum bone height and bone width. Maximum buccal undercut was seen in central incisor region.

Keywords: maxilla, dental implant, undercut

Introduction

The anterior maxilla requires careful consideration during treatment planning dental implant placements due to unique conditions that are present^[1, 2]. When people smile the crowns of their anterior teeth and some soft tissue is usually visible, it is, therefore, essential that implant restorations in the anterior maxilla be harmonious with adjacent natural teeth so as not to distract from a person's smile^[3]. Because the goal is to provide dental implants and restorations that are aesthetically pleasing and in harmony with a patient's natural dentition and adjacent restorations, careful treatment planning and risk assessment is needed in order to achieve successful outcomes^[4]. Oral rehabilitation with implant-supported prostheses has been very successful in restoration of single or multiple missing teeth. Successful implant treatment depends on precise planning. Information on the height, width, morphology, and density of alveolar bone surrounding the proposed implant site is very critical for determination of the size of the implant and angle of placement^[5]. CBCT provides high-resolution and accurate multiple planar reformatted images at a relatively low radiation dosage and affordable price^[7]. Dimensional measurement by CBCT can achieve sub-millimeter accuracy which is comparable to the level of multi-slice computerized tomography^[6]. The present study was conducted to assess dental implant placement in anterior maxilla.

Materials & Methods

The present study consisted of 45 patients of both genders requiring dental implant in maxillary anterior teeth. All were informed regarding the study and their written consent was obtained.

After thorough oral examination, CBCT scan of anterior maxilla was done with Planmics CBCT machine following all standardized parameters and with patient protection. Parameters such as bone height, bone width, buccal undercut location and buccal undercut depth was measured. Results thus obtained were subjected to statistical analysis. P value < 0.05 was considered significant.

Results

Table 1: Patient distribution based on gender

Total- 45		
Gender	Males	Females
Number	25	20

Table I shows that out of 45 patients, males were 25 and females were 20.

Table 2: Measurement of bone height

Teeth region	Mean height (mm)	P value
Central incisor region	18.26	0.05
Lateral incisor region	18.02	
Canine region	23.14	

Table II shows that mean bone height in central incisor region was 18.26 mm, in lateral incisor region was 18.02 mm and in canine region was 23.14 mm. The difference was significant (P < 0.05).

Table 3: Measurement of bone width

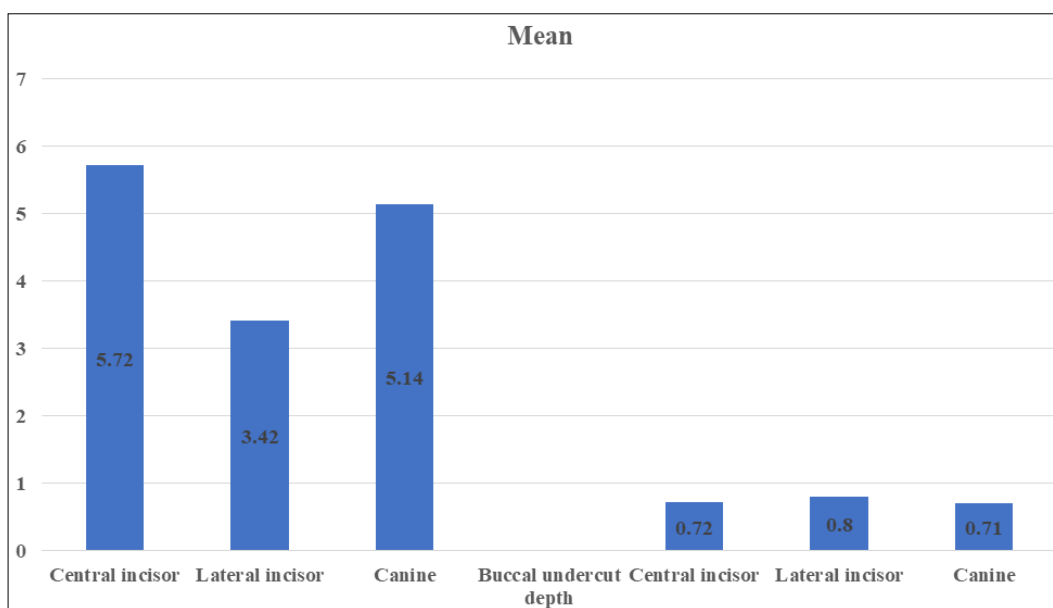
Teeth region	Mean width (mm)	P value
Central incisor region	9.30	0.04
Lateral incisor region	8.45	
Canine region	9.81	

Table III shows that mean bone width in central incisor region was 9.30 mm, in lateral incisor was 8.45 mm and in canine region was 9.81 mm. The difference was significant (P < 0.05).

Table 4: Buccal undercut location and depth

Buccal undercut location	Mean	P value
Central incisor	5.72	0.01
Lateral incisor	3.42	
Canine	5.14	
Buccal undercut depth		
Central incisor	0.72	0.04
Lateral incisor	0.80	
Canine	0.71	

Table IV, graph I shows that mean buccal undercut location at central incisor was 5.72 mm, at lateral incisor was 3.42 mm and at canine was 5.14 mm. Buccal undercut depth at central incisor was 0.72 mm, at lateral incisor was 0.80 mm and at canine region was 0.71 mm. The difference was significant (P < 0.05).



Graph 1: Buccal undercut location and depth

Discussion

Implant therapy for replacement of missing teeth in different areas in the oral cavity has become a standard of care [7]. Knowing the anatomy of the alveolar ridges and thickness of bone around natural teeth is of utmost importance in treatment planning for proper positioning of future implants, especially in the esthetic zone. Therapy success is mostly defined by the harmony of the definitive restoration with the surrounding soft and hard tissues. It has been established that resorption of the alveolar bone after tooth extraction is inevitable, regardless of the timing of implant placement, whether delayed or immediate [8].

The alveolar process after tooth extraction normally undergoes resorption resulting in decreased alveolar height

and width. The alveolar dimension prior to tooth extraction is considered one of the prognostic factors in determining the available alveolar volume for implant placement following extraction. It has been a general consensus that a precise preoperative evaluation of alveolar dimension at the future implant site is very important to develop an appropriate placement strategy and to preserve adjacent anatomical structures, especially for cases in need of immediate implant placement [9]. The present study was conducted to assess dental implant placement in anterior maxilla.

In present study, out of 45 patients, males were 25 and females were 20. Razavi *et al.* [10] evaluated 17 edentulous cadavers for bone quantity and quality of the alveolar process of the maxilla for the purpose of dental implant placement.

The maxillary arch was divided into four anatomically defined regions for measurements of bone quantity. Bone quality was assessed histologically and described by trabecular bone patterns and tissue composition. Average bone height with a minimum thickness of 4 mm was as follows: region 1, 12.1 +/- 4.9 mm; region 2, 14.1 +/- 7.2 mm; region 3, 6.1 +/- 2.8 mm; and region 4, 8.5 +/- 2.2 mm. Histological evaluation showed increased trabeculation and thicker cortex in the maxillary anterior area, regions 1 and 2. Region 3, the floor of the maxillary sinus area, had the least amount of bone; however, the quality of bone was superior to that of region 4, the maxillary tuberosity area. Trabecular distance or marrow spaces ranged from 40 microns to 2 mm with larger spaces associated with the posterior maxilla.

We found that mean bone height in central incisor region was 18.26 mm, in lateral incisor region was 18.02 mm and in canine region was 23.14 mm. The mean bone width in central incisor region was 9.30 mm, in lateral incisor was 8.45 mm and in canine region was 9.81 mm. Tarwneh *et al.* [11] evaluated labial and palatal bone thickness at the maxillary anterior teeth as well as distance from cemento-enamel junction (CEJ) to bone crest using cone beam computed tomography (CBCT). The mean value of bone thickness at coronal, middle, and apical thirds of the labial side for central incisor roots were respectively: 0.73, 0.69, 0.60 (mm), for lateral incisors: 0.70, 0.61, 0.49 (mm), and for canines: 0.74, 0.53, 0.40 (mm). The thickness of palatal bone was significantly larger. The mean distance between CEJ and mid-labial bone crest for all sites was 2.16 mm.

We found that mean buccal undercut location at central incisor was 5.72 mm, at lateral incisor was 3.42 mm and at canine was 5.14 mm. Buccal undercut depth at central incisor was 0.72 mm, at lateral incisor was 0.80 mm and at canine region was 0.71 mm. Gakonyo *et al.* [12] included a total of 184 cone beam computed tomography (CBCT) scans. Buccal bone thickness of all maxillary anterior teeth was assessed, resulting in a total of 1,104 teeth. The Mean buccal bone thickness of the teeth studied was 0.55 ± 0.38 mm at M1 and 0.60 ± 0.30 mm at M2. Missing buccal bone wall was observed in 31.61% (349 teeth) of all teeth at M1 and in 21.38% (236 teeth) of all teeth at M2. The majority of the teeth had a thin buccal bone wall (< 1 mm) at M1 (56.34%) and at M2 (68.48%), whereas a thick buccal bone (≥ 1 mm) was only observed in 12.05% of teeth at M1 and in 10.14% of teeth at M2.

Conclusion

Authors found that canine region showed maximum bone height and bone width. Maximum buccal undercut was seen in central incisor region.

References

1. Small PN, Tarnow DP, Cho SC. Gingival recession around wide-diameter versus standard-diameter implants: a 3- to 5-year longitudinal prospective study. *Pract Proced Aesthet Dent* 2001;13:143-146.
2. Bengazi F, Wennstrom JL, Lekholm U. Recession of the soft tissue margin at oral implants. A 2-year longitudinal prospective study. *Clin Oral Implants Res* 1996;7:303-310.
3. Cardaropoli G, Lekholm U, Wennstrom JL. Tissue alterations at implant-supported single-tooth replacements: a 1-year prospective clinical study. *Clin Oral Implants Res* 2006;17:165-171.
4. Morimoto T, Tsukiyama Y, Morimoto K *et al.* Facial

bone alterations on maxillary anterior single implants for immediate placement and provisionalization following tooth extraction: a superimposed cone beam computed tomography study. *Clin Oral Implants Res* 2015;26:1383-1389.

5. Carrafiello G, Dizonno M, Colli V *et al.* Comparative study of jaws with multislice computed tomography and cone-beam computed tomography. *Radiol Med* 2010;115:600-611.
6. Kobayashi K, Shimoda S, Nakagawa Y *et al.* Accuracy in measurement of distance using limited cone-beam computerized tomography. *Int J Oral Maxillofac Implants* 2004;19:228-231.
7. Atwood DA. Some clinical factors related to rate of resorption of residual ridges. *J Prosthet Dent* 1962-2001;86:119-125.
8. Botticelli D, Berglundh T, Lindhe J. Hard-tissue alterations following immediate implant placement in extraction sites. *J Clin Periodontol* 2004;31:820-828.
9. Schropp L, Wenzel A, Kostopoulos L *et al.* Bone healing and soft tissue contour changes following single-tooth extraction: a clinical and radiographic 12-month prospective study. *Int J Periodontics Restorative Dent* 2003;23:313-323.
10. Razavi R, Zena RB, Khan Z, Gould AR. Anatomic site evaluation of edentulous maxillae for dental implant placement. *Journal of Prosthodontics* 1995;4(2):90-4.
11. AlTarawneh S, AlHadidi A, Hamdan AA, Shaqman M, Habib E. Assessment of Bone dimensions in the anterior maxilla: A cone beam computed tomography study. *Journal of Prosthodontics* 2018;27(4):321-8.
12. Joseph Gakonyo BD, Implantology P, Mohamedali AJ, Mungure EK. Cone beam computed tomography assessment of the buccal bone thickness in anterior maxillary teeth: relevance to immediate implant placement. *The International journal of oral & maxillofacial implants* 2018, 33(4).