



ISSN Print: 2394-7489
ISSN Online: 2394-7497
IJADS 2021; 7(3): 470-472
© 2021 IJADS
www.oraljournal.com
Received: 19-05-2021
Accepted: 21-06-2021

Dr. Ngurang Anam
Department of Oral Medicine
and Radiology, KD Dental
College and Hospital Mathura,
Uttar Pradesh, India

Dr. Gopa Kumar R Nair
Hod & Professor, Department of
Oral Medicine and Radiology,
KD Dental College and Hospital
Mathura, Uttar Pradesh, India

Dr. Ajan Peni
Department of Prosthodontics
and Crown & Bridge,
Teerthanker Mahaveer Dental
College and Research Centre
Moradabad, Uttar Pradesh,
India

Corresponding Author:
Dr. Ngurang Anam
Department of Oral Medicine
and Radiology, KD Dental
College and Hospital Mathura,
Uttar Pradesh, India

Gingival fibromatosis: A case report

Dr. Ngurang Anam, Dr. Gopa Kumar R Nair and Dr. Ajan Peni

DOI: <https://doi.org/10.22271/oral.2021.v7.i3g.1338>

Abstract

Gingival fibromatosis (GF) is a rare and diverse group of illnesses characterised by slow-growing, localised or diffuse gingival and interdental papilla enlargements. Extra tissue may cover the crowns of the teeth due to the development of pseudo pockets and plaque collecting, causing functional, cosmetic, and periodontal issues including as bone loss and bleeding. It affects both men and women equally. Hereditary, drug-induced, and idiopathic factors have all been associated to gingival overgrowth. Gingival fibromatosis is a hereditary condition that can occur on its own or as part of a bigger genetic disorder. Gingival fibromatosis is characterised by an excessive build-up of extracellular matrix proteins, the most visible of which is collagen type I. A mutation in the son-of-Sevenless-1 gene has been proposed as one possible etiological cause of solitary (non-syndromic) hereditary gingival fibromatosis, given the disorder's variability. Other genes, on the other hand, are likely to be involved. The patient's medical history and clinical symptoms, as well as a histological study of the affected gingiva, are used to make the diagnosis. Early finding is crucial, especially when it comes to excluding oral cancer. The differential diagnosis includes all oral illnesses with substantial gingival overgrowth. Treatments vary based on the type of overgrowth and the degree of disease progression; for example, scaling the teeth is sufficient in moderate cases, but surgical intervention is required in severe cases. The prognosis is unknown, and recurrence is possible.

Keywords: gingival fibromatosis, aetiology, pathogenesis, molecular mechanism, management

Introduction

GF is a rare disorder in which the gingiva grows in a pathological, diffuse, or localised manner. Functional, periodontal, cosmetic, and psychological issues may arise in severe cases. The disorder, which can occur as a non-syndromic hereditary gingival fibromatosis (HGF) or as part of a syndrome, is thought to be caused by hereditary causes. It can also arise as a side effect of systemic drugs, such as antiepileptic, immunosuppressant, or calcium channel blockers, in people who are predisposed. The cause of the expansion in some situations is uncertain. Excessive extracellular matrix (ECM) component accumulation appears to play a role in the pathologic presentation of GF. The chromosomes 2p21-p222 and 5q13-q22 have been genetically related to autosomal-dominant types of gingival fibromatosis, which are frequently nonsyndromic. A mutation in the son of sevenless-1 (SOS-1) gene has been proposed as a potential cause of isolated (nonsyndromic) gingival fibromatosis in recent years, but no definitive link has been demonstrated. Idiopathic gingival fibromatosis is a benign expansion of the marginal gingiva, connected gingiva, and interdental papilla that develops over time. The fibromatosis could potentially cover the exposed tooth surfaces, impairing the stomatognathic system's function. The gingival tissues are typically pink, non-hemorrhagic, and firm, fibrotic in texture. The bulbous expanded connective tissue is relatively avascular, with densely organized collagen-fiber bundles, many fibroblasts, and mild chronic inflammatory cells, according to histopathology. The epithelium overlaying it is thicker and acanthotic, with elongated rete ridges. Hypertrichosis, corneal dystrophy, nail abnormalities, deafness, and craniofacial malformations are common in the autosomal dominant variant. Children with the autosomal dominant variant of the disease may experience mental impairment and epilepsy. We report a nonsyndromic case of idiopathic gingival fibromatosis and how it was treated.

Case Report

A-10-year-old boy reported to the department of oral medicine and radiology of KD Dental College, UP, India with a chief complaint of gingival overgrowth in left upper and lower back region of mouth since 1 year. (Figure 1). Swelling was not associated with pain. He reported to the department as he was having functional and masticatory difficulty. Extra oral examination showed facial disfigurement with protruding lips. (Figure 2). Intra oral view shows severe gingival enlargement on the buccal and lingual/palatal aspect of 2nd and 3rd quadrant. Which was firm, dense, fibrous, and painless with anteriorly extended. Bleeding on probing was absent and gingival enlargement enclosed the major surface of the teeth. (Figure 3). Based on the above clinical findings, a provisional diagnosis of idiopathic generalized gingival fibromatosis was ruled out. Panoramic radiograph were advised and also a whole body general body examination and blood investigations were advised to eliminate any medical abnormalities. Panoramic Radiograph revealed normal bone height and impacted upper and lower canines. (Figure 4). For subsequent treatment, the patient was referred to the periodontics department. Gingivectomy was chosen as the treatment, followed by Gingivoplasty (Excisional Biopsy) using Electrocauterization. (Figure 5).

Surgery: A quadrant-wise gingivectomy was performed under local anaesthesia due to the magnitude and extent of gingival overgrowth. In two quadrants, an external bevel gingivectomy was performed. (Figure 6). Histopathological analysis of the entire masses of removed gingival tissue was performed.

Histopathological Report: Histopathology of fixed tissue specimens showed hyperplastic parakeratinized stratified squamous epithelium with elongated rete ridges. The underlying connective tissue presented fibrous hyperplasia with varying degree of cellularity. Chronic inflammatory cell infiltrate with a predominance of lymphocytes and plasma cells were also evident

Healing phase: 20 days post-treatment showed no signs of recurrence of the gingival hyperplasia. (Figure 7)

Table 1: Causes of generalised gingival fibromatosis

Hyperplastic gingivitis	Idiopathic variety
Mouth-breathing gingivitis	Gingival overgrowth due to leukemia
Drug-induced gingival overgrowth	Hereditary gingival fibromatosis
Scurvy	Wegener granulomatosis
Gingival overgrowth in pregnancy	Acanthosis nigricans

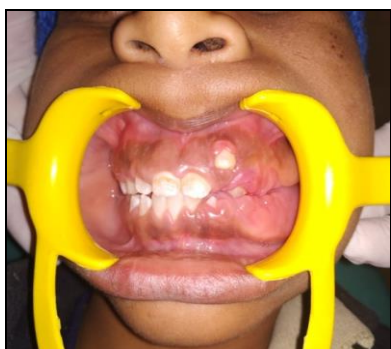


Fig 1: Gingival overgrowth in left upper and lower back region of mouth.

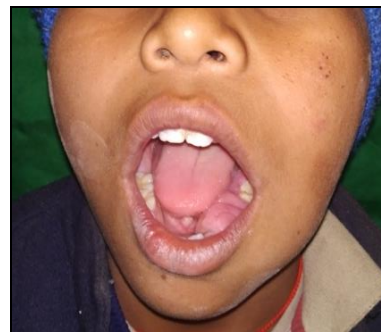

Fig 2: Extra oral examination showed facial disfigurement.

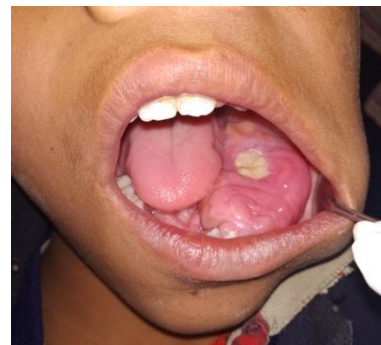

Fig 3: Gingival enlargement enclosed the major surface of the teeth.

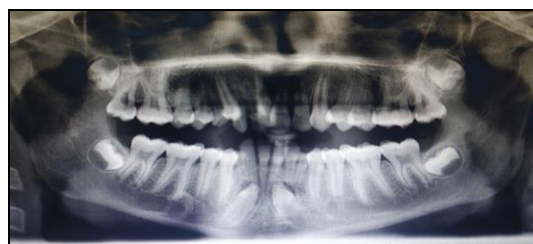


Fig 4: Panoramic Radiograph revealed normal bone height and impacted upper and lower canines.

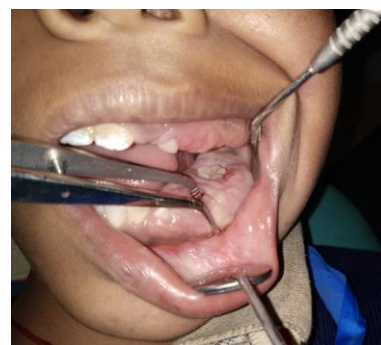

Fig 5: Gingivectomy was chosen as the treatment, followed by Gingivoplasty (Excisional Biopsy) using Electrocauterization.

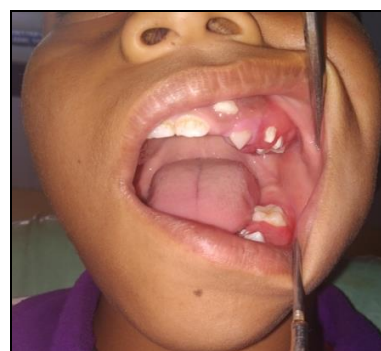


Fig 6: In two quadrants, an external bevel gingivectomy was performed.

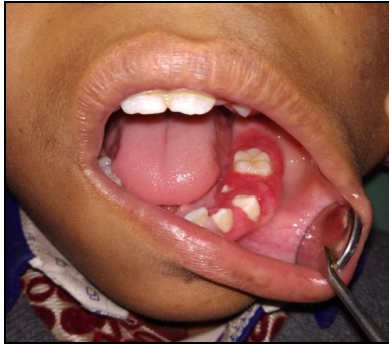

Fig 7: 20 days post-treatment showed no signs of recurrence of the gingival hyperplasia.

C. Gingival fibromatosis: clinical, molecular and therapeutic issues. *Orphanet Journal of Rare Diseases* 2016;11:9.

Discussion

Gingival overgrowth can range from a single interdental papillae expansion to segmental or uniform and significant enlargement affecting one or both jaws. A case of nonsyndromic idiopathic widespread gingival fibromatosis was presented. Gingival fibromatosis can be caused by a variety of factors. (Table 1) Generalized gingival fibromatosis has been observed in a variety of diseases with different modes of inheritance. Idiopathic gingival fibromatosis has an unknown mechanism; however, it appears to be limited to the fibroblasts that reside in the gingivae. The hyperplastic reaction occurs outside of the alveolar bone, within the connected gingiva, and has no effect on the periodontal ligament. Fibromatosis gingivae can make tooth eruption, chewing, and oral hygiene difficult. Non eruption of the primary or permanent teeth may be the patient's main problem in severe situations. Gingivectomy is the best and most recommended treatment option for idiopathic gingival fibromatosis. According to the literature, surgery has a high probability of recurrence and requires constant monitoring. There has been no recurrence in the current case after two years of observation. The timing of operation is up for dispute. The best time to have surgery is when all of your permanent teeth have erupted. Fibrosis is a bulbous increase in connective tissue that is relatively avascular and has densely packed collagen-fibre bundles, many fibroblasts, and moderate chronic inflammatory cells histopathologically. The epithelium overlaying it is thicker and acanthotic, with elongated rete ridges. Similar histology findings were found in our case report. Small calcified particles, amyloid deposits, islands of odontogenic epithelium, and osseous metaplasia in the connective tissue are all unusual features. To reduce the effect of inflammation on fibroblasts, the patient was recommended to maintain adequate oral hygiene.

Conclusion

The patient had nonsyndromic idiopathic gingival hypertrophy in this case. The gingival hypertrophy was completely removed, greatly improving the aesthetics and masticatory abilities.

Reference

1. Jaju P Prashant, Desai Ankit, Desai S, Jaju P Sushma. Idiopathic Gingival Fibromatosis: Case Report and Its Management.
2. Dani N, Praveen Khanna, Bhatt H, Joshi P. Idiopathic gingival fibromatosis. *an Soc Periodontol.* 2015;19(6):698-700.
<https://www.ncbi.nlm.nih.gov/pmc/articles/PMC4753719/#>
3. Gawron Katarzyna, Bartyzel L, Potempa Jan, Gajewska